

Acute Hemorrhagic Edema of Infancy

RAKESH KUMAR
KUNDAN MITTAL
MANOJ RAWAL
SANJAY KUMAR*

ABSTRACT

We describe an 18-month-old girl with acute hemorrhagic edema of infancy, with palpable erythematous purpuric rash on face, upper and lower limbs and ear lobules associated with edema and leukocytoclastic vasculitis. There were no systemic complications.

Key words: *Henoch-Schonlein purpura, Leukocytoclastic vasculitis.*

Acute hemorrhagic edema of infancy (AHEI) is a benign, small vessel vasculitis of young children with characteristic skin findings. The cutaneous findings are dramatic, both in appearance and rapidity of onset; histopathology is characterized by leukocytoclastic vasculitis (LCV). Since 1913, when AHEI was first reported, only about 100 case reports have appeared in the literature (1). The condition is also described as Finkelstein's disease (2), or Seidlmayer syndrome.

CASE REPORT

This 18 month old girl presented with features of viral upper respiratory tract infection for 4-5 days followed by edema starting from feet and progressing to all four limbs. The patient also showed erythematous palpable spots, first on the lower limbs that progressed to the upper limbs, face and ears and were absent from the trunk (**Fig. 1**). The

From the Departments of Pediatrics and Pathology, Pt. BD Sharma Postgraduate Institute of Medical Sciences, Rohtak, Haryana, India.*

Correspondence to: Dr. Rakesh Kumar, Assistant Professor, Advanced Pediatric Center, PGIMER, Chandigarh, India.

E-mail: drangural@yahoo.com

Manuscript received: July 7, 2007;

Initial review completed: October 11, 2007;

Revision accepted: March 10, 2008.

patient was receiving an unidentified oral antibiotic, which was administered after the onset of rash and edema. There was no history of pain abdomen, irritability, hematuria, refusal to feed or recent vaccination. There was no history of similar illness in the family. On examination, the child was active and playful with stable vitals and mild fever; the blood pressure was normal. Skin examination showed erythematous, palpable, purpuric lesions over the legs, gluteal region, upper limbs, face and ears varying in size from 0.5 to 4 cm in diameter. There was edema of upper and lower limbs; no tenderness was elicited. Systemic examination was normal. During hospital stay, there were multiple crops of these purpuric lesions. Investigations showed normal blood counts and blood levels of urea, creatinine and electrolytes; urinalysis was normal. Blood culture was sterile and chest x-ray was normal. Skin biopsy, on day 3 of admission, showed mild hyperkeratosis with spongiosis in epidermis. Dermis showed edema and periadenexal inflammatory infiltrate. Small blood vessels showed focal neutrophilic infiltrate and concentric thickening of thin walls, with nuclear dust and fibrinoid changes; the features were compatible with the diagnosis of leukocytoclastic vasculitis (**Fig. 2**). Immunofluorescence study was not done. The patient was given symptomatic treatment and recovered within 10 days.

DISCUSSION

Krause, *et al.* (3) reported a series of 5 patients and proposed clinical criteria for the diagnosis of AHEI as: age less than two years, purpuric or ecchymotic target like lesions with edema on the face, auricles and extremities with or without mucosal involvement, lack of systemic disease and visceral involvement, spontaneous recovery within few days or weeks (3). Our case fulfills all above criteria along with consistent findings of skin biopsy.

On histopathological examination of skin, small blood vessels in the dermis show perivascular neutrophilic infiltrate with numerous scattered nuclear fragments called nuclear dust. Histopathological findings in Henoch Schonlein purpura are similar to AHEI. However, IgA deposition is seen in only 10-35% cases of AHEI.

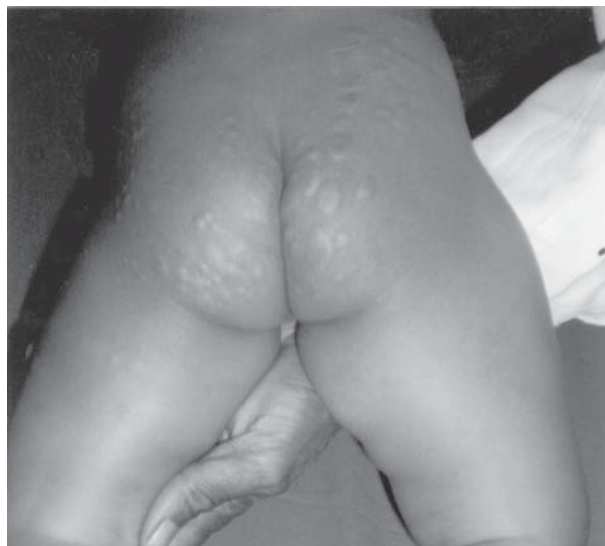

FIG.1 Typical erythematous, papular and target like skin lesions characteristic of AHEI. Note the presence of edema over both the legs.

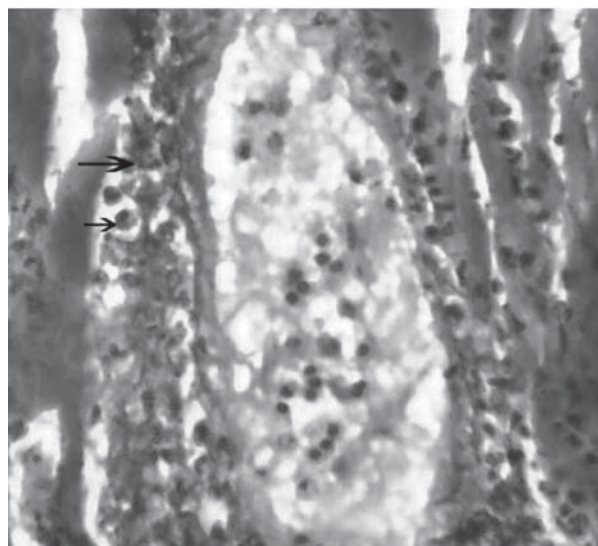


FIG.2 Photomicrograph showing thickened vessel wall with infiltration by neutrophils. Note the presence of nuclear dust. (H&E; 400X)

Immunofluorescence studies have shown deposition of fibrinogen, C3, IgA, IgG, IgM, IgE in and around small blood vessels.

AHEI is an uncommon disease. This may reflect either a low incidence or underdiagnosis. Other reason for its rarity could be that it is considered to be a variant of Henoch Schonlein purpura with only skin involvement(4). There are few case reports from India as well(5,6). The etiology of AHEI is not very clear. Poyrazoglu, *et al.*(7). reported that 6 of 8 patients had history of recent infection, drug administration or immunization.

Common differential diagnosis of AHEI include Henoch Schonlein purpura, meningococemia, erythema multiforme, urticaria with hemorrhagic elements and drug eruptions. All these entities are not difficult to differentiate from AHEI clinically. Spontaneous recovery usually occurs within 1-3 weeks, without sequelae. Recurrent episodes may occur. On follow up at one year, our patient did not have any recurrence.

Contributors: KM, RK, MR and SK were involved in management of the patient. RK and MR reviewed the literature and prepared the manuscript.

Funding: None.

Competing Interest: None stated.

REFERENCES

1. Suehiro RM, Soares BS, Eisencraft AP, Campos LM, Silva CA. Acute hemorrhagic edema of childhood. *Turk J Pediatr* 2007; 49: 189-192.
2. Morrison RR, Saulsbury FT. Acute hemorrhagic edema of infancy associated with pneumococcal bacteremia. *Pediatr Infect Dis J* 1999; 18: 832-833.
3. Krause I, Lazarov A, Rachmel A, Grunwald MM, Metzker A, Garty BZ, *et al.* Acute hemorrhagic edema of infancy, a benign variant of leukocytoclastic vasculitis. *Acta Pediatr* 1996; 85:114-117.
4. Dubin BA, Bronson DM, Eug AM. Acute hemorrhagic edema of childhood: an unusual variant of leukocytoclastic vasculitis. *J Am Acad Dermatol* 1990; 23: 347-350.
5. Shah D, Goraya JS, Poddar B, Parmar VR. Acute infantile hemorrhagic edema and Henoch Schonlein purpura overlap in a child. *Pediatr Dermatol* 2002; 19: 92-93.
6. Kaur S, Thami GP. Urticarial vasculitis in infancy. *Indian J Dermatol Venereol Leprol* 2003; 69: 223-224.
7. Poyrazoglu H M, Per H, Gunduz Z, Du sunsel R, Arslan D, Narin N, *et al.* Acute hemorrhagic edema of infancy. *Pediatr Int* 2003; 45: 697-700.