

Case Reports

Transcatheter Embolisation of Pulmonary Arteriovenous Fistula

S.S. Kothari
Mukti Sharma
Sanjeev Sharma

Pulmonary arterio-venous fistula (AVF) is rare in children. Although the majority are congenital, they usually do not present before the second decade(1). Transcatheter embolisation has now replaced surgery as the treatment modality of choice and various embolisation techniques have been described(2-4). We report a case of multiple pulmonary AVF detected in an infant who was successfully embolised using indigenous coils.

Case Report

An eleven month old male child was referred with history of cyanosis since birth, tachypnea and failure to thrive. He had developed high grade fever with seizures at 8 months of age. Computed tomography of the brain had revealed bilateral infarcts. Examination revealed

central cyanosis and clubbing, cardiovascular examination was normal and there was no murmur in the chest.

The hemoglobin was 14 g/dl and TLC was 6,700/cu mm. ECG showed a heart rate of 110/min, a QRS axis of -60, with no evidence of chamber hypertrophy. Chest X-ray revealed a cardiothoracic ratio of 60%. There was a 2.5 x 2.2 cm circular shadow seen in the right lower zone and non-homogeneous nodular opacities in the right middle and lower zones (*Fig. 1*). Echocardiography revealed a structurally normal heart. Agitated saline, injected as contrast material in the left arm appeared in the left atrium after three cycles, suggestive of a pulmonary AVF. Cardiac catheterization revealed normal pulmonary arterial pressures (mean 17 mm Hg) and systemic arterial desaturation (oxygen saturation 66%). Selective pulmonary arterial angiogram delineated multiple large AVF arising from a hypertrophied branch of the right pulmonary artery. The lower lobe branch fed the largest AVF (*Fig. 2*). The left pulmonary artery was normal.

The patient was taken up for embolisation of the large AVF in the right lower lobe as surgery would entail a lobectomy and was considered high risk. The distal lower lobe branch of the right pulmonary artery was engaged with a 7F Swan-Ganz catheter and ten indigenously made coils were released in succession (*Fig. 3*). There was significant reduction of blood flow through the AVF. The right heart pressures remained normal. The systemic arterial oxygen saturation increased from 66% to 83% following the procedure and the cyanosis diminished markedly. The child is now on regular follow up.

From the Department of Cardiology and Cardiac Radiology, Cardiothoracic Centre, All India Institute of Medical Sciences, New Delhi 110 029.

Reprint requests: Dr. S.S. Kothari, Assistant Professor Department of Cardiology, Cardiothoracic Centre, All India Institute of Medical Sciences, Ansari Nagar, New Delhi 110 029.

Received for publication: May 7, 1996;

Accepted: June 14, 1996

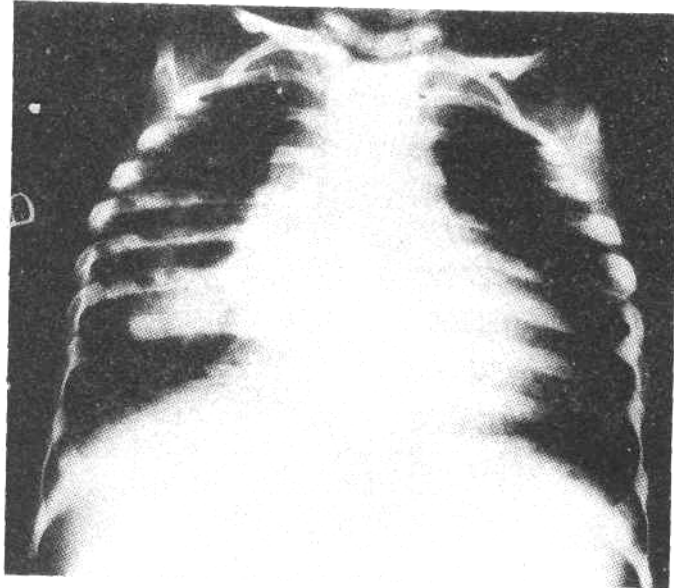


Fig. 1. X-ray chest showing a 2.5 × 2.2 cm circular shadow in the right lower zone and nonhomogeneous nodular opacities in the right middle and lower zones.

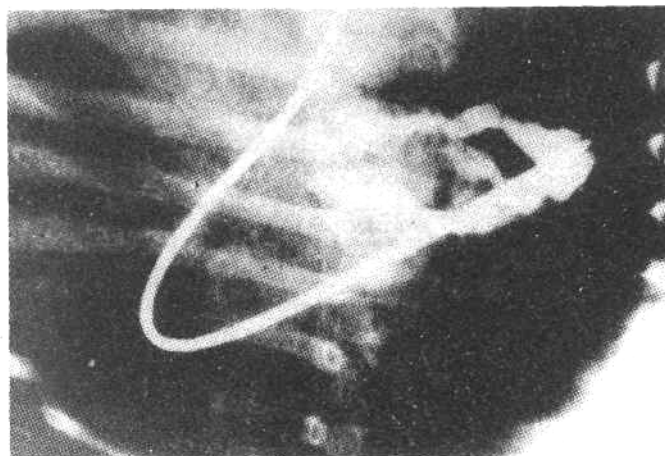


Fig. 2. Selective pulmonary arterial angiogram delineating multiple large AVF arising from a hypertrophied branch of the right pulmonary artery.

Discussion

Pulmonary AVF is a rare but interesting malformation that results in cyanosis in the presence of a normal cardiac examination. The patient in addition may have dyspnea, clubbing and clinical evidence of

paradoxical embolisation and may present as a brain abscess in 6%(5). Other rare modes of presentation may be hemoptysis, bacterial endocarditis and spontaneous hemothorax(6). These fistulas are often a manifestation of congenital hemorrhagic telangiectasia (Osler-Weber-

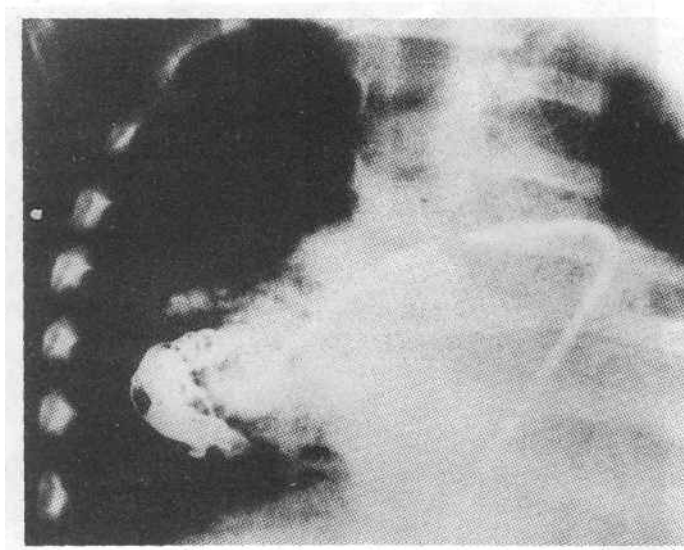


Fig. 3. Multiple indigenously made coils within the pulmonary AVF released through a 7F Swan-Ganz catheter

Rendu syndrome)(5). Ninety five per cent patients have abnormalities on chest X-ray, most of which are seen in the lower lobes(1) and may be misinterpreted as infiltrates, metastatic lesions or coin lesions. Changing arterial blood gases with change in posture is highly suggestive of the diagnosis (orthodeoxia-platypnea).

The diagnosis can be confirmed by peripheral venous contrast echocardiography. The contrast material (agitated saline) reaches the left heart by flowing through the AVF, thus avoiding filtration in the pulmonary capillary bed. Late appearance of contrast in the left atrium allows differentiation of a pulmonary AVF from a right to left atrial shunt(7). Angiography is indicated before surgery or attempts at occlusion, in patients with large, symptomatic AVF, for precise anatomic details as it delineates the size and number of fistulas(5).

Treatment is indicated if the AVF is enlarging, gives rise to hypoxemia with secondary polycythemia or paradoxical

embolisation(1). As most fistulas are immediately subpleural, ligation of feeding vessels and extirpation or oversewing can be performed with minimal loss of lung tissue. For more severely effected lobes, segmental resection or lobectomy may have to be performed. The disadvantage of these techniques is that the development of new AVFs and growth of pre-existing AVFs in other lobes may necessitate further surgical procedures and reduce the total capacity of the lungs to dangerously low levels. The operative mortality of segmental resections is 5% with an overall cure rate of 75%(8).

In the infant or child, surgical lobectomy carries the additional morbidity of chest wall deformity and secondary alterations in pulmonary mechanics. Transcatheter therapy provides an advantage in such patients, and is considered by some to be the treatment of choice for most pulmonary AVFs. Percutaneous embolisation is particularly useful for

multiple AVFs and in patients who are not good surgical candidates(3,4). Morbidity is minimal, although balloon migration and recanalisation of the AVF can occur (5). The other complications include systemic embolisation, pulmonary infarction, faulty placement of coils and early deflation of balloons(2). When combined with selective surgical resection, lung tissue can be preserved. However, long term follow up is essential as residual fistulas may enlarge.

The procedure is cost effective. Although in our patient the risk of embolisation is not eliminated and he continues to be cyanosed, there is significant symptomatic improvement.

In conclusion, an infant with pulmonary AVF is reported, in whom embolisation using indigenous coils resulted in significant clinical improvement.

REFERENCES

- 1 Dines DE, Seward JB, Bernatz PE. Pulmonary arterio-venous fistulas. *Mayo Clin Proc* 1983, 58:176-181.
- 2 Barth CH, White RI, Kaufman SL, Terry PB, Roland JM. Embolotherapy of pulmonary arterio-venous malformations with detachable balloons. *Radiology* 1982, 142: 599-606.
- 3 Castineda ZW, Zollikofer C, Epstein M, *et al.* Embolisation of multiple pulmonary artery fistulas. *Radiology* 1980,134: 309.
- 4 Hatfield DR, Fried AM. Therapeutic embolisation of diffuse pulmonary arterio-venous malformations. *AJR* 1981, 137: 861.
- 5 Walder AL, Anastasia LF, Spodik DH. Pulmonary arterio-venous malformations with brain abscess. *Am Heart J* 1994, 127: 227-232.
- 6 Wallenhaupt SL, D'Souza V. Combined radiological and surgical management of arterio-venous malformation of the lung. *Ann Thorac Surg* 1988, 45: 213-215.
- 7 Snider RA, Sarwer GA. Abnormal vascular connections and structures. *In: Echocardiography in Pediatric Heart Disease*. Chicago, Year Book Medical Publishers, 1990, pp 273-274.
- 8 Preminger TJ, Perry SB, Burrows PE. Vascular anomalies. *In: Moss and Adams Heart Disease in Infants, Children and Adolescents*, 5th edn. Ed. Pine JW. Baltimore, Williams and Wilkins, 1995, pp 802-804.