

# **Surveillance for Developmental Dysplasia of the Hip in India: Consensus Guidelines From the Pediatric Orthopaedic Society of India, Indian Academy of Pediatrics, National Neonatology Forum of India, Indian Radiological and Imaging Association, Indian Federation of Ultrasound in Medicine and Biology, Federation of Obstetric and Gynaecological Societies of India, and Indian Orthopaedic Association**

**ALARIC AROOJIS,<sup>1</sup> RAJENDRA PRASAD ANNE,<sup>2</sup> JACQUELINE LI,<sup>3</sup> EMILY SCHAEFFER,<sup>3</sup> TMANANDA KESAVAN,<sup>4</sup>  
SAMIR SHAH,<sup>5</sup> SANDEEP PATWARDHAN,<sup>6</sup> ALKA KARNIK<sup>7</sup>, UDAY THANAWALA<sup>8</sup>**

*From <sup>1</sup>Department of Pediatric Orthopaedics, Bai Jerbai Wadia Hospital for Children, Acharya Donde Marg, Parel, Mumbai, Maharashtra; <sup>2</sup>Department of Pediatrics, All India Institute of Medical Sciences, Hyderabad, Telangana; <sup>3</sup>Department of Orthopaedics, BC Children's Hospital, University of British Columbia, Vancouver, BC, Canada; <sup>4</sup>Department of Pediatrics, Government Medical College, Thrissur, Kerala; <sup>5</sup>Samir Hospital, Vadodara, Gujarat; <sup>6</sup>Department of Orthopaedics, Sancheti Institute for Orthopaedics and Rehabilitation, Pune, Maharashtra; <sup>7</sup>Department of Ultrasonography, Max Nanavati Superspeciality Hospital, Mumbai, Maharashtra; <sup>8</sup>Department of Gynaecology, Thanawala Maternity Home, Vashi, Navi Mumbai, Maharashtra. Correspondence to: Dr Alaric Aroojis, Department of Pediatric Orthopaedics, Bai Jerbai Wadia Hospital for Children, Acharya Donde Marg, Parel, Mumbai 400 012, Maharashtra. aaroojis@gmail.com*

**Justification:** When developmental dysplasia of the hip (DDH) is diagnosed during infancy, conservative management is often successful, with good long-term outcomes. In India, DDH is often not diagnosed until walking age and there are limited guidelines for its screening.

**Process:** A multidisciplinary Expert Group consisting of members of the Paediatric Orthopaedic Society of India, Indian Academy of Pediatrics, National Neonatology Forum of India, Indian Radiological and Imaging Association, Indian Federation of Ultrasound in Medicine and Biology, Federation of Obstetric and Gynaecological Societies of India, and Indian Orthopaedic Association worked collaboratively to develop surveillance guidelines for DDH.

**Objectives:** To enhance the early detection rate of DDH in India through development and implementation of a standardized surveillance care pathway, thus reducing the burden of late-presenting DDH.

**Recommendations:** Routine clinical hip examinations must be performed on all infants at birth and during immunization visits at these approximate time points: 6, 10, and 14 weeks; 6, 9, 12, 15, and 18 months of age. Assessments include Ortolani and Barlow tests for infants <14 weeks; limited hip abduction and leg length discrepancy for infants >14 weeks; and evaluation of limp in walking children. If clinical examination is abnormal or inconclusive, referral to orthopedics for further evaluation and management is recommended. In infants younger than 6 weeks with positive Barlow test but negative Ortolani test, hip ultrasound is recommended at 6 weeks of age. Infants must also be screened for DDH risk factors: breech presentation, family history of DDH, unsafe hip swaddling, and hip instability at any previous clinical examination. In infants with risk factors but normal clinical examination, further evaluation should include ultrasound taken no earlier than 6 weeks of age for infants younger than 14 weeks, ultrasound or X-ray for infants 14 weeks to 6 months of age, and X-ray for infants older than 6 months. Referral to an orthopedic surgeon is recommended if radiological tests are abnormal.

**Keywords:** *Care pathway, Early detection, Hip dislocation, Screening.*

**Published online:** March 28, 2022; **PII:** S097475591600416

**D**evelopmental dysplasia of the hip (DDH) represents a wide spectrum of hip abnormalities, present at birth or developed during infancy, that ranges from sub-clinical dysplasia to complete hip dislocation [1]. When DDH is diagnosed and treated during infancy, conservative management is often successful at achieving a safe and effective reduction with good long-term outcomes [2-5]. In contrast, DDH that is diagnosed after the child starts walking often results in the

need for more complex surgical reconstructive procedures and can lead to significant morbidity [4-7]. A recent scoping review [8] estimated the incidence of DDH in India to be between 0-75 per 1000 live births when considering the entire spectrum of hip dysplasia, but the incidence of true DDH to be between 0-2.6 per 1000 live births. Until now, only limited guidelines have been available for DDH screening in India and DDH is often not diagnosed until the child starts walking [8-10]. The aim of this guideline is to enhance the early

detection of DDH through the development of a standardized surveillance care pathway, thus reducing the burden of late-presenting DDH. This guideline has been developed specifically for the Indian context, with the goal of identifying all cases of hip dislocation, instability and dysplasia before the child starts walking, but ideally before six months of age.

## OBJECTIVES

To devise consensus guidelines for surveillance and diagnosis of DDH in India, so as to help healthcare providers detect most cases of DDH before walking age, and ideally before six months of age.

## PROCESS

A multidisciplinary Expert Group consisting of members of the Paediatric Orthopaedic Society of India (POSI), Indian Academy of Pediatrics (IAP), National Neonatology Forum of India (NNFI), Indian Radiological and Imaging Association (IRIA), Indian Federation of Ultrasound in Medicine and Biology (IFUMB), Federation of Obstetric and Gynaecological Societies of India (FOGSI), and Indian Orthopaedic Association (IOA) was convened. The Executive Committee of each organization nominated representatives from various regions of the country to join the group, based on their expertise in DDH and leadership within their respective organizations. Care was taken to include representatives from all five zones of India and a wide range of experts working in the Government public healthcare sector, private sector and university teaching hospitals. Two representatives (one from IAP and one from IOA) represented the rural population. The resulting expert group, designated as the DDH India Care Pathway Working Group, worked collaboratively to develop a list of consensus statements that were used to frame surveillance guidelines for DDH screening in India, as outlined in this document.

The guidelines were developed by the Expert Group, with technical support from the Department of Orthopaedics at the University of British Columbia, Canada. A three-phased process was used, consisting of a preparatory phase, a consensus-building phase, and a writing phase. The study methodology used in developing the guidelines was reported and published earlier [11]. In the initial phase, members reviewed the existing evidence during a series of virtual meetings beginning on 31 May, 2020 and concluding on 2 August, 2020. Group members participated in an informal literature review process in which presenters synthesized relevant high-quality articles on designated topics, including the incidence of DDH in India, clinical examination, the role of imaging, and comparisons of existing screening programs. A repository of literature was created and stored on a cloud-based server for group members to

access at their convenience. In addition to the articles selected for group discussion, the repository included publications cited in a recent systematic review of DDH in children younger than 6 months [12], on the Delphi consensus process, and other articles selected by group members. Key topics included clinical examination, risk factors, the role of ultrasound and X-ray, and management of DDH. A preliminary survey of NNFI and IAP membership was designed and circulated to understand their knowledge and practices regarding DDH.

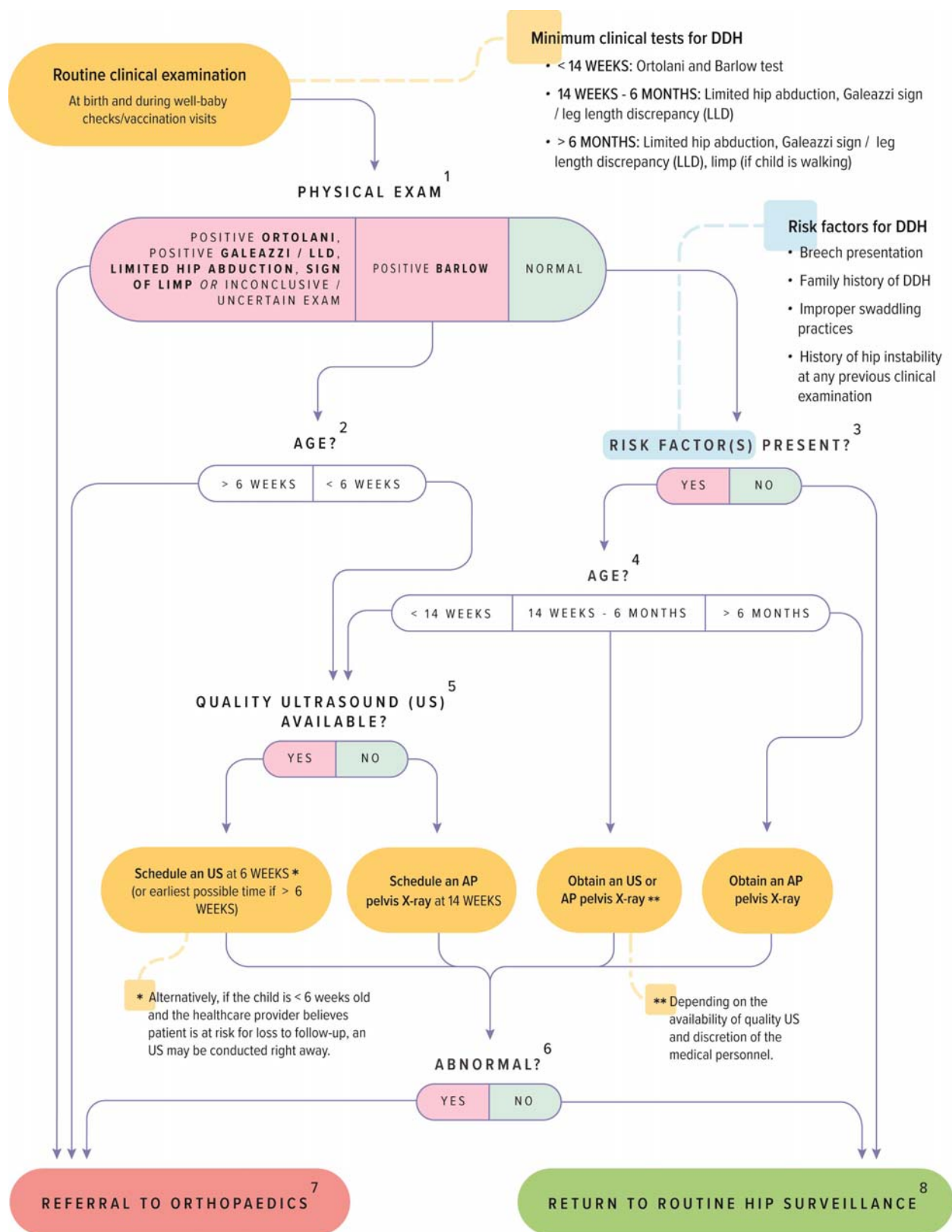
*Delphi process:* During the second phase, which began on 15 October, 2020, group members participated in the Delphi process to reach consensus on a list of statements about DDH screening that were used to frame the guideline. The Delphi approach employed two online rounds of surveys along with virtual meetings between each round until consensus was achieved [11,13].

Upon the conclusion of the consensus-building phase on 10 February, 2021, the final guidelines were drafted by a core writing group and then distributed to the Expert Group for feedback. During a final consensus meeting on 14 March, 2021, the group reviewed the guidelines prior to finalization and endorsement by the participating organizations. While no formal external review was performed, DDH experts from Canada (who were part of the American Academy of Orthopaedic Surgeons Clinical Practice Guidelines development) were integrated into the process to bring perspective from outside of the Indian context.

## GUIDELINES

The Rashtriya Bal Swasthya Karyakram (RBSK) program under the National Health Mission (NHM) aims at providing child health screening and early intervention services for a number of pediatric conditions, including DDH. This current guideline aims to expand and elaborate upon the RBSK program, improving practicability, feasibility and effectiveness. The guidelines (**Fig. 1**) are broad in order to remain applicable to India's diverse public and private healthcare settings. The guidelines have been developed for use by a wide cadre of clinical healthcare providers, especially pediatricians, neonatologists, primary care physicians and other trained healthcare providers who care for children, so as to maximize uptake across the country.

The focus of this guideline is on 'surveillance' rather than 'screening' – emphasizing the concept of periodic physical examinations as part of regular well baby checks/immunization visits until the child is of walking age. For the Indian context, we have recommended regular clinical examination of the hips at every well-baby check/immunization visit in addition to selective imaging using ultrasound or X-ray for any baby with abnormal clinical



**Fig. 1** Flowchart showing clinico-radiological surveillance protocol for screening infants for developmental dysplasia of the hip (copyrighted to the Paediatric Orthopaedic Society of India (POSI) and reproduced with permission).

finding(s) and/or risk factor(s) present. These recommendations are in alignment with those of the Pediatric Orthopedic Society of North America (POSNA), the American Academy of Pediatrics (AAP), the American Academy of Orthopaedic Surgeons (AAOS), and the Canadian Task Force on DDH.

To create ease of use, the recommended periodic hip examinations have been aligned with the immunization schedule recommended under the Universal Immunization Programme (UIP) and Government of India.

### Terminology

**Quality ultrasound:** Refers to both accessibility of ultrasound and expertise in interpretation of its results in the area of practice, at the discretion of the screener. While ultrasound facilities are widely available in urban areas and even in rural regions of India, diagnostic ultrasound is tightly controlled under the restrictive Pre-Conception and Pre-Natal Diagnostic Techniques (PCPNDT) Act, 1994. Furthermore, expertise in performing and interpreting pediatric musculoskeletal ultrasound is often lacking in the country, and this must be considered by the healthcare provider while choosing the appropriate imaging tool for screening.

**Routine hip surveillance:** Refers to regular clinical hip examinations using age-appropriate tests that occur at birth and during well-baby checks/immunization visits.

**Referral to Orthopedics:** Referral should be to a pediatric orthopedic/orthopedic surgeon. While a pediatric orthopedic surgeon is preferable, whenever possible, an orthopedic surgeon is sufficient if a pediatric orthopedic surgeon is not available in the area of practice.

**Inconclusive Exam:** Refers to instances where the healthcare provider performing the clinical examination suspects hip instability or dysplasia but is uncertain of the clinical finding, or the examination lacks a definitive positive or negative result. If the examiner is unsure of the clinical examination or has reason for heightened suspicion of DDH, referral to a pediatric orthopedic/orthopedic surgeon is prudent so as not to miss a potential case.

### Clinical Examination Schedule

All babies should undergo routine clinical examinations of the hip to check for hip dysplasia. A newborn clinical examination is universally accepted to screen for DDH [14-16]. Clinical hip examinations will primarily be performed by pediatricians, neonatologists, and primary care physicians, but can be performed by any trained clinical healthcare provider involved in the care of children, including paramedical personnel. These examinations should occur at birth, before the baby and mother are discharged, and also

during well-baby checks/immunization visits. To align with the national immunization schedule as much as possible, these examinations should occur at these approximate time points: at birth, 6 weeks, 10 weeks, 14 weeks, 6 months, 9 months, 12 months, 15 months, and 18 months of age.

### Minimum Clinical Tests

There are many clinical tests that can be used to screen for DDH. The minimum clinical tests that are required for each age group are outlined in **Table I** and **Fig. 2**.

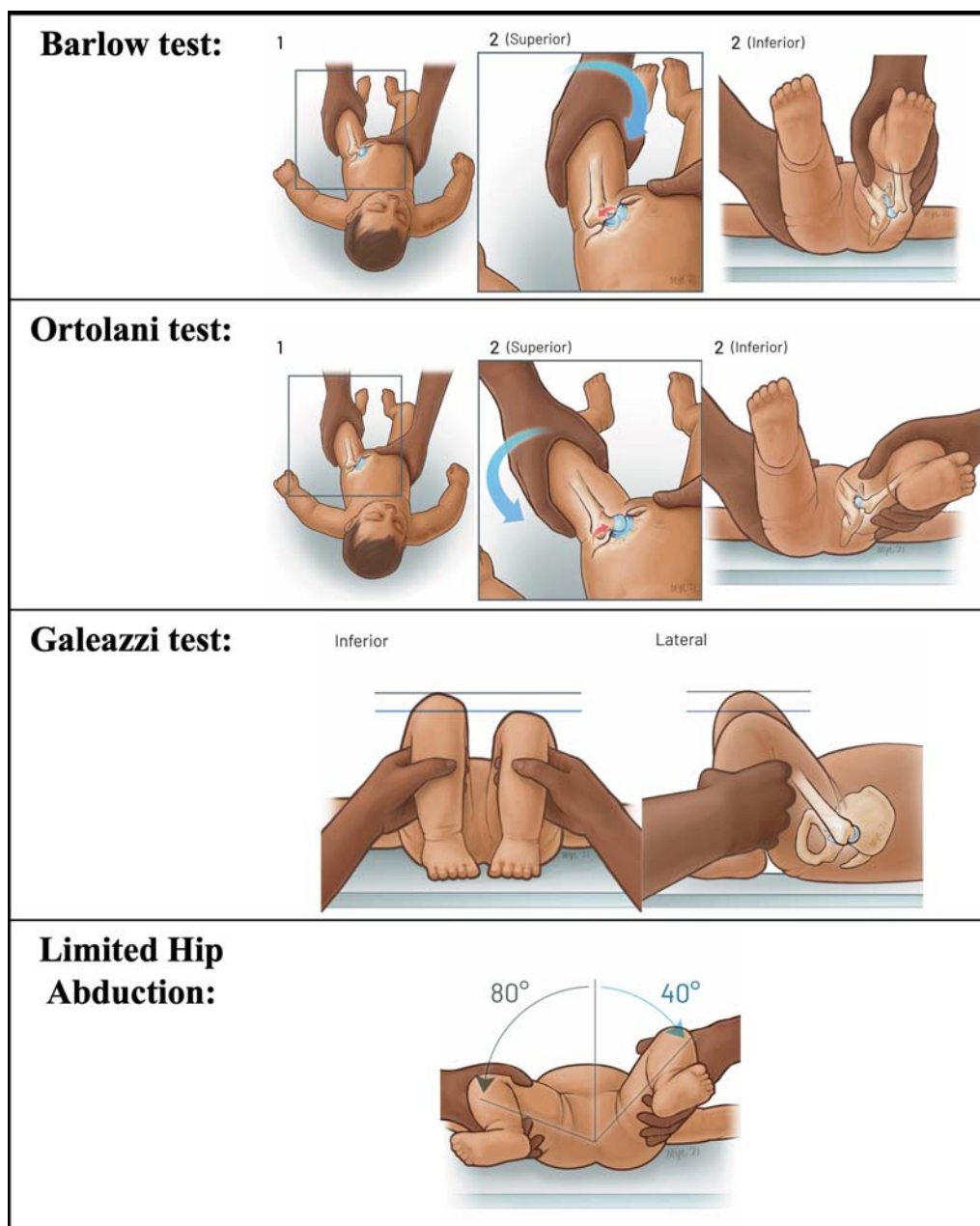
The Barlow and Ortolani tests (**Fig. 2a** and **b**) were established in the 1960s as critical clinical tests to determine instability and reducibility in the infant hip [14,17,21]. Both these tests are most effective in early infancy (up to 3 months of age), since they tend to become negative as the baby grows [3,15,21]. Consequently, other clinical tests such as leg length discrepancy (Galeazzi sign) (**Fig. 2c**) and limited hip abduction (LHA) (**Fig. 2d**) become more valuable over time [5,18-20]. Unilateral limitation of hip abduction beyond eight weeks of age is an important clinical indicator of pathologic DDH, with high specificity (>90%) and moderate sensitivity (>70%) [18,19]. A limp in the walking child can also indicate DDH. Bilateral hip dislocations can lead to hyperlordosis of the lumbar spine (exaggerated C-shaped lumbar curve) and a waddling gait. Unilateral dislocations may cause a short limb gait and a Trendelenburg lurch, in which the pelvis fails to remain in the neutral position but tilts downwards to the unaffected side.

### Imaging Guidelines

**Ultrasound:** An ultrasound can be used as a screening tool anytime from birth to six months of age, provided that quality ultrasound imaging and interpretation is available. Beyond six months of age, the appearance and growth of the ossification centre of the femoral head begins to obscure key sonographic landmarks including the ilium [22,23]. Expertise in performing and correctly interpreting musculoskeletal ultrasound, especially in an infant, may not be uniformly available, and thus, these guidelines provide practical alternatives if ultrasound accessibility and expertise is an issue.

**Table I Clinical Tests for Screening for Developmental Dysplasia of the Hip As Per Age of the Baby**

<14 wk of age	14 wk – 6 mo	> 6 mo
Ortolani test [17]	Limited hip abduction [5,18-20]	Limited hip abduction [5,18-20]
Barlow test [14]	Galeazzi sign /leg length discrepancy (LLD) [5,20]	Galeazzi sign/leg length discrepancy (LLD) [5,20] Limp (if child is walking) [5,20]



**Fig. 2** Pictorial representation of various clinical tests used for screening of developmental dysplasia of the hip in infants (copyrighted to the International Hip Dysplasia Registry (IHDR) and reproduced with permission); *a*) The Barlow provocative test is performed with the newborn positioned supine and the hips flexed to  $90^{\circ}$ . The leg is then gently adducted while posteriorly directed pressure is placed on the knee. A palpable clunk or sensation of movement is felt as the femoral head exits the acetabulum posteriorly – this is a positive Barlow sign, which indicates hip instability; *b*) The Ortolani maneuver is performed with the newborn in the supine position and the examiner's index and middle fingers placed along the greater trochanter with the thumb placed along the inner thigh. The hip is flexed to  $90^{\circ}$ , and the leg is held in neutral rotation. The pelvis is stabilized with the other hand and the hip is gently abducted while lifting the leg anteriorly. With this maneuver, a “clunk” is felt as the dislocated femoral head reduces into the acetabulum; *c*) The Galeazzi test is conducted with the infant supine, on a firm, flat surface with the pelvis stabilized and level. The hips are flexed to  $90^{\circ}$  and placed in neutral adduction/abduction, with knees in flexion. In this position, the vertical level of the knees can be assessed for asymmetry; and *d*) The clinical assessment of limited hip abduction (LHA) is made with the child supine with both hips flexed to  $90^{\circ}$  and full abduction of both hip joints is attempted. Any block to full abduction is noted from the horizontal, and the sign is considered positive if there is a limitation of  $>20^{\circ}$  as compared to the opposite hip in unilateral cases or if  $<60^{\circ}$  of hip abduction is possible on each side in bilateral cases [18-20].

**X-ray:** The earliest that an X-ray can be used as a screening tool is at 14 weeks of age. The recommended time to transition from ultrasound to X-ray imaging screening is between 4-6 months of age, as this is when the femoral head ossific nucleus typically becomes visible radio-graphically [5,24,25]. However, the working group reached consensus to give healthcare providers the option to perform an X-ray slightly earlier (14 weeks), as this aligns with the national immunization schedule and ensures that infants requiring imaging can still be screened if quality ultrasound is not available. The International Hip Dysplasia Institute (IHDI) classification [26] is a reliable radiographic system to quantify DDH severity using the midpoint of the proximal femoral metaphysis, rather than the femoral head utilized in the commonly used Tonnis criteria [26]. Consequently, the IHDI classification holds value even prior to ossification of the femoral head, enabling the use of X-ray when needed in these younger infants. Use of X-ray in this younger age group is only recommended if quality ultrasound is not available; in order to prevent potential missed cases that may arise if left without surveillance until after four months of age. A single antero-posterior (AP) pelvis radiograph is required for DDH screening, without the need of a frog-leg lateral radiograph [27].

Key imaging recommendations are outlined in **Box I**.

## Guidelines As Per the Age of the Child

### 1. Baby younger than six weeks

**Clinical tests:** The minimum clinical tests for babies less than six weeks of age include both Ortolani and Barlow tests.

**Positive clinical examination:** If the Ortolani test is positive, the baby should immediately be referred to a pediatric orthopedic/orthopedic surgeon for further management. This recommendation is consistent with the AAOS Appropriate Use Criteria (AUC) and AAP Guidelines [15,28].

#### **Box I Imaging Recommendations for Developmental Dysplasia of the Hip**

##### *Younger than 6 weeks*

**Recommendation:** Ultrasound at 6 weeks of age.

**Alternative approach:** Ultrasound immediately, if potential for loss to follow-up. X-ray at 14 weeks of age, if quality ultrasound unavailable.

##### *6 to <14 weeks*

**Recommendation:** Ultrasound at earliest possible time.

**Alternative approach:** X-ray at 14 weeks of age, if quality ultrasound unavailable.

##### *14 weeks to 6 months*

**Recommendation:** Ultrasound or AP pelvis X-ray, depending on availability.

##### *Older than 6 month*

**Recommendation:** Antero-posterior pelvis X-ray.

**Positive Barlow test:** If the Barlow test is positive, the baby does not require immediate referral to orthopedics, as these hips may spontaneously resolve [29]. Ideally, babies with a positive Barlow test should wait to obtain an ultrasound at six weeks of age, consistent with the AAOS AUC [28]. Prior to six weeks of age, most hip instability and morphologic abnormalities detected on ultrasound are due to immaturity of the hip joint. Most of these abnormalities spontaneously resolve during normal maturation and development of the hip joint in infancy [30,31]. Thus, ultrasound performed before six weeks of age is prone to detecting morphologic abnormalities that will self-resolve over time. However, if the examiner believes the baby is at risk for loss to follow-up, an ultrasound can be obtained right away. If quality ultrasound is not easily available, an AP pelvis X-ray should be scheduled at 14 weeks of age. Any abnormal imaging findings on ultrasound at 6 weeks or X-ray at 14 weeks should prompt a referral to orthopedics, again consistent with the AAOS AUC [28]. If imaging is normal, the baby can return to routine hip surveillance. Alternatively, if the first imaging is normal, an examiner can choose to schedule an additional follow-up X-ray at six months. This additional follow-up imaging for a baby with an initial positive Barlow test is recommended, particularly if there are also risk factor(s) present.

**Normal clinical examination:** If clinical examination is normal, babies must undergo risk factor screening, as the AAOS clinical practice guideline (CPG) found that there is moderate evidence to support additional imaging before six months of age for infants with breech presentation, family history of DDH or history of clinical hip instability [32].

**Inconclusive exam:** If the clinical exam is inconclusive or uncertain, the baby should be referred to a pediatric orthopedic/orthopedic surgeon for further assessment.

### 2. Age between 6 to 14 weeks

**Clinical tests:** The minimum clinical tests for babies in this age range include both Ortolani and Barlow tests.

**Positive Ortolani and/or positive Barlow test:** If the Ortolani and/or Barlow tests are positive, the baby should be referred to a pediatric orthopedic/orthopedic surgeon. This recommendation is consistent with the AAOS AUC [28].

**Normal clinical examination:** If clinical examination is normal, the baby must undergo risk factor screening.

**Inconclusive examination:** If the clinical exam is inconclusive or uncertain, the baby should be referred to a pediatric orthopedic/orthopedic surgeon.

### 3. Age between 14 weeks and 6 months

**Clinical tests:** The minimum clinical tests for babies in this age range include both limited hip abduction and Galeazzi

sign/leg length discrepancy (LLD).

*Limited hip abduction and/or positive Galeazzi sign/LLD:* If the baby has limited hip abduction and/or a positive Galeazzi sign/LLD, the baby should be referred to a pediatric orthopedic/orthopedic surgeon, consistent with the AAOS AUC[28].

*Normal clinical examination:* If clinical examination is normal, the baby must undergo risk factor screening [32].

*Inconclusive examination:* If the examination is inconclusive or uncertain, the baby should be referred to a pediatric orthopedic/orthopedic surgeon.

#### 4. Baby older than 6 month

*Clinical tests:* The minimum clinical tests for babies >6 months who are younger than the age of walking include limited hip abduction and Galeazzi sign/leg length discrepancy (LLD). If the baby is walking, the minimum tests include limited hip abduction, Galeazzi sign/LLD, and limp.

*Limited hip abduction and/or Positive Galeazzi sign/LLD and/or Sign of limp:* If the baby has one or more positive clinical tests (limited hip abduction, positive Galeazzi sign/LLD, sign of limp), they should be referred to a pediatric orthopedic/orthopedic surgeon.

*Normal clinical examination:* If clinical examination is normal, the baby must undergo risk factor screening.

*Inconclusive examination:* If the examination is inconclusive or uncertain, the baby should be referred to a pediatric orthopedic/orthopedic surgeon.

#### Risk Factor Screening

All babies should be assessed for the presence of risk factors along with their clinical examination. With a normal clinical examination, the baby's risk factor status becomes important, since defined risk factors warrant additional screening regardless of clinical examination status. While girls are approximately 4-5 times more likely than boys to have DDH, with girls born breech having the highest risk [33], female sex alone will not be used as an indication for risk factor screening in this surveillance guideline. The risk factors are listed in **Box II**.

*No risk factor(s) present:* If no risk factors are present, the baby can return to routine hip surveillance.

*One or more risk factors present:* If one or more risk factors are present, the baby will require further imaging. The recommended imaging (ultrasound vs X-ray) will depend on the age of the child and the availability of the imaging tool (**Box I**). The AAOS clinical practice guideline described two moderate strength studies that suggested a significant role for further imaging in infants with risk factors of family

history, breech presentation or history of clinical instability in order to prevent late detection of dysplasia or dislocation [39,43].

Any abnormal imaging findings should prompt a referral to orthopedics. If imaging findings are normal, the baby can return to routine hip surveillance.

#### Guidelines in the context of RBSK Program

The RBSK program provides valuable screening, examination and care recommendations for the detection and treatment of DDH in the government and public healthcare sector in India. The RBSK recommends that screening for DDH occur at the public health facility level at birth by Auxiliary Nurse Midwives (ANMs), Medical officers (MOs) or gynecologists, and by the mobile health team at anganwadi centers at six weeks and beyond. Children with positive clinical findings and/or risk factors are referred to the District Early Intervention Centre (DEIC) or District Hospital (DH) for further examination, imaging and treatment. Under the RBSK program, screening/examination is recommended to occur at birth, 6 weeks, and at 3, 6 and 12 months. The intent of the current guideline is to integrate, where applicable, with the existing RBSK guidelines and improve practicality and feasibility of its successful implementation. Endorsement by national professional organizations, whose members provide healthcare to children, will encourage adoption of these guidelines especially for infants who do not access public healthcare and hence do not come under the ambit of the RBSK

#### Box II Risk Factors For DDH Screening

Breech presentation at any point after 36 weeks of pregnancy, irrespective of presentation at birth or mode of delivery.

Family history of DDH, defined as first-degree (parents, siblings) or second-degree (grandparents, aunts, uncles) relatives diagnosed with DDH.

Improper swaddling practices. Swaddling is the traditional practice of wrapping a baby in cloths or blankets that can tightly restrict limb movements. While swaddling has been shown to have several beneficial effects for the newborn, tight swaddling of the legs with the hips in extension and adduction can tighten the muscles around the hip joint and predispose to hip dislocation. 'Hip-safe swaddling' permits the lower limbs of the infant to be positioned loosely in a frog-leg attitude within the swaddle and allows space for the legs to have unrestricted flexion-abduction movements, facilitating normal hip development.

Presence of hip instability at any previous clinical examination.

*Prepared from references 34-42. Other risk factors historically associated with DDH, such as, oligohydramnios, multiple pregnancy, foot deformities, torticollis, asymmetric thigh or gluteal skin creases, and hip clicks, have not been included among risk factors warranting screening due to the lack of strong evidence of association. DDH - developmental dysplasia of the hip.*



program. A key difference this guideline presents from the RBSK program is a more structured surveillance schedule that links hip examinations with immunization visits. While the recommended clinical examinations are similar between the two guidelines (Ortolani/Barlow tests, limited hip abduction, Galeazzi sign/leg length discrepancy), the current guideline elaborates more on age-appropriate clinical tests and provides clear guidelines for referral. Additionally, the RBSK does not address availability of quality ultrasound, and consequently, does not discuss the important role of X-rays when ultrasound access is lacking.

### Limitations

There are a few limitations to these guidelines. First, patients/families were not included as stakeholders in the care pathway development process. To facilitate timely completion and practicability of the project, a decision was made to develop the pathway with relevant medical experts and stakeholders, and instead include patients/families in the implementation and knowledge translation phases. Second, the expert group lacked sufficient representation from rural areas, a limitation that will be addressed by recruiting involvement and input from rural practitioners in the implementation process. Third, discussion of the management of DDH was not within the purview of these guidelines. The aim was to develop screening and surveillance guidelines to ensure a timely referral to a pediatric orthopedic/orthopedic surgeon, who would offer appropriate management using established treatment protocols.

We provide consensus guidelines for screening and surveillance of DDH in India (**Table II**), targeting the practicing pediatricians and trained healthcare workers in the country. We feel that widespread adoption of these will improve the outcomes of children with DDH with early diagnosis and timely initiation of treatment.

**Acknowledgements:** The guidelines development process was supported by office-bearers of following organizations: Indian Academy of Pediatrics: Bakul Parekh, President 2020; GV Basavaraja, Secretary-General 2020-21; Samir Dalwai, Joint Secretary - Admin 2020-21. National Neonatology Forum of India: Ashok Deorari, President, 2020; Ranjan Pejaver, President, 2021; Lalan Bharti, Secretary, 2020. Federation of Obstetric and Gynaecological Societies of India: Alpesh Gandhi, President, 2020. Indian Orthopaedic Association: B Shivashankar, President, 2021; Atul Shrivastava, Vice-President, 2021; Rajesh Gupta, Chairman, IOA Rural Committee, 2020.

**Contributors:** AA, ES, JL: conceptualised and designed the study; AA, RPA, ES, JL: wrote the first draft of the manuscript. All authors commented on and edited initial versions of the manuscript. All authors read and approved the final manuscript. All authors agree to be accountable for all aspects of the work.

**Funding:** Partially funded by I'm a HIPpy Foundation, the Peterson Fund for Global Hip Health, the Divis Foundation for Gifted Children, and BC Children's Hospital Foundation.

**Competing interest:** None stated.

### REFERENCES

1. International Hip Dysplasia Institute. What is Hip Dysplasia? Available from: <https://hipdysplasia.org/developmental-dysplasia-of-the-hip>. Accessed December 20, 2021.

**Table II Summary of Guidelines for Screening for Developmental Dysplasia of the Hip**

<i>Clinical workup</i>	<i>Imaging recommendations</i>	<i>Timing for referral to orthopedics</i>
<i>Risk factors</i>	<i>Indications for imaging</i>	<i>Urgent</i>
Breech presentation	One or more risk factor(s) present	Abnormal imaging findings
Family history of DDH	Positive Barlow in baby <6 wk	Abnormal clinical exam:
Improper swaddling practices	Inconclusive/uncertain clinical exam	- Positive Ortolani
History of hip instability in any previous clinical exam		- Positive Barlow in baby >6 wk
	<i>Age-dependent imaging recommendations</i>	- Limited hip abduction
<i>Clinical tests</i>	6 wk ultrasound for babies <6 wk of age	- Positive Galeazzi test/leg length discrepancy
Ortolani test (<14 wk)	Immediate ultrasound for babies 6-14 wk of age	Limp in walking age child
Barlow test (<14 wk)	Immediate ultrasound or AP pelvis X-ray for babies between 14 wk-6 mo of age	
Limited hip abduction (>14 wk)	Immediate AP pelvis X-ray for babies >6 mo of age	<i>Not urgent</i>
Galeazzi test/leg length discrepancy (>14 wk)		Positive Barlow in baby <6 wk <sup>a</sup>
Sign of limp (walking age)	<i>Imaging alternatives:</i>	<i>Referral not required</i>
	Ultrasound before 6 wk of age if baby is at risk for loss to follow-up	Normal physical exam and no risk factors present
	AP pelvis X-ray not earlier than 14 wk of age if quality ultrasound is not available	Normal imaging findings

<sup>a</sup>May spontaneously resolve. Only refer if first imaging is abnormal.



2. Cashman JP, Round J, Taylor G, Clarke NM. The natural history of developmental dysplasia of the hip after early supervised treatment in the Pavlik harness. A prospective, longitudinal follow-up. *J Bone Joint Surg Br.* 2002;84:418-25.
3. Guille JT, Pizzutillo PD, MacEwen GD. Development dysplasia of the hip from birth to six months. *J Am Acad Orthop Surg.* 2000;8:232-42.
4. St George J, Kulkarni V, Bellemore M, Little DG, Birke O. Importance of early diagnosis for developmental dysplasia of the hip: A 5-year radiological outcome study comparing the effect of early and late diagnosis. *J Paediatr Child Health.* 2021; 57:41-45.
5. Yang S, Zusman N, Lieberman E, Goldstein RY. Developmental dysplasia of the hip. *Pediatrics.* 2019;143:e20181147.
6. Lucchesi, G, Sacco R, Zhou W, et al. DDH in the walking age: Review of patients with long-term follow-up. *Indian J Orthop.* 2021;55:1503-14.
7. Murphy RF, Kim YJ. Surgical management of pediatric developmental dysplasia of the hip. *J Am Acad Orthop Surg.* 2016; 24:615-24.
8. Chand S, Aroojis A, Pandey R, Johari AN. The incidence, diagnosis, and treatment practices of developmental dysplasia of hip (DDH) in India: A scoping systematic review. *Indian J Orthop.* 2021;55:1428-39.
9. Hooper N, Aroojis A, Narasimhan R, et al. Developmental dysplasia of the hip: An examination of care practices of orthopaedic surgeons in India. *Indian J Orthop.* 2020;55:158-68.
10. Rebello G, Joseph B. Late presentation of developmental dysplasia of the hip in children from southwest India-will screening help? *Indian J Orthop.* 2003;37:210-14.
11. Li J, Aroojis A, Mulpuri K, Shea Kg, Schaeffer EK. Development of a DDH care pathway for India: A study methodology to guide similar efforts in other countries and for other conditions. *Indian J Orthop.* 2021;55:1549-58.
12. Ashoor M, Abdulla N, Elgabaly EA, Aldiyami E, Alshryda S. Evidence based treatment for developmental dysplasia of the hip in children under 6 months of age. Systematic review and exploratory analysis. *Surgeon.* 2021;19:77-86.
13. Dalkey N, Helmer O. An experimental application of the DELPHI method to the use of experts. *Management Science.* 1963;9:458-67.
14. Barlow T. Early diagnosis and treatment of congenital dislocation of the hip. *J Bone Joint Surg [Br].* 1962;44-B:292-301.
15. Shaw BA, Segal LS. Evaluation and referral for developmental dysplasia of the hip in infants. *Pediatrics.* 2016;138:e20163107.
16. Omeroğlu H, Koparal S. The role of clinical examination and risk factors in the diagnosis of developmental dysplasia of the hip: A prospective study in 188 referred young infants. *Arch Orthop Trauma Surg.* 2001;121:7-11.
17. Ortolani M. Congenital hip dysplasia in the light of early and very early diagnosis. *Clin Orthop Relat Res.* 1976;119:6-10.
18. Choudry Q, Goyal R, Paton RW. Is limitation of hip abduction a useful clinical sign in the diagnosis of developmental dysplasia of the hip? *Arch Dis Child.* 2013;98:862-6.
19. Jari S, Paton RW, Srinivasan MS. Unilateral limitation of abduction of the hip. A valuable clinical sign for DDH? *J Bone Joint Surg Br.* 2002;84:104-7.
20. Storer SK, Skaggs DL. Developmental dysplasia of the hip. *Amer Fam Phys.* 2006;74:1310-6.
21. Grissom LE, Harcke HT. Ultrasonography and developmental dysplasia of the infant hip. *Curr Opin Orthop.* 2000;11:127-30.
22. Edmonds EW, Hughes JL, Bomar JD, Brooks JT, Upasani VV. Ultrasonography in the diagnosis and management of developmental dysplasia of the hip. *JBJS Rev.* 2019;7:e5.
23. Starr V, Ha BY. Imaging update on developmental dysplasia of hip with the role of MRI. *Am J Roentgenol.* 2014;203:1324-35.
24. Sewell MD, Rosendahl K, Eastwood DM. Developmental dysplasia of the hip. *BMJ.* 2009;339:b4454.
25. Tudor A, Sestan B, Rakovac I, et al. The rational strategies for detecting developmental dysplasia of the hip at the age of 4-6 months old infants: a prospective study. *Coll Antropol.* 2007; 31:475-81.
26. Narayanan U, Mulpuri K, Sankar WN, et al. Reliability of a new radiographic classification for developmental dysplasia of the hip. *J Pediatr Orthop.* 2015;35:478-84.
27. Hudak KE, Faulkner ND, Guite K, et al. Variations in AP and frog-leg pelvic radiographs in a pediatric population. *J Pediatr Orthop.* 2013;33:212-5.
28. American Academy of Orthopaedic Surgeons: Appropriate use criteria for the management of developmental dysplasia of the hip in infants up to six months of age: Intended for use by orthopaedic specialists. Accessed Jan 17, 2022. Available from: [https://www.aaos.org/globalassets/quality-and-practice-resources/pddh/ddh-auc\\_generalist\\_3.5.18.pdf](https://www.aaos.org/globalassets/quality-and-practice-resources/pddh/ddh-auc_generalist_3.5.18.pdf)
29. Cook KA, Schmitt M, Ingram M, Larson JE, Burgess J, Janicki JA. Pavlik Harness initiation on Barlow positive hips: Can we wait? *J Orthop.* 2019;16:378-81.
30. Bialik V, Bialik GM, Wiener F. Prevention of overtreatment of neonatal hip dysplasia by the use of ultrasonography. *J Pediatr Orthop B.* 1998;7:39-42.
31. Czubak J, Kotwicki T, Ponitek T, Skrzypek H. Ultrasound measurements of the newborn hip. Comparison of two methods in 657 newborns. *Acta Orthop Scand.* 1998;69:21-4.
32. Mulpuri K, Song KM, Goldberg MJ, Sevarino K. Detection and nonoperative management of pediatric developmental dysplasia of the hip in infants up to six months of age. *J Am Acad Orthop Surg.* 2015;23:202-5.
33. Lehmann HP, Hinton R, Morello P, Santoli J. Developmental dysplasia of the hip practice guideline: Technical report. Committee on Quality Improvement and Subcommittee on Developmental Dysplasia of the Hip. *Pediatrics.* 2000;105:e57.
34. Abu Hassan FO, Shannak A. Associated risk factors in children who had late presentation of developmental dysplasia of the hip. *J Child Orthop.* 2007;1:205-10.
35. de Hundt M, Vlemmix F, Bais JM, et al. Risk factors for developmental dysplasia of the hip: a meta-analysis. *Eur J Obstet Gynecol Reprod Biol.* 2012;165:8-17.
36. Imrie M, Scott V, Stearns P, Bastrom T, Mubarak SJ. Is ultrasound screening for DDH in babies born breech sufficient? *J Child Orthop.* 2010;4:3-8.
37. Kural B, Devcioğlu Karapınar E, Yılmazbaşı P, Eren T, Gökçay G. Risk factor assessment and a ten-year experience of DDH screening in a well-child population. *Biomed Res Int.* 2019;2019:7213681.
38. Ömeroğlu H, Akceylan A, Köse N. Associations between risk factors and developmental dysplasia of the hip and ultrasonographic hip type: a retrospective case control study. *J Child Orthop.* 2019;13:161-6.
39. Paton RW, Hinduja K, Thomas CD. The significance of at-risk factors in ultrasound surveillance of developmental dysplasia of the hip. A ten-year prospective study. *J Bone Joint Surg Br.* 2005;87:1264-6.
40. Stevenson DA, Mineau G, Kerber RA, Viskochil DH, Schaefer C, Roach JW. Familial predisposition to developmental dysplasia of the hip. *J Pediatr Orthop.* 2009;29:463-6.
41. Vaidya S, Aroojis A, Mehta R. Developmental dysplasia of hip and post-natal positioning: Role of swaddling and baby-wearing. *Indian J Orthop.* 2021;55:1410-6.
42. van Sleuwen BE, Engelberts AC, Boere-Boonekamp MM, Kuis W, Schulp TW, L'Hoir MP. Swaddling: a systematic review. *Pediatrics.* 2007;120:e1097-e1106.
43. Paton RW, Srinivasan MS, Shah B, Hollis S. Ultrasound screening for hips at risk in developmental dysplasia. Is it worth it? *J Bone Joint Surg Br.* 1999;81:255-58.

## ANNEXURE

**National DDH Expert Group**

**Project Lead:** Alaric Aroojis, *Mumbai, Maharashtra.*

**Paediatric Orthopaedic Society of India (POSI):** Dhiren Ganjwala, *Ahmedabad, Gujarat*; Ramani Narasimhan, *Delhi*; Sandeep Patwardhan, *Pune, Maharashtra*; Atul Bhaskar, *Mumbai, Maharashtra*; Rujuta Mehta, *Mumbai, Maharashtra*; Taral Nagda, *Mumbai, Maharashtra*; Thomas Palocaren, *Vellore, Tamil Nadu*; Sanjay Sarup, *Gurgaon, Haryana.*

**Indian Academy of Paediatrics (IAP):** Devender Gaba, *Delhi*; Samir Shah, *Vadodara, Gujarat*; Rashmi Dwivedi, *Bhopal, Madhya Pradesh*; G Sudhakar, *Kurnool, Andhra Pradesh*; Ananda Kesavan, *Thrissur, Kerala*; GP Kaushal, *Delhi*; A Somasundaram, *Chennai, Tamil Nadu*; Jaydeep Choudhury, *Kolkata, West Bengal*; Atanu Bhadra, *Asansol, West Bengal.*

**National Neonatology Forum of India (NNFI):** Srinivas Murki, and Rajendra Prasad Anne, *Hyderabad, Telangana.*

**Indian Radiological and Imaging Association (IRIA):** Deepak Patkar, *Mumbai, Maharashtra*; Nidhi Bhatnagar, *Delhi.*

**Indian Federation for Ultrasound in Medicine and Biology (IFUMB):** Alka Karnik and Ashwin Lawande, *Mumbai, Maharashtra.*

**Federation of Obstetric and Gynaecological Societies of India (FOGSI):** Uday Thanawala, *Navi Mumbai, Maharashtra.*

**Indian Orthopaedic Association (IOA):** Ajai Singh, *Lucknow, Uttar Pradesh.*

**International Advisors:** Kishore Mulpuri, *Emily Schaeffer and Jacqueline Li, Vancouver, Canada.*