

An Atypical Case of Parotid Gland Swelling and Arthritis in a Child

CHANDRIKA AZAD, ADHI ARYA, VIDUSHI MAHAJAN AND *SHILPA GOYAL

From the Departments of Pediatrics and *Pathology, Govt. Medical College and Hospital, Chandigarh, India.

Correspondence to: Dr Chandrika Azad, Assistant Professor, Department of Pediatrics, Govt. Medical College and Hospital, Sector 32, Chandigarh 160 030, India. chandrika_azad@yahoo.co.in
Received: February 18, 2014;
Initial review: April 09, 2014;
Accepted: May 30, 2014.

Background: Early onset sarcoidosis is a rarely reported disease in children. **Case characteristics:** 2½-year-old girl with chronic enlargement of bilateral parotid glands and polyarthritis. **Observation:** Biopsy of salivary gland revealed non-caseating granuloma. **Outcome:** Polyarthritis and salivary gland swelling resolved completely after starting oral corticosteroids. **Message:** Sarcoidosis is an important differential diagnosis in young children with joint and salivary gland involvement.

Keywords: Arthritis, Parotitis, Sarcoidosis.

Sarcoidosis in pediatric age group is rare with an incidence of 0.22-0.27 per 100,000 children per year; incidence is 0.06 in children ≤4 years of age and increases gradually to 1.02 in children aged 14-15 years [1]. Only few cases have been reported from India [2]. It can be difficult to diagnose because of its rarity and similarity to other common disorders like tuberculosis and juvenile idiopathic arthritis (JIA). We hereby report a young child with arthritis and salivary gland involvement.

CASE REPORT

A 2½-year-old girl, resident of Hilly area of Northern India, presented with joint swellings for two years, and swelling in pre-auricular area and fever for two months. The joint swellings were painless (painful only during winter season) and boggy, involving ankles, knees and wrist joints, with some relief on oral medications but it never resolved completely. There was no history of rash, cough, dryness of mouth or eyes, weight loss, convulsions, or previous hospital admissions. Family history was non-contributory; there was no history of tuberculosis. On examination, child had stable vitals, with weight <3rd percentile and height between 3rd and 15th percentile. There was generalized non-tender and non-matted lymphadenopathy along with mild pallor. Submandibular and parotid glands were enlarged (**Fig. 1**), non-tender and soft to firm in consistency. There was no icterus, cyanosis, edema or clubbing. Soft, fluctuant and non-tender swelling was present bilaterally above knees, ankles and wrist joints. There was no corneal or conjunctival dryness or uveitis. Systemic examination was non-contributory. Provisional diagnosis of systemic onset JIA was kept.

Hematological workup was normal except microcytic, hypochromic anemia and raised erythrocyte sedimentation rate. Serum electrolytes and renal function tests were within normal limits. Serum Angiotensin Converting Enzyme (SACE) was 190 U/L (Normal 8-52 IU/L) and Urinary calcium was normal (0.12 g/L). Serum immunoglobulins, calcium, phosphorus, alkaline phosphatase and uric acid were within normal limits. Antinuclear Antibody, RA factor and Antistreptolysin-O titers were not raised. C-reactive protein was increased. HIV and tubercular workup were negative. Ultrasonography (USG) of knee joint showed suppurative fluid collection over both patellar bursae. X-ray of the joints did not show any erosion. USG abdomen showed increased renal echogenicity and minimal bowel fluid. Fine needle aspiration cytology (FNAC) of knee joint showed synovial hyperplasia, and FNAC of right parotid and left submandibular area showed non-caseating granuloma. Biopsy from the submandibular gland also showed non-caseating granulomas with no acid-fast bacilli. Final diagnosis of sarcoidosis was made and the child was started on prednisolone (2mg/kg/day). Within two weeks, submandibular and parotid swelling subsided completely.

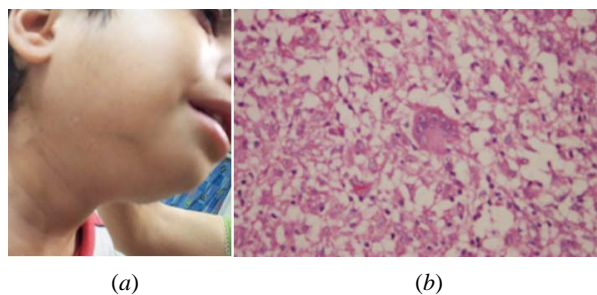


Fig. 1 (a) Enlarged parotid and submandibular salivary glands; (b) Histology from submandibular gland showing non-caseating granuloma with langhans giant cell.

In next two weeks, her joint swelling also subsided. Steroids were given on alternate days after four weeks, and then gradually tapered to 0.5 mg/kg/d every alternate day. She is completely asymptomatic after one year of follow-up.

DISCUSSION

Sarcoidosis is a rare multisystem disorder, affecting most of the organ systems. In younger children, diagnosis is often challenging as presentation is very different from that seen in older children and adults [1]. Young children (<5 years of age) present with classical triad of rash, polyarthritis and uveitis [3]; our patient did not present with this triad. Arthritis of sarcoidosis is characterized by painless boggy effusions of synovium without limitation of motion [4], as seen in our patient. The seasonal variation of arthritis, as seen in our child, has been reported earlier [5].

A close differential diagnosis in the index case was Blau syndrome, which classically presents as granulomatous dermatitis, arthritis and uveitis; salivary gland involvement may also occur. Although clinical features in our patient were suggestive of Blau syndrome, there was no family history of similar illness and no joint erosion on X-ray as seen in blau syndrome [6]. Some authors consider Blau syndrome and early onset sarcoidosis to be familial and sporadic forms of the same disease [7,8]. We could not get mutation analysis for CARD15/NOD2. Another important differential was systemic-onset JIA but non-erosive boggy arthritis favoured sarcoidosis. Granulomatous salivary gland involvement – as seen in our patient – can be found in a variety of disorders, including infections, autoimmune disorders and sarcoidosis [9]. In sarcoidosis, parotid involvement is seen in 6% of adult cases and is commoner in females [10]. In a case series from India, one out of 12 patients had parotid involvement, and eight patients presented with arthritis [2].

There is no gold standard diagnostic test for sarcoidosis. Although SACE can be increased in more than half of children with late-onset sarcoidosis, it is not

specific for sarcoidosis. Usually the diagnosis is made by demonstrating a typical non-caseating epithelioid cell granuloma on a biopsy specimen that can also be seen in tuberculosis, leprosy, Sjogren syndrome, Behcet disease and berylliosis [1,3].

Prognosis in sarcoidosis of early onset is guarded; there is likelihood of chronic progressive course and sequelae in large proportion of patients [3]. We conclude that possibility of sarcoidosis should always be kept in any child presenting with chronic arthritis or salivary gland involvement.

REFERENCES

- Hoffmann AL, Milman N, Byg KE. Childhood sarcoidosis in Denmark 1979-1994: Incidence, clinical features and laboratory results at presentation in 48 children. *Acta Paediatr.* 2004;93:30-6.
- Gupta SK. Pediatric sarcoidosis in India. *Indian J Pediatr.* 2001;68:931-5.
- Häfner R, Vogel P. Sarcoidosis of early onset: A challenge for the pediatric rheumatologist. *Clin Exp Rheumatol.* 1993;11: 685-91.
- Rosenberg AM, Yee EH, MacKenzie JW. Arthritis in childhood sarcoidosis. *J Rheumatol.* 1983;10:987-90.
- Glennas A, Kvien TK, Melby K, Refvem OK, Andrup O, Karstensen B, *et al.* Acute sarcoid arthritis: Occurrence, seasonal onset, clinical features and outcome. *Br J Rheumatol.* 1995;34:45-50.
- Sfriso P, Caso F, Tognon S, Galozzi P, Gava A, Punzi L. Blau syndrome: clinical and genetic aspects. *Autoimmunity Reviews.* 2012;12:44-51.
- Kanazawa N, Okafuji I, Kambe N, Nishikomori R, Nakata-Hizume M, Nagai S, *et al.* Early-onset sarcoidosis and CARD15 mutations with constitutive nuclear factor-kappa B activation: common genetic etiology with Blau syndrome. *Blood.* 2005;105:1195-7.
- Rose CD, Doyle TM, McIlvain-Simpson G, Coffman JE, Rosenbaum JT, Davey MP, *et al.* Blau syndrome mutation of CARD15/NOD2 in sporadic early onset granulomatous arthritis. *J Rheumatol.* 2005;32:373-5.
- Vanhauwaert BG, Roskams TA, Vanneste SB, Knockaert DC. Salivary gland involvement as initial presentation of Wegener's disease. *Postgrad Med J.* 1993; 69, 643-5.
- James DG, Sharma OP. Parotid gland sarcoidosis. *Sarcoidosis Vasc Diffuse Lung Dis.* 2000;17:27-32.