

Danger of Contrast Enhanced CT Scan

A ten-year-old male child was admitted with attacks of fall, myoclonic jerks and progressive physical and mental deterioration for the last one year. On examination, the vital functions were normal. He was conscious but demented. Speech was infrequent and intelligible. Frequent myoclonic jerks involving mostly the extremities and trunk were noted. There was no obvious focal deficit. Fundus was normal. Other systems did not show any abnormality. Clinically SSPE was suspected. Routine examinations of blood, stool, urine and CSF were normal. Samples of blood and CSF were sent for measles antibody titres, and the child was awaiting EEG. At that point a CT scan was planned. Conray 280, which contains meglumine iothelamate, was used for the contrast study. Following the CT scan the child went into deep coma. Soon he developed hypotension, shock and oliguria. Then he developed ventricular tachycardia and died about 48 hours after the scan. The CT scan report, however, turned out to be normal. We feel that the rapid deterioration and death in this child was due to the side effects of the contrast media.

Haslam *et al.*(1) reported rapid deterioration and also death following contrast enhanced CT in 4 brain tumor cases. They have attributed this to neurologic complications of meglumine which has been shown to produce seizures and neuronal

depression in animal experiments. The present case probably died because of neurologic as well as circulatory complications. The iodinated contrast agents are known to cause a variety of adverse effects which include anaphylaxis, hypersensitivity reactions, hypotension, circulatory failure, cardiac arrhythmia, cardiac arrest, convulsion and renal failure(2). It thus appears that contrast enhanced CT is not as safe as the plain CT. It may probably be omitted where no additional information is going to be obtained from it, as also suggested by Haslam *et al.*(1).

B. Talukdar,
B. Rath,
R. Talwar,

Department of Pediatrics,
Maulana Azad Medical College,
New Delhi 110 002.

REFERENCES

1. Haslam RHA, Cochrane DD, Amundson GM, Johns RD. Neurologic complications of contrast computed tomography in children. *J Pediatr* 1987, 111: 837-840.
2. Reynolds JEF. *Martindale-The Extra Pharmacopoeia*, 28th edn. London, The Pharmaceutical press, 1982, pp 434-445.

Ileocecal Lymphoma Presenting as an Epigastric Mass

Intestinal lymphomas are relatively rare and the third common small bowel tumors(1). Anomalies of midgut rotation account for about 1% of all intestinal

obstructions seen in children and incidence of a symptomatic malrotated gut is very low(2,3). We report here a case of ileocecal lymphoma in a malrotated gut of a young child presenting as an epigastric mass and masquerading as a pancreatic tumor clinically and radiologically.

A boy aged 4½ years, was admitted with the complaints of abdominal pain and mass of 2 months duration. The pain was colicky and mass was gradually increasing in size. He had associated weight loss, mild fever and anorexia. He weighed 11.8 kg. He had severe pallor and tachycardia. There was a firm to hard, irregular, nodular, mobile and inverted horse-shoe shaped mass in the epigastric region extending to neighboring areas. It was non tender and measured 15×12×8 cm in size. There was minimal ascites. The physical examination was otherwise noncontributory.

Routine laboratory investigations revealed a hemoglobin of 6 g/dl and ESR of

40 mm in first hour. The chest X-ray was normal. Abdominal X-ray and IVP showed a soft tissue mass with pressure effect on right kidney and displacement of bowel gas (Fig. 1A). Barium meal study showed widening of the C-loop of duodenum and soft tissue mass occupying the concavity of the loop (Fig. 1B). Ascitic fluid examination showed protein of 3.4 g/dl with cells 12,000/cumm and marked increase in mononuclear cells with atypical blast type of large cells. Peripheral smear confirmed hypochromic normocytic anemia without any evidence of leukemia. Bone marrow examination showed hyperplastic marrow with lymphoblastic (35%) proliferation.

Preoperatively he was prepared with blood transfusions, multivitamins, high protein diet and bowel preparations. At exploration via supraumbilical transverse incision, he was found to have midgut malrotation and an ileocecal mass with minimal ascites and no liver involvement. Ileo-

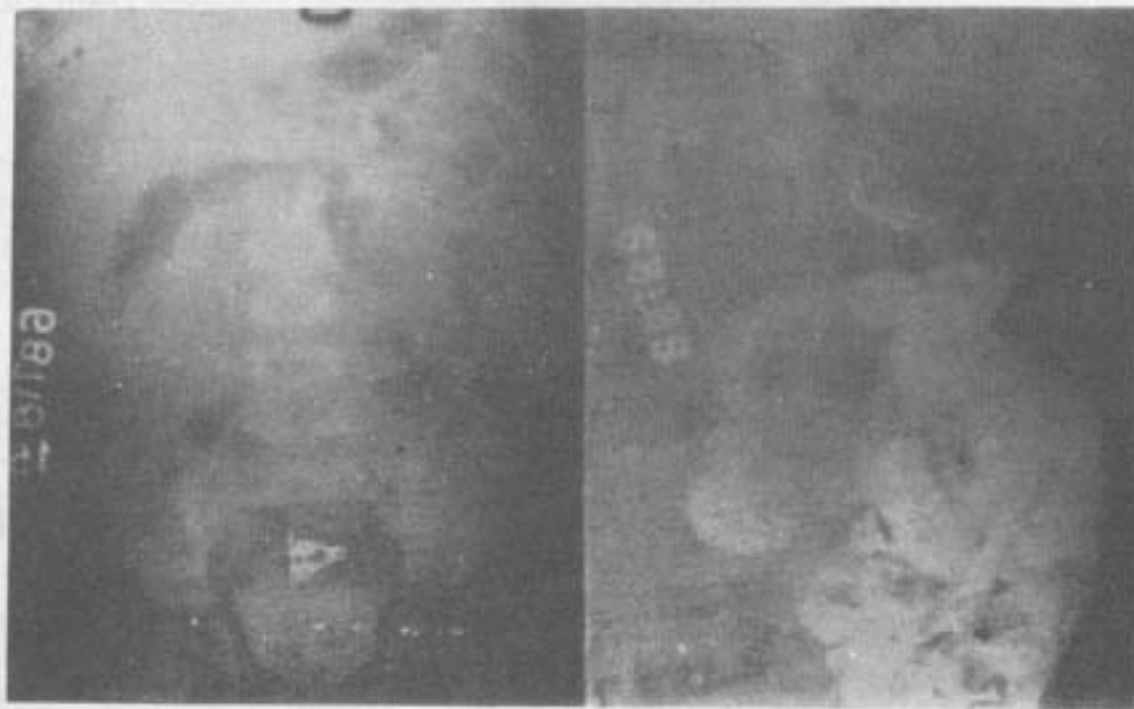


Fig. 1A & B. IVP film and barium meal showing soft tissue mass displacing right kidney downwards and undue widening of C-loop of the duodenum.

cecal area was situated in the epigastrium just below the pylorus with Ladd's bands stretching from it across the second part of duodenum to the gall bladder region. It was classic type of malrotation with duodenojejunal flexure to the right of lumbar spine.

Extended right hemicolectomy followed by ileotransverse anastomosis were carried out. Post operative period was uneventful. He was put on regular cyclic combination chemotherapy following histopathologic confirmation of non Hodgkin's lymphoma. Vincristine, cyclophosphamide and prednisolone in recommended doses were given according to COP regime. He received radiotherapy after 2 cycles of chemotherapy and cyclical combination chemotherapy was continued soon after the completion of radiotherapy. After a period of 6 months, patient had local recurrence with hepatosplenomegaly, ascites and leukemic conversion. Intensive chemotherapy was instituted but the patient succumbed within two months.

In the usual type of malrotation, C-loop of duodenum is widened and the ileocecal region is in the epigastric area with the Ladd's bands stretching across the second part of the duodenum. Any mass, therefore, in the ileocecal region of such a malrotated gut would simulate a pancreatic lesion clinically and radiologically. In the evaluation of an abdominal mass in a child with a high index of suspicion of congenital anomalies of gut rotation, combined upper gastrointestinal barium study and barium enema may help to establish the diagnosis of malrotation and ileocecal site of the lesion.

Ileocecal lymphomas in children may present as intraluminal polypoid masses causing early intestinal obstruction(4). In a

malrotated gut, the ileocecal region is placed very close to celiac axis and spread to adjacent lymph nodes appears to be very early. The prognosis of polypoidal lesion causing early intestinal obstruction is far better as compared to ileocecal mass lesion. Radical right hemicolectomy should *immediately* be followed by radiotherapy to destroy residual deposits and *thereafter* chemotherapy should be given in that order of preference for obtaining maximum benefits(4).

R.V. Patel,
M.H. Mehta,
N.H. Bhoot,
J.S. Gondalia,
J.K. Ghodadra,
Department of Surgery,
M.P. Shah Medical College and
Irwin Group of Hospitals, Jamnagar, and
K.T. Children Government Hospital,
Rajkot 361 001.

REFERENCES

1. Hawley PR, Morson BC. Tumors of the small intestine. *In: Abdominal Operations, Vol 2, 7th edn, Ed Maingot R.* New York, Appleton-Century-Crofts, 1980, pp 1962-1979.
2. Jain VK, Verma BK. Midgut malrotation in an adult presenting as an acute intestinal obstruction. *Indian J Surg* 1989, 51: 47-51.
3. Rao PLNG, Katariya RN, Rao PG, Sood S. Malrotation of midgut causing intestinal obstruction in adults. *J Assoc Phys India* 1977, 25: 493-497.
4. Yadav K, Patel RV, Mitra SK, Malik AK. Chronic secondary cecocolic intussusception in a boy in association with primary malignant lymphoma of the cecum. *J Postgrad Med* 1986, 32: 94-96.