

ROLE OF ULTRASOUND GUIDED PERCUTANEOUS ANTEGRADE PYELOGRAPHY (USPCAP) IN THE DIAGNOSIS OF OBSTRUCTIVE UROPATHY

M. Rohatgi
M. Bajpai
D.K. Gupta
A.K. Gupta

ABSTRACT

Ultrasound guided percutaneous antegrade pyelography (USPCAP) was performed in 6 cases between 1 month and 8 years age, presenting with obstructive uropathy. The procedure in this age group was characterized by (i) ease of performance without sedation in the neonates and with sedation in older children, and (ii) use of smaller needles and catheters. The procedure enabled delineation of the intimate anatomy of complicated urological abnormalities such as obstructed duplex system, primary megaureters, posterior urethral valves, prune belly syndrome, obstructive hydronephrosis and vesicoureteric reflux.

Percutaneous renal puncture may be established rapidly using ultrasonic guidance in severely ill pediatric patients with obstructive uropathy. B-mode ultrasonography has proved to be rapid, accurate and free of radiation hazards, making it applicable to children with little or no sedation. Guided by ultrasound, percutaneous antegrade pyelography should be considered in the few, selected children with obstructive uropathy when the diagnosis is critical for management and difficult with the usual imaging procedures.

Key words: Ultrasound guided percutaneous antegrade pyelography, Obstructive uropathy.

Although percutaneous studies of the upper urinary tract are widely performed in adults, reports of their particular features in children have been few(1-7). The exact location and the depth of the dilated renal pelvis can be determined accurately with the use of ultrasound. Percutaneous antegrade pyelography (PCAP) provides significant diagnostic information on the nature of the urinary tract anomaly and can be performed in most cases as an alternative to a retrograde pyelogram. The present study reviews our experience with ultrasound guided PCAP-(USPCAP) in the pediatric age group.

Material and Methods

Ultrasound equipment used for this procedure consisted of an ATL MK-600, real time sector scanner with a mechanical type of transducer. The gray scale images were displayed on Philips Diagnost-73 image intensifier. Written consent was obtained, hematocrit and coagulation profile were checked, antibiotics were started and premedication with diazepam and pentazocine were used, when necessary, prior to the procedure. The procedures were performed with the patient in a prone or slightly prone oblique position, with a bolster under the upper abdomen to fix the kidneys against the posterior abdominal wall. An US scan was first performed from

From the Departments of Pediatric Surgery and Radiodiagnosis, All India Institute of Medical Sciences, New Delhi 110 029.

Reprint requests: Dr. M. Bajpai, Assistant Professor, Department of Pediatric Surgery, All India Institute of Medical Sciences, New Delhi 110 029.

Received for publication March 10, 1991;
Accepted November 22, 1991

the back. After cleaning and draping the area along the puncture site, 2% xylocaine solution was injected along the approximate path of the needle upto the renal capsule. A 20 cm 22 gauge skinny needle was introduced in the pelvicalyceal system under continuous ultrasonographic monitoring and water soluble contrast medium was injected. Care was taken to inject a volume of contrast less than the volume of aspirated urine to prevent extravasation. Radiographs were then obtained in anteroposterior, posteroanterior, both obliques, lateral and erect projections. Delayed films were obtained when indicated.

Results

Six patients with obstructive uropathy underwent USPCAP between 1986 and 1989. Average age at presentation was 6.2 years, with a range of 1 month to 8 years. These patients were referred to us after preliminary investigations such as biochemical evaluation, ultrasonography (US) and intravenous pyelography (IVP) and in some cases after an initial operative intervention (*Cases 1 and 2*). Biochemical parameters and US were repeated in all cases after admission.

Case 1: A one month-old-girl had undergone bilateral ureterostomies for suspected megaureters. She was referred because of retraction and nonfunctioning of left ureterostomy, a serum creatinine of 1.8 mg/dl and non-visualization of kidneys on IVP. Ultrasonography confirmed the diagnosis of hydronephrosis. Isotopic renogram was noncontributory because of poorly functioning kidneys. Micturating cystourethrogram (MCU) revealed right sided grade 3 vesicoureteric reflux (VCR). In the first attempt at USPCAP, a pelvicalyceal

system was visualized draining into a single ureter which was obstructed at ureterovesical junction (*Fig. 1*). Since the ureter which was brought out as ureterostomy was not visualized, percutaneous study was attempted at a higher level and the upper moiety was then visualized. During surgery the upper moiety ureterostomy was revised and a fresh ureterostomy performed on the lower moiety ureter. Despite this, functional recovery could not be achieved and a left nephroureterectomy had to be done after 3 months. The right ureterostomy was closed one year after the MCU showed cessation of reflux.

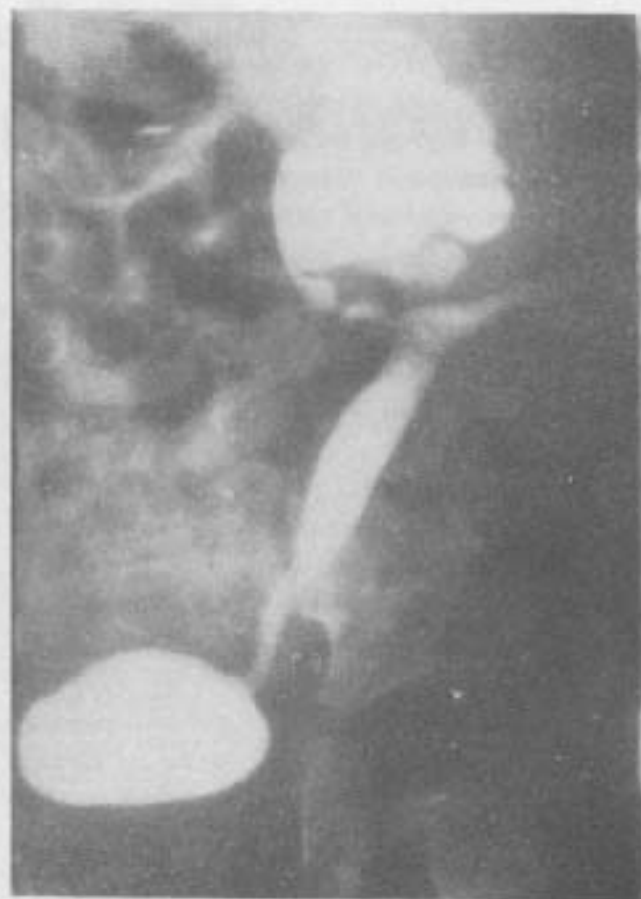


Fig. 1. USPCAP showing hydroureteronephrosis in left duplex system. Ureterostomy seen in upper moiety ureter and obstructed vesicoureteric junction of lower moiety ureter.

Case 2: A two-year-old boy had undergone a left sided pyeloplasty and ureteric reimplantation, both done at the same time for obstruction at pelviureteric and vesicoureteric junctions. He was referred because of nonvisualization of left kidney on IVP six months later. Isotopic renogram also showed negligible function in the left kidney. MCU was normal. USPCAP (Fig. 2) revealed mild obstruction at the ureteropelvic junction and severe obstruction at the ureterovesical junction. After a short interval of drainage by a percutaneous catheter the pyeloplasty was revised and the lower end of ureter brought out as end ureterostomy. Neoureterostomy was deferred for six months. Subsequent functional recovery was satisfactory.

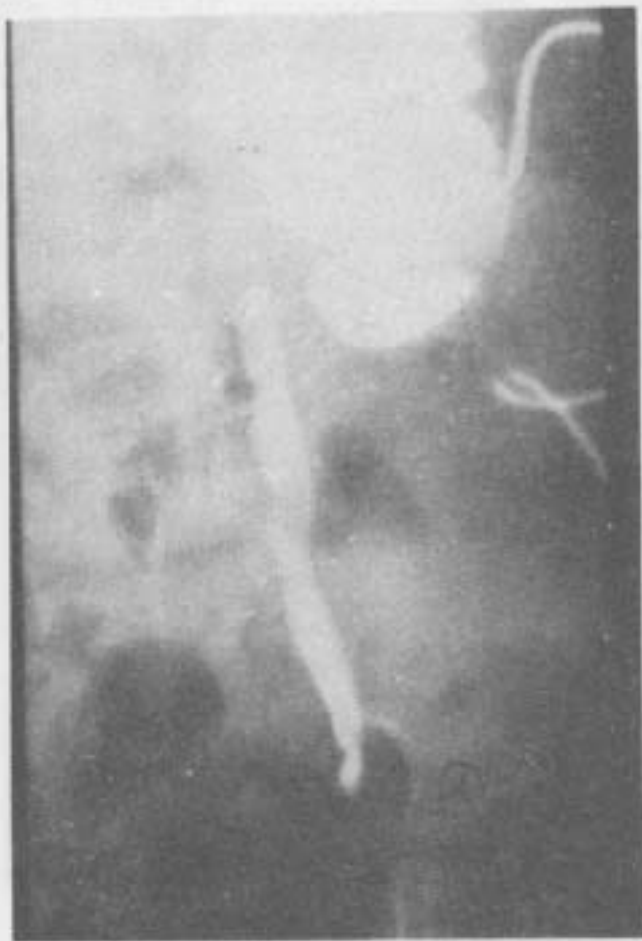

Fig. 2. USPCAP showing obstruction at both pelviureteric and ureterovesical junction.

Case 3: An eight-year-old boy presented with hypertension and renal failure with a serum creatinine of 4.8 mg/dl and nonvisualization of kidneys in IVP. US showed bilateral hydronephrosis. Isotopic renogram was noncontributory due to poor renal function. MCU showed left sided Grade 3 reflux and delayed ureteric clearance. USPCAP (Fig. 3) revealed bilateral ureterovesical junction obstruction. Bilateral high ureterostomies were performed. Isotopic renal studies showed return of function.

Case 4: A ten-month-old boy presented with a history of failure to thrive and recurrent urinary tract infection. His serum creatinine was 4.0 mg/dl and the IVP

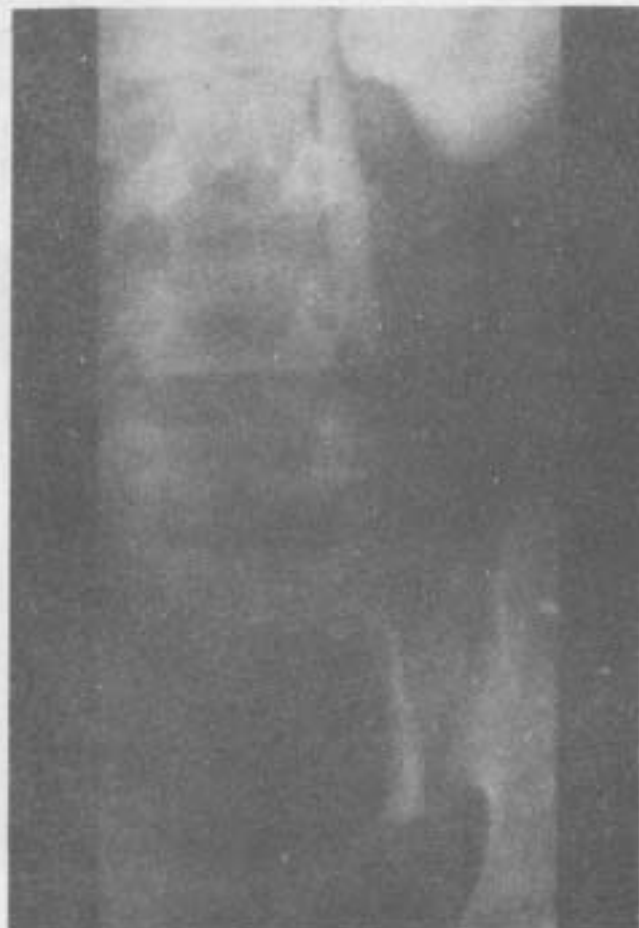

Fig. 3. USPCAP (6 hour film) showing obstruction at left ureterovesical junction.

showed bilateral nonfunctioning kidneys. US showed dilated cystic fluid filled spaces occupying both the renal areas and most of the mid and lower abdominal cavity. MCU showed a large bladder. Contrast enhanced CT scan confirmed these findings (Fig. 4). Though the cystic spaces were thought to be dilated ureters, it was not clear as to which kidney the ureter/ureters belonged to. USPCAP (Fig. 5) revealed bilateral hydronephrosis with massively dilated, non-obstructed and aperistaltic ureters. The child developed mild hematuria after the procedure, which subsided spontaneously after a few hours. Since he also had bilateral cryptorchidism but a normally appearing abdominal wall a diagnosis of type 3 prune-belly syndrome was made present-

ing with incomplete features. At surgery reduction cystoplasty, tapering of 1/3 of both ureters and bilateral ureteric reimplantations were done. The serum creatinine fell to 0.6 mg/dl within 3 months and isotopic renal studies revealed return of function.

Case 5: A two-month-old boy presented with renal failure, a serum creatinine of 3.6 mg/dl and nonfunctioning kidneys in IVP. US revealed a solitary right kidney with hydroureteronephrosis and abnormally elongated calyces. Isotopic renogram was noncontributory. MCU showed Grade 4 VUR, trabeculated bladder and type 1 posterior urethral valves. In view of the unusual shape of the solitary kidney, USPCAP (Fig. 6) was done to show the

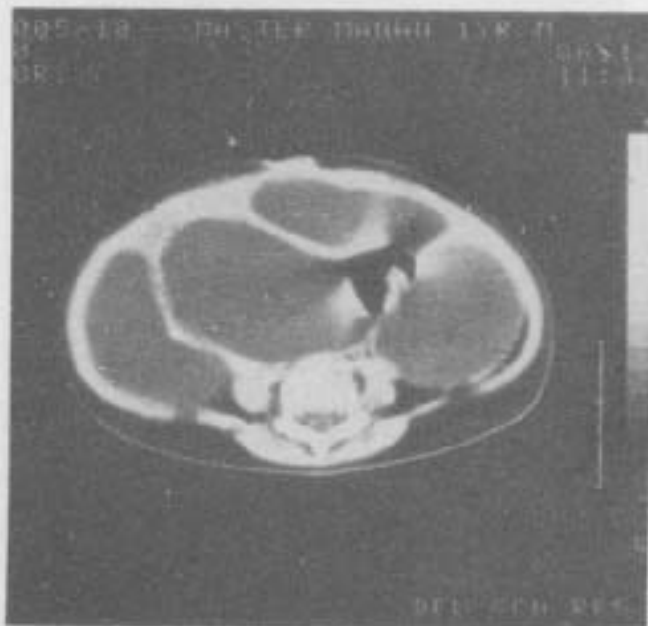


Fig. 4. Contrast enhanced CT scan showed large fluid filled spaces representing dilated ureters in prune belly syndrome.

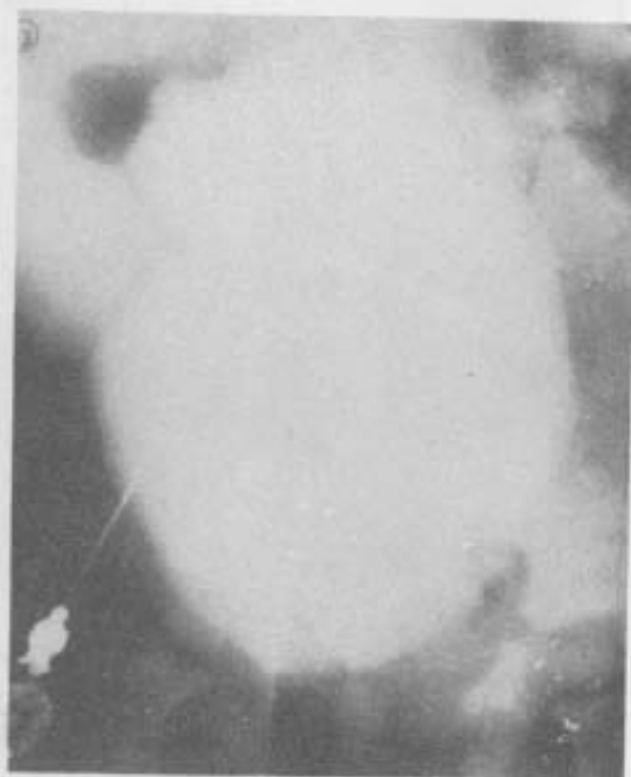

Fig. 5. USPCAP showing massive right hydroureteronephrosis and megacystis.

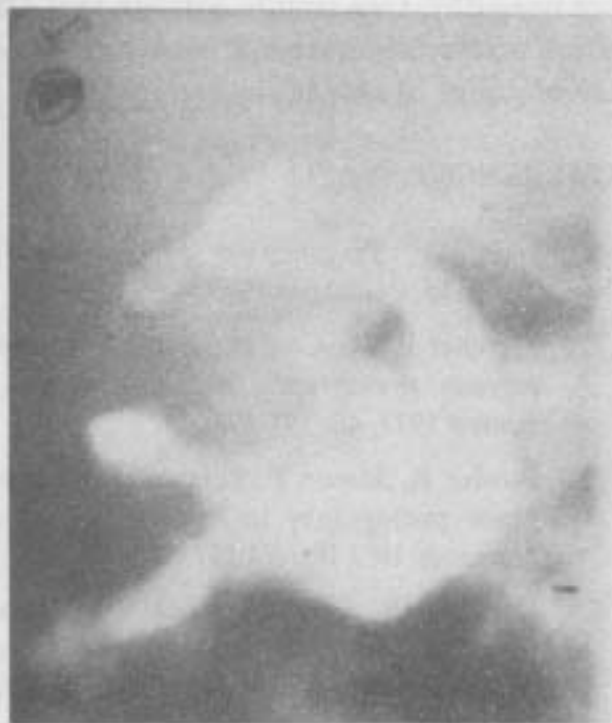

Fig. 6. USPCAP showing abnormally rotated solitary right kidney with hydronephrosis.

exact nature of the anatomical abnormality. The study revealed medial rotation abnormality of the kidney with obstruction at the ureterovesical junction. He underwent a high ureterostomy and is awaiting definitive surgery.

Case 6: An eight-year-old boy presented with high grade fever, pyuria, a serum creatinine of 6 mg/dl and nonfunctioning kidneys on IVP. US showed bilateral hydronephrosis, the isotopic renogram was noncontributory and MCU was normal. USPCAP revealed bilateral hydronephrosis with obstruction at both vesicoureteric junctions. Under ultrasound guidance percutaneous catheters were inserted to drain the infected urine. After 3 weeks both kidneys were explored. The right kidney had papery thin cortex and a nephroureterectomy was carried out. On the left side the kidney had good cortex

and a high ureterostomy was done. Subsequent functional recovery was remarkable.

Discussion

Various diagnostic modalities are available for investigating the obstructed urinary tract. US, IVP, CT scan and isotopic renal studies are usually sufficient to define the nature of pathology but have their own limitations. Whereas the usefulness of IVP, CT scan and isotopic renal studies becomes restricted when renal function is poor, ultrasonography does not show function at all. In certain cases with possible obstruction and reduced renal function when the pathological anatomy is inadequately defined, antegrade or retrograde pyeloureterography is indicated(8). Retrograde study through cystoscopic ureteric catheterization carries an increased risk of introduction of bacteria, may produce edema of ureteric orifices, may be difficult to perform in the male infant (Cases 2, 4, & 5) and utilizes general anaesthesia(8,9). On the other hand antegrade pyelography is characterized by ease of performance, without sedation in the neonate and with sedation in children, and by the use of smaller needles and catheters(7). Percutaneous renal puncture may be established rapidly using ultrasonic guidance in severely ill pediatric patients with obstructive uropathy. Antegrade pyelography has several diagnostic and therapeutic indications(8) (Table I). Ultrasound guided percutaneous drainage was also instituted in 2 cases (Cases 2 & 3) to allow the infection to subside before surgical exploration. In our study of 6 patients important information leading to a more definite diagnosis was achieved only after USPCAP. The majority of childhood disorders constitute congenital obstructions of

TABLE I—Indications for Antegrade Pyelography**A. Diagnostic**

1. Confirmation and evaluation of hydronephrosis
2. Determination of resting pressure
3. Urinalysis: Cytologic study, culture and biochemical analysis
4. Site and etiology of obstruction
5. Ureteral fistula, leak
6. Ureteral diversion

B. Therapeutic

1. Drainage
2. Dilatation of stenosis
3. Stenting
4. Balloon occlusion
5. Stone removal
6. Biopsy

ureteropelvic junction (*Case 2*) and ureterovesical junction (*Cases 2, 3 & 6*), duplex system (*Case 1*), vesicoureteric reflux (*Cases 1, 3 & 5*) and hydronephrosis associated with posterior urethral valves (*Case 5*) and prune belly syndrome (*Case 4*). In advanced stage of the disease the final diagnosis is determined only after PCAP(1,10-13). Potential complications of USPCAP include hematuria, temporary obstruction due to clots, subcapsular or perinephric hemorrhage, infection, local pain and entry into adjacent non renal structures(9). Although the possible complications of the procedure appear formidable, the actual complications, other than transient hematuria (*Case 4*) are unusual. The incidence of significant complications or those requiring treatment or prolonged hospitalization should be 1% or less(13,14).

In conclusion, PCAP is a valuable adjunct to the diagnostic studies of obstructive uropathy. Our results indicate that US offers a safe, accurate and easy aid in the performance of antegrade pyelography.

REFERENCES

1. Lalli AF. Translumbar pyelography in the child. *Pediatrics* 1969, 44: 1016-1018.
2. Fletcher EWL, Chir B, Gough MH. Antegrade pyelography in children. *Br J Radiol* 1973, 46: 191-194.
3. Fowler R, Jensen F. Percutaneous antegrade pyelography in small infants and neonates. *Br J Radiol* 1975, 48: 987-992.
4. Babcock JR, Kolnik A, Cook WA. Ultrasound guided percutaneous nephrostomy in the pediatric patient. *J Urol* 1979, 121: 327-329.
5. Man DWK, Hendry GMA, Handy MA. Percutaneous nephrostomy in pelviureteric junction obstruction in children. *Br J Urol* 1983, 55: 356-360.
6. Winfield AC, Kirchner SG, Brun ME, Major MJ, Braren HV, Kirchner FK. Percutaneous nephrostomy in neonates, infants and children. *Radiology* 1984, 151: 617-619.
7. Riedy MJ, Lebowitz RL. Percutaneous studies of the upper urinary tract in children with special emphasis on infants. *Radiology* 1986, 160: 231-235.
8. Pfister RC, Papanicolaou N, Youder IC. Diagnostic, morphologic and urodynamic antegrade pyelography. *Radiol Clin North Am* 1986, 24: 561-571.
9. Pfister RC, Newhouse JH. Interventional percutaneous pyeloureteral techniques II. Antegrade pyelography and ureteral perfusion. *Radiol Clin North Am* 1979, 17: 341-350.
10. Amis ES Jr, Cronan JJ, Pfister RC. Lower moiety hydronephrosis in duplicated kidneys. *Urology* 1985, 26: 82-88.
11. Blickman JG, Lebowitz RI. The coexis-

tence of primary megaureter and reflux. *Am J Radiol* 1984, 143: 1053-1057.

12. Crooks KK, Hendren WH, Pfister RC. Giant hydronephrosis in children. *J Pediatr Sury* 1979, 14: 844-850.

13. Mandell VS, Mandell J, Gassie G. Pediatric urologic radiology: Intervention and

endourology. *Urol Clin North Am* 1985, 12: 151-168.

14. Pfister RC, Newhouse JH, Yoder, *et al.* Complications of pediatric percutaneous renal procedures: Incidence and observations. *Urol Clin North Am* 1983, 10: 563-571.

NOTES AND NEWS

RECENT ADVANCES IN PEDIATRICS

The 2nd volume of the series, edited by Dr. Suraj Gupte, has just been released at the inaugural function of the 29th National Conference of the Indian Academy of Pediatrics held at Nagpur from January 9-12, 1992.

Part I deals with 19 original articles from 27 experts drawn from across the world on such topical issues as "Computers in Pediatrics", "ICC 1992", "Child Labor", "Breast Feeding Promotion", "Simplified Developmental Assessment", "Nutritional Anemias", "Nutrition and Developing Brain", "Newer Technologies in Weaning Foods", "Short Stature", "Dental Caries", "Prenatal Diagnosis of Hematologic Disorders", "Posterior Rhizotomy in CP", "ECMO," *etc.*

Part II carries critically-analyzed abstracts of 92 highly selected articles forming cream of the world pediatric literature that appeared recently in journals and periodicals: The commentaries by the Editor invited experts to analyze each article's clinical significance and implications, supply valuable background information, discuss results of related studies and provide suggestions for further work and cross references.

The volume is published by Jaypee Bros, New Delhi, and priced at Rs 150/-.

Limited number of copies of the first volume, priced at Rs 125/- are also available.

Requests for delivery by post must be accompanied by crossed demand draft covering the price plus Rs 15/- as handling and postal charges.

Also available through Dr. Suraj Gupte, MD, FIAP, 60 Lower Gumat, Jammu 180001.