

($p < 0.001$) to differentiate between PM and TBM. The mean CSF IgG percentage in healthy non-meningitic children is $11 \pm 8\%$ while it is raised in PM and TBM (25 ± 11 and $46 \pm 18\%$, respectively). A similar observation has been made by Varani *et al.* (7). Hence, a mean CSF IgG percentage of more than 25% forms a highly useful diagnostic tool to establish and distinguish TBM from PM. This helps to institute an early and proper specific therapy, which would lead to a better prognosis of the case and reduce the overall morbidity and mortality.

REFERENCES

1. Chandra RK, Ghai OP. Serum immunoglobulins in healthy children from birth to adolescence. *Indian J Med Res* 1972, 60:89-96.
2. Prasad LS, Sinha KP, Sen DK, Mullick H. A study on immunoglobulins in Indian children. *Indian J Med Res* 1971, 59: 107-114.
3. Samuel AM, Deshpande VR, Singh B. Immunoglobulins in normal adult Indians. *Indian J Med Res* 1970, 58: 56-64.
4. Varley H. The plasma proteins. In: *Practical Clinical Biochemistry*, IV edn. Ed Varley H, New Delhi, Arnold Heinemann Publishers, 1976, pp 236-238.
5. Mancini C, Carbonara AO, Herenan JF. Immunochemical quantitation of immunoglobulins by SRID. *Immuno Chem* 1965, 2: 235-254.
6. Gill DG, Brody M. Cerebrospinal fluid immunoglobulins in child. *Arch Dis Child* 1979, 54: 961-967.
7. Varani SF. Immunoglobulins in CSF in central nervous disorders. *Indian J Pediatr* 1982, 49: 665-693.
8. Pole S. Immunoglobulin levels in CSF in meningitis. Dissertation submitted to the University of Bombay, 1981.

Hemoptysis in Tetralogy of Fallot

M. Singh
V. Kohli
S. Singhi

Hemoptysis is a potentially lethal pulmonary complication of congenital cyanotic heart disease seen infrequently in Pediatric practice. It may be caused by rupture of enlarged bronchopulmonary collaterals, underlying hematological disorder or infections like tuberculosis. During last one year, we saw four cases of Tetralogy of Fallot (TOF) presenting with hemoptysis, out of a total of 21 admissions to the Pediatric emergency with various complications of TOF.

Case Reports

Four cases of TOF were admitted to the Pediatric Emergency of PGIMER, Chandigarh in 1989, with the complaint of hemoptysis. All patients were male, between 8-13 years of age (mean 11.2 years). The diagnosis of TOF was made clinically, electrocardiographically and confirmed by echocardiography. The details of all the four patients are given in *Table I*.

Discussion

In the natural history of TOF,

From the Department of Pediatrics, Post-graduate Institute of Medical Education and Research, Chandigarh-160 012.

Reprint requests: Dr. Meenu Singh, 3/8H, PGI Campus, Chandigarh-160 012.

*Received for publication April 23, 1990;
Accepted November 12, 1990*

TABLE I — Clinical Profile and Investigations

Case No.	Age (yrs)	Age at diagnosis (yrs)	Past history	Presenting features	Investigation	Treatment
1.	12	4	Occasional cyanotic spells	Two episodes of massive hemoptysis (200 ml)	Hb 17 g/dl PCV 55%, PT/PTT/PTTK-N. X-ray chest: Prominent bronchopulmonary collaterals.	Surgical ligation recommended
2.	9	5	Cyanotic spells Received anti TB therapy 8 months back for fever, cough, pleural effusion and positive Mantoux test	Bilateral crepitations blood streaking of sputum	Hb 17 g/dl, PCV 54% Coagulogram N. X-ray chest: Bilateral parenchymatous lesion (Fig. 1)	Anti tubercular treatment
3.	11	11	Cyanotic spells	Hemoptysis (30 ml), Hematemesis, Polycythemia (76%), Dysmorphic features	Hb 15 g/dl, PT 20/22 sec, PTT 90%, PTTK 58/60 sec. Platelet: 20,000/cu mm X-ray chest: Oligemic lung fields	Fresh blood transfusion, Platelet rich transfusion. Advised corrective surgery
4.	13	8	Head trauma at 8 yrs - Post traumatic hydrophalus: shunted.	Hemoptysis (50 ml), Polycythemia, Recurrent spells	PT 15/22 - 20/22 PTT 68 - 90% PTTK 43/60 - 55/60 platelets 67,000-90,000/cu mm FDP +, PCV 70%, Hb 20 g/dl, X-ray chest: Prominent bronchopulmonary collateral	Partial exchange with plasma. Advised corrective surgery

N.B. Bronchoscopy done in Case No. 1 showed aneurysm of bronchial collaterals and in case No. 3 was normal.

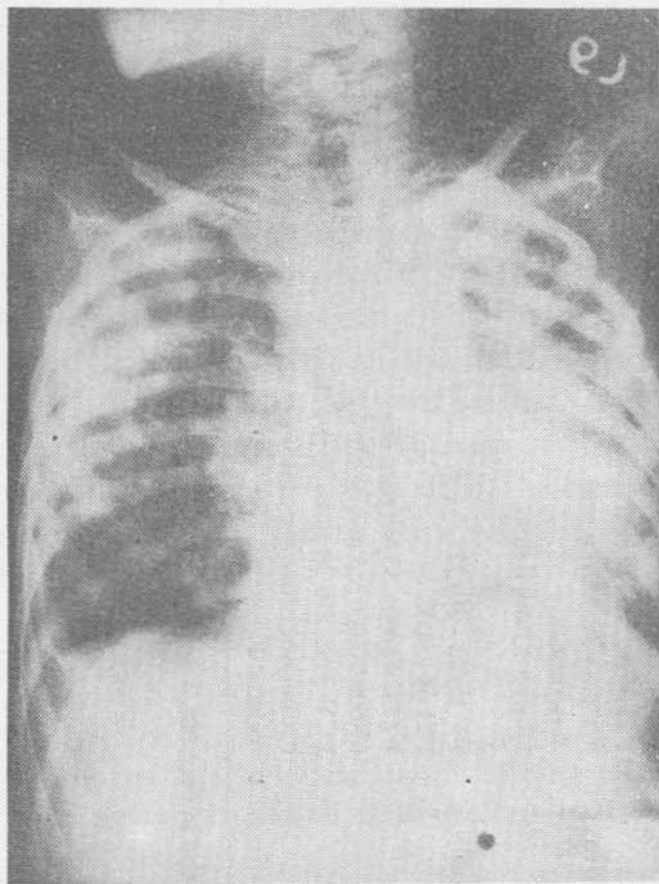


Fig. 1. X-ray chest of patient No. 2 showing bilateral parenchymatous lesions.

hemoptysis occurs as a result of increased collaterals in bronchopulmonary circulation as seen in our first patient. This complication is not seen if early surgical correction of the anomaly is undertaken. Haroutonian and Neill described 13 cases of TOF with hemoptysis, all aged 12 years or more due to this complication(1).

Three major changes have been described in the pulmonary vascular bed in these patients namely – thrombosis of the small pulmonary vessels, increased size and tortuosity of the bronchial arteries and the relative hypoplasia of the pulmonary arterial wall. All these changes may contribute to hemoptysis and may interact. These patients can also develop hemoptysis from angiomatous conversion of right upper lobe. The radiological changes seen in the upper lobes simulate chronic tuberculosis

or histoplasmosis. These are termed pseudofibrosis. Apical pleural capping may also result from localised pleuritis due to pulmonary infarction(1).

The second case was diagnosed to have tuberculosis on the basis of history, positive Mantoux and response to anti-tubercular treatment. Patients with decreased pulmonary flow are believed to have a tendency to develop tuberculosis(2). Tuberculosis being common in our country could have contributed to development of hemoptysis in this child. Hemoptysis occurring as a result of increased bronchopulmonary collaterals mostly occurs in children more than 12 years of age.

Underlying disorders of coagulation have been reported in congenital cyanotic heart disease(3). Isolated thrombocytopenia as seen in one of our cases has been reported earlier(4,5). The platelet count which is normal initially may increase with subsequent decrease due to persistent desaturations(5). Abnormal coagulation factors have been found in patients with PCV greater than 60%. Polycythemia leads to a state of chronic disseminated intravascular coagulation increasing the tendency to bleed. Although chest X-rays showed only oligemia in patients 3 and 4, there could have been undetected changes in the pulmonary vascular bed accompanied by hematological abnormalities to produce hemorrhagic manifestation in these patients.

It must be emphasized that the etiology of hemoptysis in cases with tetralogy of Fallot may be multifactorial hence the basic diagnostic work up should include all the investigations with priority given to the most likely possibility.

REFERENCES

1. Haroutonian LM, Neill CA. Pulmonary

- complication of congenital heart disease: Hemoptysis. *Am Heart J* 1972, 84: 540-559.
2. Somerville J Congenital heart disease in adults. In: *Oxford Textbook of Medicine*, 2nd edn. Weatherall DJ, Ledingham JG, Warrell DA Oxford University Press, 1987, pp 13-249.
 3. Henriksson P, Varend LG, Lundstrom NR. Hemostatic defects in cyanotic congenital heart disease. *Br Heart J* 1979, 41: 23-27.
 4. Waldman JD, Czapack EE, Paul MH, *et al*. Shortened platelet survival in cyanotic heart disease. *J Pediatr* 1975, 87: 77-79.
 5. Gross S, Keefer V, Liebman J. The Platelets in cyanotic congenital heart disease. *Pediatrics* 1968, 42: 561-568.

Dental Caries in Children

N. Ganga

B. Rajagopal

S. Rajendran

A.S. Padmanabhan

Dental caries (DC) is the most common dental problem in children. It begins even before the first year of life(1). By 5 years, 15% of all children have had dental caries. After eruption of permanent teeth, 20% had caries(2). Pediatricians and primary care physicians can prevent dental problems because they see and observe the child earlier.

From the Department of Pediatrics, Thanjavur Medical College, Thanjavur-613 004.

Reprint requests: Dr. N. Ganga, W/o Dr. A. Subramanian, Sacred Heart Leprosy Centre, Sakkottai-612 401, Kumbakonam, Tamil Nadu.

Received for publication January 10, 1987;

Accepted December 17, 1990

The World Health Organization had defined DC as a 'Localised post eruptive pathological process of external origin, involving softening of the hard tooth tissue and proceeding, to the formation of a cavity'(3). No baseline data is available for India in the WHO Global Oral Data Bank(4).

Material and Methods

Five hundred children, selected at random, from the out-patient department were studied. The dental status of children was assessed which included dental hygiene, number of decayed, missing or filled teeth and presence of cavity. History of dietary habits, methods of teeth cleaning, mouth rinsing after food, parents and/or sibling history of dental problems was obtained. Oral hygiene advice was given to the children and parents.

Results

Of 500 children, 287 (57.4%) were male and 213 (42.8%) female. Of these, 161 (32.2%) had dental caries. The prevalence was more in children between 4-12 years of age. The site of caries is shown in *Table I*. Among 161 children with caries, 122 (75.3%) had cavity. Of 500 children, 182 (36.4%) had one or more missing teeth, of which 39 had the tooth extracted for DC and in others, it was physiological tooth loss. Nine (1.8%) had filled teeth. Rampant caries or nursing bottle caries were not seen in any child. History revealed that 67 (41.8%) had dental abscess and 102 (63.3%) had one or more attacks of toothache.

For teeth cleaning, 174 children (34.8%) used sand or ash, 289 (57.8%) tooth powder, 37 (7.4%) tooth brush with