
BRIEF REPORTS

Tuberculosis of Petrous Apex

S. Kumar

V. Puri

R. Malik

S. Gupta

Even though tuberculosis is still rampant in our country, tubercular osteomyelitis of the skull bone is uncommon especially of the base. Recently, we came across a case of tubercular granulation tissue originating from petrous portion of the temporal bone mimicking as a trigeminal tumour and because of its rarity, this case is being reported.

Case Report

A 13-year-old female child was admitted with complaints of generalised tonic and clonic seizures. She had three such episodes during the last three years. She had been having generalised headache and low grade fever for the last 5 months. She complained of diplopia on looking towards the right side and had been aware of deviation of right eye for the last 4 months.

On examination, she was afebrile. Higher mental functions were normal. There was bilateral papilledema, paralysis

of right 5th and 6th cranial nerves and diminished sensations on right side of the face. There was no motor or sensory deficit in the limbs or any cerebellar signs.

Hemogram and urinalysis were normal. ESR was 12 mm in first hour. Plain X-ray skull including periorbital view for the petrous and chest were normal. Contrast CT scan showed high attenuating lesion in the right medial temporal region near the petrous bone (*Fig.*). CT cuts for petrous bone were normal.

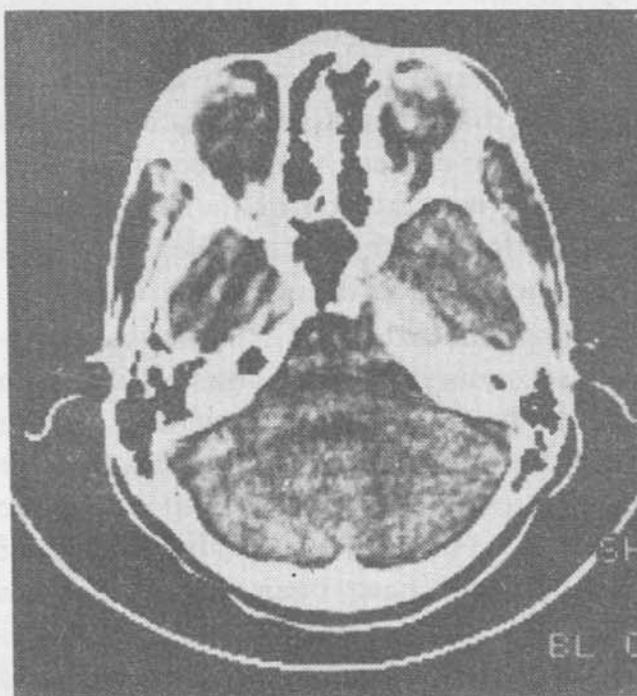


Fig. Contrast CT scan showing a high attenuating mass in the region of medial portion of petrous bone.

Right temporal craniotomy revealed no intradural mass. The duramater was closed and its gentle elevation from the base revealed granulomatous relatively avascular tissue destroying the petrous bone. Granulations were not adherent to duramater and were scooped out.

Histopathology of the tissue revealed granulation tissue with granuloma formation with lymphocytes, plasma cells, epithelioid cells and giant cells.

From the Departments of Neurosurgery, Neurology, Pathology and Radiology, G.B. Pant Hospital, New Delhi-110 002.

Reprint requests: Dr. Sushil Kumar, Professor, Department of Neurosurgery, G.B. Pant Hospital, New Delhi-110 002.

*Received for publication July 27, 1990;
Accepted November 12, 1990*

The patient was put on antitubercular drugs and dilantin. Postoperatively she recovered 5th and 6th nerve functions within 2 months.

Discussion

Despite high incidence of tuberculosis in our country, tuberculosis of skull base is rarely encountered, though cases with involvement of cranial vault are seen occasionally. Strauss(1) reported prevalence rate between 0.2 and 1.4% of tuberculosis of skull, the rate being 0.14 to 0.46% in India(2,3). Rarity of the disease could be due to early diagnosis of systemic tuberculosis and greater efficacy of antitubercular drugs resulting in reduction of the incidence of chronic form of the disease. Nearly 75-80% cases occur under the age of 20 years(1,4).

Involvement of the skull bones is usually secondary to tuberculosis elsewhere in the body. Absence of lymphatics in the skull has been cited as an explanation for the extreme rarity of tuberculosis of the skull(5). Few cases of tuberculosis of cranial vault have been described from India(2,6-10). Gupta *et al.*(11) reported involvement of basal bones (sphenoid and ethmoid) alongwith temporal bone. Involvement of sphenoid has been reported by others(12,13), but we failed to find the case of petrous tuberculosis from the literature. Two forms of the lesion are known: circumscribed or punched out and progressive infiltrating type and both may be present at the same time indicating thereby that both are spectrum of the disease process. When the response to infection is good, the lesion develops slowly. Wide extension of the tuberculous granulation tissue through the diploe is prevented by the proliferation of encircling layer of concentrically placed fibroblasts and if

process of extension is not arrested, extension takes place through either table.

The duramater shows a high degree of resistance to the spread of infection to meninges and brain. According to De Vat(14) the granulations are adherent to the underlying duramater and separation of the two is difficult. According to Strauss(1), granulations are not very adherent to the duramater and they could be separated off easily and similar was our experience.

Because of clinical involvement of 5th and 6th nerves and high density mass in the petrous region, we suspected the lesion to be a trigeminal neurinoma rather than tuberculous granulation. It seems that 5th nerve was directly involved by granulation tissue. However, papilledema could not be explained by such a small mass in the absence of ventricular enlargement. Epileptiform convulsions as seen in our case is a rare complication and has been earlier reported by Tirona(5).

Radiography of skull may show discrete oval or round defect without sclerosis or with sequestrum within the destructive lesion and is referred to as bone sand.

Mainstay of treatment is antitubercular drugs, and surgery is indicated if there is raised intracranial pressure or sequestrum or when the diagnosis is in doubt as was in our case. Result of treatment is generally good as is evident from our case as well.

Acknowledgements

The authors are grateful to Dr. M. Khalilullah, Director, G.B. Pant Hospital, New Delhi for permitting them to publish this case.

REFERENCES

1. Strauss DC. Tuberculosis of the flat bones

of the vault of the skull. *Surg Gynec Obstet* 1933, 57: 384-398.

2. Raja Reddy DR, Rammohan S, Krishnachari A, Satyanarayana K. Tubercular osteomyelitis of skull bones. *Indian J Tuberc* 1974, 21: 213-215.
3. Nagi B, Sodhi JS, Nagi ON. Tuberculosis of flat bones. *Indian J Radiol* 1976, 30: 170-171.
4. Meng CM, Wu YK. Tuberculosis of the flat bones of the vault of skull. *J Bone J Surg* 1942, 24: 341-353.
5. Tirona JP. The roentgenological and pathological aspects of tuberculosis of the skull. *Am J Roentgenol* 1954, 72: 762-768.
6. Grewal DS, Kumar R. Caries cranii. *Indian J Surg* 1969, 31: 414-416.
7. Tata HR. Tuberculous osteomyelitis of the skull. *Indian J Tuberc* 1978, 25: 208-209.
8. Mohanty S, Rao CJ, Mukherjee KC. Tuberculosis of the skull. *Int Surg* 1981, 66: 81-83.
9. Katariya S, Thapa BR, Kumar L, Chand G. Tuberculous osteolytic lesions of the skull mimicking neuroblastoma. *Indian J Pediatr* 1988, 55: 149-152.
10. Gupta RK, Sastri Kolluri VR, Chandmurli BA, Venkataramma NK, Das BS. Calvarial tuberculosis: A report of two cases. *Neurosurgery* 1989, 25: 830-833.
11. Gupta RK, Jena A, Sharma. Sellar abscess associated with tuberculous osteomyelitis of the skull: MR findings. *AJNR* 1989, 10: 448-448.
12. Goldblatt M, Cremin BJ. Osteoarticular tuberculosis: Its presentation in coloured races. *Clin Radiol* 1978, 29: 669-677.
13. Miles J, Hughes B. Tuberculous ostitis of the skull. *Br J Surg* 1970, 57: 673-678.
14. Vet AC De. Caries cranii (Tuberculosis of the flat bones of the vault of the skull). *J Neurosurg* 1949, 6: 269-278.

Immunoglobulin Profile in Tuberculous and Pyogenic Meningitis

D.A. Murthy

K.B. Logani

D.N. Mullick

Cerebrospinal fluid (CSF) and serum immunoglobulins (Ig) have been studied in healthy children by Chandra *et al.* (1) and in disease by others (2,3). Little attention has been paid to the quantitative assessment of various Ig in CSF and serum in meningitis. This study was undertaken to assess the diagnostic and clinical significance of serum and CSF Ig to distinguish between tuberculous and pyogenic meningitis (TBM and PM, respectively).

Materials & Methods

Fifty established cases of meningitis admitted to Kalawati Saran Children's Hospital were studied. Twenty age and sex matched children undergoing elective surgery under spinal anesthesia for unrelated cause served as controls. The cases and controls were divided into 6 groups (I-VI) according to age (*Table I*).

CSF analysis was done in all cases. Total proteins were estimated using tur-

From the Departments of Pathology and Pediatrics, Lady Hardinge Medical College and Kalawati Saran Children's Hospital, New Delhi-110 001.

Reprint requests: Dr. (Mrs.) D. Anuradha Murty, 489, Sector III, R.K. Puram, New Delhi-110 022.

Received for publication December 2, 1988;

Accepted March 1, 1990