

3. Karakukcu M, Patiroglu T, Ozdemir MA, Gunes T, Gumus H, Karakukcu C. Pancytopenia, a rare hematologic manifestation of brucellosis in children. *J Pediatr Hematol Oncol* 2004; 26: 803-806.
4. Varga J, Zivkovic D, Grebeldinger S, Somer D. Acute scrotal pain in children: Ten years' experience. *Urol Int* 2007; 78: 73-77.
5. Memish Z, Mah MW, Mahmoud SA, Shaalan MA, Khan MY. Brucella bacteremia: clinical and laboratory observations in 160 patients. *J Infect* 2000; 40: 59-63.

Incessant Atrial Flutter after Device Closure of Atrial Septal Defect : Successful Radio Frequency Ablation

Bobby John
Oommen K George
George Joseph
Yash Y Lokhandwala*

A four-month-old baby presented with failure to thrive and congestive cardiac failure precipitated by a lower respiratory tract infection. He was found to have a large ostium secundum atrial septal defect measuring 18 mm. This was successfully closed percutaneously by a device (Blockaid). A month after the device deployment the child developed typical atrial flutter. Despite rate control drugs the ventricular rate remained 140/min over the next several months. In view of the incessant atrial flutter with fast ventricular response, the child underwent radiofrequency ablation at the age of 2 years. An isthmus block was created which successfully terminated the tachycardia.

Key words: ASD device, Ablation, Atrial flutter, Atrial setpal defect, Radiofrequency.

Atrial septal defect closure using percutaneous techniques has become a standard practice in symptomatic infants(1). The incidence of arrhythmia, following the device closure is rare in those

*From the Department of Cardiology, Christian Medical College, Vellore. * Visiting Faculty.*

Correspondence to: Dr. Bobby John, Lecturer, Department of Cardiology, Christian Medical College, Vellore 632 004, Tamil Nadu, India.

E-mail: bobeck@cmcvellore.ac.in

Manuscript received: Sesptember 9, 2005;

Initial review completed: January 24, 2006;

Revision accepted: April 23, 2007.

without a pre-existing one(2). More so, atrial flutter is uncommnn in infancy(3). We report a case of atrial flutter in a child following device closure which was successfully ablated.

Case Report

A four-month-old baby (weight 5.5 kg; length 60 cm; head circumference 39 cm) presented with failure to thrive and congestive cardiac failure associated with an episode of lower respiratory tract infection. The child's birth weight was 3030 g and he had perinatal asphyxia and hypoxia induced encephalopathy (stage II) requiring phenytoin.

He appeared lethargic and had subcostal retraction with a sinus tachycardia rate of 140 bpm. There was a widely split second heart sound accompanied by grade 3/6 systolic murmur in the pulmonary area. The liver was palpable 6 cm below the right costal margin associated with mild splenomegaly. Echocardiography revealed a large ostium secundum atrial septal defect (ASD) measuring 18 mm. He underwent percutaneous ASD closure at four months of age under general anesthesia. A 20 mm ASD occluder (Blockaid-Shanghai Shape Memory Alloy Company Ltd, China) was deployed. The post-procedure period was uneventful.

One month after the device deployment the child developed typical atrial flutter with a ventricular rate of 140 bpm. There was no residual shunt on echocardiogram He was initiated on rate control drugs which included propranolol and digoxin. Despite this the ventricular rate remained 140 bpm over the next several months.

At two years of age, due to persistent atrial flutter associated with fast ventricular rate, an

electrophysiological study with view to ablation was performed. The right femoral vein could not be cannulated and thus a single radiofrequency (RF) ablation catheter (6F, 4 mm tip. Biosense-Webster) was introduced via the left femoral vein. Since the ECG was consistent with typical counterclockwise atrial flutter it was decided to “empirically” attempt an isthmus cavo-tricuspid isthmus line. Ablation was performed in the temperature-controlled mode with a preset maximum temperature of 55°C. An intermediate line was attempted starting from the ventricular aspect of the tricuspid annulus and using a dragging technique extended to the inferior vena cava. At each spot RF energy was applied for a minimum of 20 seconds. Surprisingly, there seemed to be a large isthmus. Totally nine RF energies were required to reach from the tricuspid annulus to the IVC. During the 8th energy the atrial flutter terminated (*Fig. 1*). Following flutter termination, vigorous stimulation using programmed extra-stimuli, burst pacing and isoproterenol could not induce any tachycardia. The child has remained in sinus rhythm after 18 months of follow-up.

Discussion

Atrial tachyarrhythmia (AT) is known in patients

following surgical closure of atrial septal defect(4) Silversides *et al*(2) studied the immediate and long term complications associated with trans-catheter closure of the defect and found AT was common (13%) in the immediate follow up period, only in patients with past history of the arrhythmia(2) However, in this child, atrial flutter occurred only after trans-catheter closure of atrial septal defect. It is possible that persistent RA dilatation and fibrosis consequent to congestive cardiac failure pre-disposed to the development of this arrhythmia. Rosenblueth and Ramos(5) have demonstrated atrial flutter in a canine model, with mechanical obstacles; it is now known that for perpetuation of the re-entrant rhythm, areas of slow conduction are required. Therefore, its manifestation after the deployment of the device cannot exclude the possibility of the device altering the geometry of the atrium so as to change its conduction property Moreover, this is a rare arrhythmia in infancy. It is uncommon even in infants with atrial septal defects which would lead us to speculate that the mechanical obstacle produced by early closure of the defect with the device would have triggered the arrhythmia in this child(3).

To the best of our knowledge this is the first

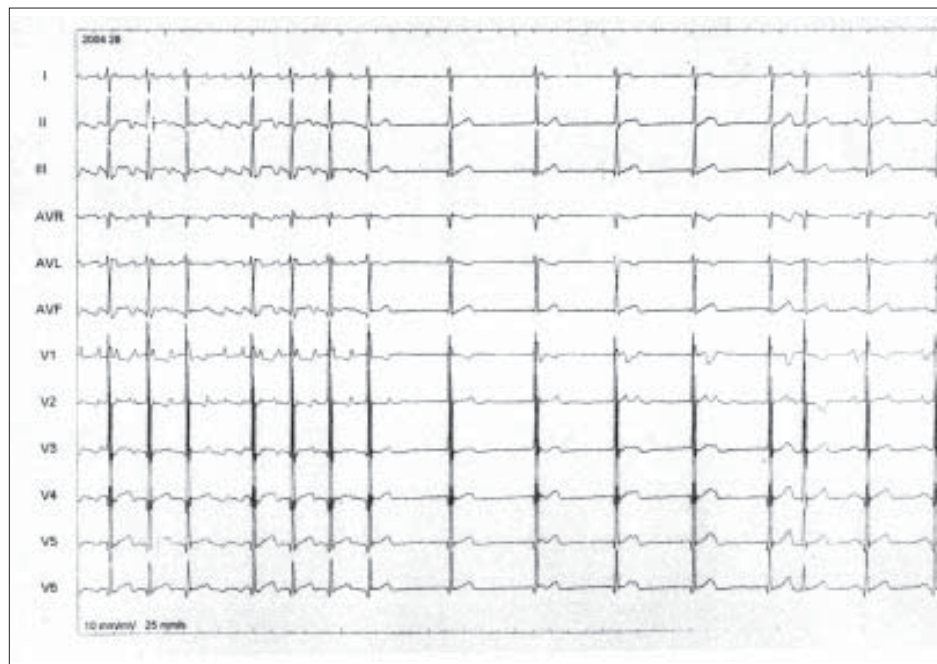


Fig. 1. 12 lead ECG showing termination of atrial flutter during radiofrequency ablation.

report of atrial flutter following device closure in an infant which was successfully ablated. In conclusion, caution has to be exercised in closing the atrial septal defects with a device in infants although it has been reported to be a safe alternative(6).

REFERENCES

1. Hijazi ZM. Catheter closure of atrial septal and ventricular septal defects using the Amplatzer devices. *Heart Lung Circ* 2003; 12 Suppl 2: 63-72.
2. Silversides CK, Siu SC, McLaughlin PR, Haberer KL, Webb GO, Benson L, *et al*. Symptomatic atrial arrhythmias and transcatheter closure of atrial septal defects in adult patients. *Heart* 2004; 90: 1194-1198.
3. Texter KM, Kertesz NJ, Friedman RA, Fenrich AL, Jr. Atrial flutter in infants. *J Am Coll Cardiol* 2006; 48: 1040-1046.
4. Berger F, Vogel M, Kramer A, Alexi-Meskishvili V, Weng Y, Lange PE, *et al*. Incidence of atrial flutter/fibrillation in adults with atrial septal defect before and after surgery. *Ann Thorac Surg* 1999; 68: 75-78.
5. Rosenblueth A, Ramos JG. Studies on flutter and fibrillation; II. The influence of artificial obstacles on experimental auricular flutter. *American Heart Journal* 1947 May; 33: 677-684.
6. Bialkowski J, Karwot B, Szkutnik M, Banaszak P, Kusa J, Skalski J. Closure of atrial septal defects in children: surgery versus Amplatzer device implantation. *Tex Heart Inst J* 2004; 31: 220-223.

Rabies Encephalitis

Ambeshprasad Mohite
Vinitha Prasad
L Rajam
SN Madhusudana*

A 12-year-old boy presented with fever and sore throat of 6 days duration followed by vomiting and altered sensorium. He had received 4 doses of antirabies vaccine following a dog bite 4 weeks back. Rabies immunoglobulin was not given. History of hydrophobia and aerophobia were strikingly absent. The possibilities of rabies encephalitis and vaccine induced acute disseminated encephalomyelitis (ADEM) were considered. MRI brain showed exclusive grey matter changes characteristic of rabies. The diagnosis was further confirmed by serological tests.

Key words: *Encephalitis, Hydrophobia, Rabies.*

Rabies should be considered in the differential diagnosis of any case of encephalitis, especially when there is a history of animal bite, signs of excitation or phobic symptoms. But atypical presentations can pose significant problems in the

diagnosis, especially when the patient is comatose and the pathognomonic signs are lacking. We describe a case of encephalitic rabies that presented without the classical symptoms of rabies like hydrophobia or aerophobia. Rabies occurring after postexposure antirabies vaccination creates a diagnostic dilemma when vaccine induced ADEM is a distinct possibility.

Case Report

A 12-year-old male child was brought to the Emergency room with vomiting and drowsiness of one day. He also had a history of fever and sore throat of 6 days.

*From the Department of Pediatrics, Amrita Institute of Medical Sciences and Research Center, Kochi, Kerala and *Department of Neurovirology, National Institute of Mental Health & Neurosciences, Bangalore, Karnataka, India.*

Correspondence to: Dr. Vinitha Prasad, Associate Professor of Pediatrics, Amrita Institute of Medical Sciences and Research Centre, Elamakkara PO, Kochi, Kerala 682 026, India.

Email: vinithaprasad@aims.amrita.edu.

Manuscript received: July 10, 2006;

Initial review completed: August 30, 2006;

Revision accepted: April 27, 2007.