

NEONATAL CHOLESTASIS SYNDROME: AN APPRAISAL AT A TERTIARY CENTER

S.K. Yachha, A. Khanduri, M. Kumar, S.S. Sikora, R. Saxena, R.K. Gupta and J. Kishore

From the Departments of Gastroenterology (Pediatric GE), Surgical Gastroenterology, Pathology and Microbiology, Sanjay Gandhi Post Graduate Institute of Medical Sciences, Lucknow 226014.

Reprint requests: Dr. S.K. Yachha, Assistant Professor, Department of Gastroenterology, Sanjay Gandhi Post Graduate Institute of Medical Sciences, Lucknow, 226 014.

Received for publication: September 23, 1995; Accepted: May 21, 1996

Objective: To know the magnitude, etiology and clinical profile, the efficacy of various investigations and the outcome in patients with neonatal cholestasis syndrome (NCS). **Design:** Prospective evaluation of 60 consecutive infants with NCS (mean age 3.9 ± 1.9 months; 49 males) over a period of 3.5 years. **Setting:** Tertiary level referral gastroenterology center in North India. **Methods:** Liver function tests, urine examination, serum antibodies against Cytomegalovirus (CMV), Rubella and Toxoplasma; abdominal ultrasonography, hepatobiliary scintigraphy and liver biopsy were done. In appropriate setting, laparotomy and surgical corrections were done for biliary tract disorders. **Results:** NCS constituted 19% of pediatric liver diseases. Considerable delay in presentation was observed [mean delay, extrahepatic biliary atresia (EHBA)= 4 ± 2.0 months, neonatal hepatitis (NH)= 2.2 ± 1.3 months]. Thirty three (55%) infants had EHBA, 14 (23%) NH (4 CMV, 2 galactosemia, 1 urinary tract infection and 7 idiopathic), 2 (3%) paucity of intralobular bile ducts and 11 (18%) were of indeterminate etiology. Liver biopsy was the most accurate (96.4%) investigation in discriminating between EHBA and NH. Of the 18 operated infants with EHBA (portoenterostomy 15 and hepatico-jejuno-stomy-3), 10 were alive (mean follow up= 22.8 ± 8.6 months) of which 4 were completely asymptomatic. **Conclusions:** (i) NCS is an important cause of liver disease in Indian children, (ii) It requires prompt referral, quick investigative approach and targeted management. (iii) Liver biopsy is highly accurate in differentiating EHBA and NH. (iv) Infants with EHBA and compensated status of liver should undergo corrective surgery irrespective of age at presentation.

Key words: Biliary atresia, Intrahepatic cholestasis, Hepatitis, Galactosemia, Portoenterostomy.

NEONATAL cholestasis syndrome (NCS) comprises two major groups, extrahepatic biliary atresia (EHBA) and neonatal hepatitis (NH)(1). Prompt distinction between EHBA and NH is crucial for management. EHBA is amenable to surgical correction and early surgery (within 8 weeks) is extremely important for successful bile drainage and prolonged survival (1-5).

Identification of underlying etiology of NH is essential because some subgroups are treatable or preventable(6).

Progress in management of NCS, particularly that of successful surgical correction and liver transplantation, has focused need to adopt prompt and appropriate

strategies to salvage such infants. Scarcity of data on NCS from India highlights the fact that the disease entity has not received appropriate attention and thrust in our country. We, therefore, undertook a prospective study in infants with NCS to know the (i) magnitude of the disease, (ii) distribution of etiology and clinical profile, (iii) diagnostic efficacy of various investigations, and (iv) the outcome.

Subjects and Methods

Sixty consecutive infants with NCS (mean age 3.9 ± 1.9 months; 49 males) admitted to our hospital between January 1992 through July 1995 were evaluated clinically and complete blood counts, liver function tests, serum urea and creatinine, blood sugar, HBsAg, IgM and IgG antibodies against *Toxoplasma*, *Rubella* and *Cytomegalovirus* (CMV) and urine examination (routine analysis and non-glucose reducing substances), abdominal ultrasonography (USG), hepatobiliary scintigraphy (99 m Technetium labelled BULIDA/mebrofenin) and liver biopsy were done. X-ray spine, eye examination, urine culture and work-up for septicemia and hypothyroidism were done in appropriate settings.

At USG, presence of intrahepatic biliary radicle dilatation, absence of gallbladder and absence/dilatation of the bile duct at the hilum were considered suggestive of EHBA. Presence of normal gallbladder and common bile duct at USG were considered favouring NH(7). At scintigraphy, absence of radioactivity in the small bowel at 24 hours was taken as indicative of EHBA; the presence of radioactivity in small bowel within 6 hours was considered diagnostic of NH(8). Standard criteria were used for the diagnosis of EHBA (enlarged portal tracts, bile ductular proliferation, portal tract fibrosis and bile plugs in portal triads), NH (collection of mononuclear cells in the hepatic lobule, fatty changes in the

hepatocytes, uneven staining of hepatocytes and predominant giant cell transformation) and the paucity of intra-lobular bile ducts (PILBD) on liver histology(9).

EHBA was diagnosed either by per-operative cholangiography (POC) or findings favoring EHBA both at scintigraphy and liver histology (Fig. 1). NH was diagnosed by liver histology and USG findings or by scintigraphy. The diagnosis was considered indeterminate in those infants in whom scintigraphy and USG was suggestive of EHBA but liver biopsy could not be performed. Laparotomy was done in children with (a) EHBA and compensated liver disease whose parents consented despite informing them of the poor prognosis at this advanced stage of the disease, and (b) doubtful diagnosis, viz., liver histology suggestive of NH but both USG and scintigraphy findings suggestive of EHBA (Fig. 1).

Results

NCS constituted 19% (60/316) of our pediatric liver diseases. Thirty three (55%) infants had EHBA, 14 (23%) NH, 2 (3%) PILBD (non-syndromic variety) and 11 (18%) were of indeterminate etiology. The diagnosis of EHBA was based on per-operative cholangiography in 19 cases and on liver histology and scintigraphy in 14. NH was diagnosed by scintigraphy with or without liver histology in 7 cases, liver histology and USG in 4 and POC in 3.

The clinical characteristics and liver function tests of patients with EHBA and NH are shown in *Tables I & II*. Of the 14 infants with NH, 4 had CMV infection, 2 galactosemia, one urinary tract infection (UTI) and the other 7 were of idiopathic etiology.

The sensitivity, specificity and accuracy of USG, scintigraphy and liver histology (*Table III*) were evaluated in infants with EHBA [confirmed by

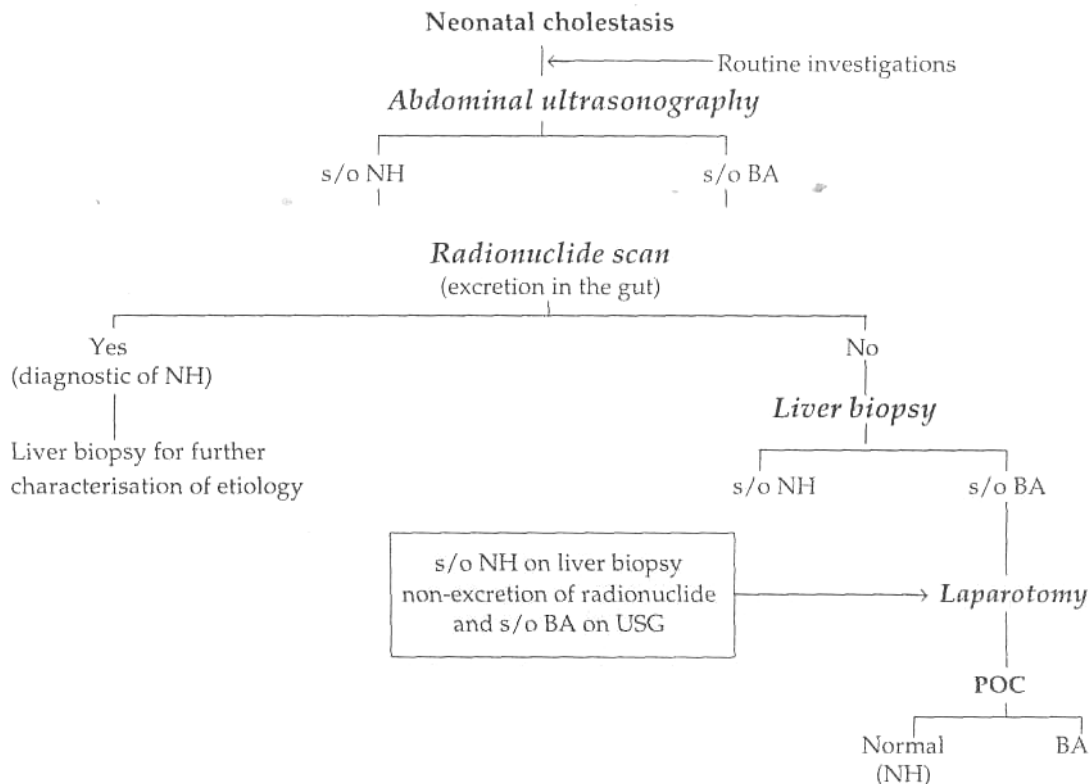


Fig. 1. Scheme of investigations used in the study for the diagnosis of neonatal cholestasis syndrome, (s/o-suggestive of, NH-neonatal hepatitis, BA=biliary atresia, USG=ultrasonography, POC=per-operative cholangiography).

EHBA [confirmed by POC (n=19)] and NH [confirmed by appearance of radioactivity in duodenum at scintigraphy (n=7) or POC (n=3)].

Treatment and Follow-up

Laparotomy was performed in 19/33 (58%) infants with EHBA. POC revealed type 2 EHBA in 3 (16%) infants and type 3 EHBA in 16 (84%). Hepatico-jejunostomy was done in type 2 EHBA cases and portoenterostomy in type 3. One infant with type 3 EHBA was not offered corrective surgery as ascites was detected at laparotomy. Mean age of infants at surgery was 4.6 (range 2.3-8.3) months and

78% had cirrhosis on liver histology. Three infants died; one during surgery (anaesthetic complications) and other 2 in the immediate post-operative period (septicemia). One infant had only recently been operated (< 2 months follow up) and had no complications. No follow up is available in 4 infants. The other 10 infants are alive at a mean follow up period of 22.8 ± 8.6 months. Four of these have remained completely asymptomatic (follow up of 1.5 to 3 yr) and 6 had recurrent cholangitis and jaundice. Of the latter, 4 have developed ascites and 2 variceal bleeding which was controlled by endoscopic sclerotherapy. Two of the 3 infants with

type 2 EHBA became completely symptom free even though they were referred very late (each at 8 months of age.)

The two infants with galactosemia died due to septicemia and hepatic decompensation in our hospital. One infant with idiopathic NH died during laparotomy (done to exclude EHBA) and 6 were lost to follow up. Jaundice resolved in 4 (CMV-1, UTI-1, idiopathic-2) infants over a mean duration of 5 ± 2.3 months. One infant (idiopathic) developed cirrhosis. No follow up is available in infants with indeterminate etiology.

Discussion

In our experience, NCS constitutes a significant proportion (19%) of childhood liver diseases in India. Delayed presentation (Table I) is more marked in our country [median age at presentation for EHBA= 4.4 (range 2.1-8) months] compared with that

TABLE I- Clinical Characteristics of Patients with Neonatal Cholestasis Syndrome

Attribute	EHBA (n=33)	NH* (n=16)
Age of onset of jaundice # (days)	12.6 ± 9.5	16.6 ± 12.7
Age at presentation# (mo)	4.4 ± 1.9	2.8 ± 1.3
Delay in presentation # (days)	120.8 ± 60.5	65.9 ± 39.2
Acholic stools	33 (100)	8 (50)
Hepatomegaly	33 (100)	16 (100)
Splenomegaly	32 (97)	15 (94)
Ascites	2 (6)	2 (13)

EHBA= Extrahepatic biliary atresia, NH= Neonatal hepatitis
 * 2 infants with paucity of intralobular bile ducts included
 # mean ± SD
 Figures in parenthesis indicate percentages

Table-II- Liver Function Tests in Infants with Neonatal Cholestasis Syndrome

Parameter*	EHBA (n=33)	NH (n=16)
Bilirubin (mg/dl)		
Total	13.9 ± 5.6	8.2 ± 7.4
Direct reacting	8.6 ± 4.2	4.5 ± 2.7
AST (IU/L)	243.0 ± 160	198.0 ± 138
ALT (IU/L)	174.0 ± 134	150.0 ± 97
Alkaline phosphatase (IU/L)	529 ± 297	572 ± 350
Total proteins (g/dl)	6.1 ± 1.4	6.1 ± 0.7
Albumin (g/dl)	3.4 ± 0.7	3.6 ± 0.9

EHBA= extrahepatic biliary atresia, NH=neonatal hepatitis, AST= Aspartate aminotransferase, ALT= Alanine aminotransferase. * Serum values expressed as mean ±SD

Table-III- Efficacy (percent) of Diagnostic investigations in Discriminating Between Biliary Atresia and Neonatal Hepatitis (n=29)

Test	Ultrasonography	Scinti graphy	Liver histology
Sensitivity for EHBA	68.4 #	100 @	100
Specificity for EHBA *	70	70	88.9
Positive predictive value	81.3	86.4	95
Negative predictive value	53.8	100	100
Accuracy	68.9	89.7	96.4

EHBA= Extrahepatic Biliary Artesia
 # All values expressed as percentages
 @ Scintigraphy has been used as ' gold standard' for NH. Therefore, by definition, the specificity of scintigraphy for NH, (which equals its sensitivity for EHBA) is 100 %
 * Specificity for EHBA= sensitivity for neonatal hepatitis and vice versa

in United Kingdom [median 2 (range 0.6-5.7) months](2). Others (10,11) have also observed delay in referral in Indian infants with NCS. Delayed presentation of patients with NCS in our country is probably due to two major factors, namely, misconceptions about jaundice and failure to seek immediate medical advice by the parents of the child, and delayed referral due to lack of awareness among doctors regarding the serious implications of delay by even a few weeks.

The enormously delayed presentation of our NCS patients hinders the performance of a liver biopsy due to deranged coagulation profile. In 12% of our cases, in correctable coagulation profile precluded a liver biopsy - a situation seldom encountered in other countries(2,7).

Our data, and that of others (7,11,12), suggests that liver biopsy is the most valuable investigation for discriminating between EHBA and NH. Scintigraphy alone definitely excluded EHBA in 7/56 of our infants with NCS. Cox *et al.*(13) found scintigraphy non-specific and time consuming; however, we found it to be a useful diagnostic tool.

Notwithstanding the late referral, we offered corrective surgery to infants with EHBA without decompensation. The most important determinant of successful portoenterostomy is age of infant at the time of surgery (2-5). We observed a high rate (6/8) of unsuccessful portoenterostomy (failure of jaundice to resolve completely) due to delayed presentation (mean age >4.5 months). Despite this, 56% (10/18) of the infants survived and 22% became jaundice free; 3 of the latter (portoenterostomy 1, hepatico-jejunoostomy 2) were more than 5 months of age at operation. Our results suggest that surgery should not be denied to infants with EHBA merely on the basis of late presentation. Chiba (14) has

suggested that Kasai's operation should not be done in patients over 4.6 months of age. However, others (15), including us, recommend surgery in infants with EHBA irrespective of age at presentation, unless hepatic decompensation has set in.

In conclusion, our study highlights that NCS constitutes a sizeable proportion of pediatric liver diseases in India. NCS requires prompt referral, quick investigative approach and targeted management. Liver biopsy is highly accurate in differentiating EHBA and NH. Infants with EHBA and compensated status of liver should be offered corrective surgery despite late presentation.

REFERENCES

1. Mowat AP, Psachoropoulos HT, Williams R. Extrahepatic biliary atresia versus neonatal hepatitis. A review of 137 prospectively investigated infants. *Arch Dis Child* 1976;51:763-770.
2. Mieli-Vergani G, Portmann B, Howard ER, Mowat AP. Late referral for biliary atresia - missed opportunities for effective surgery. *Lancet* 1989, i: 421-423.
3. Ohi R, Manamatsu M, Mochizuki I, Chiba T, Kasai M. Progress in the treatment of biliary atresia. *World J Surg* 1985, 9: 285-293.
4. Ohkohchi N, Chiba T, Ohi R, Mori S. Long-term follow-up study of patients with cholangitis after successful Kasai operation for biliary atresia: Selection of recipients for liver transplantation. *J Pediatr Gastroenterol Nutr* 1989, 9: 416-420.
5. Houwen RHJ, Zwierstra RP, Severijnen RSVM, et al. Prognosis of extrahepatic biliary atresia. *Arch Dis Child* 1989, 64: 214-218.
6. Mowat AP. *Liver Disorders in Childhood*, 3rd edn. Oxford, Butterworth-Heinemann Ltd, 1994, pp 43-78.

7. Lai MW, Chang MH, Hsu SC, Hsu HC, Su CT, Kao CL, Lee CY. Differential diagnosis of extrahepatic biliary atresia from neonatal hepatitis: A prospective study. *J Pediatr Gastroenterol Nutr* 1994, 18: 121- 127.
8. Rosenthal P, Miller JH, Sinatra FR. Hepatobiliary scintigraphy and the string test in the evaluation of neonatal cholestasis. *J Pediatr Gastroenterol Nutr* 1989,8:292-296.
9. Mowat AP. *Liver Disorders in Childhood*, 3rd edn. Oxford, Butterworth-Heinemann Ltd, 1994, pp 79-96.
10. Karnnarkar SJ, Oak SN, Ramadwar RH, Deshmukh SS. Biliary atresia: Need for an 'Indian effort', *Indian Pediatr* 1992, 29: 791-792.
11. Bavdekar A, Bhav S, Pradhan A, Datar G, Atre A, Pandit A. Discriminatory features and outcome of biliary atresia and neonatal hepatitis. In: *Scientific abstracts, 8th Asian Congress of Pediatrics*. Eds Choudhury P, Sachdev HPS, Puri RK, Verma IC. New Delhi, Jaypee Brothers Medical Publishers, 1994, p 85.
12. Tolia V, Dubois RS, Kagalwalla A, Fleming S, Dua V. Comparison of radionuclear scintigraphy and liver biopsy in evaluation of neonatal cholestasis. *J Pediatr Gastroenterol Nutr* 1989, 5: 30-34.
13. Cox KL, Stadalnik RC, McGahan JP, Sanders K, Cannon RA, Reubner BH. Hepatobiliary scintigraphy with technetium-99m disofenin in evaluation of neonatal cholestasis. *J Pediatr Gastroenterol Nutr* 1987, 6:885-891.
14. Chiba T. Indication of Kasai's operation for biliary atresia: For early decision of liver transplant. *Arch Jpn Chir* 1988, 57: 261-264. 5.
15. Miyano T, Fujimoto T, Ohya T, Shimomura H. Current concept of the treatment of biliary atresia. *World J Surg* 1993,17: 332-336.

NOTES AND NEWS

"Pediatrics For You" - Year Book 1995

- * Editor Dr. Sanwar Agrawal * 12 issues of the newsletter compiled in book form.
- * Contributions by eminent pediatricians from the country. * Pages 168, Price Rs. 100/-.
- * Limited Stock available.

Pediatrics For You: Monthly Newsletter

- * Annual subscription Rs. 100/-; Life Rs. 1000/-
- * Practical articles on day to day problems.
- * Contributions by eminent pediatricians.

Brainstorming Sessions in Pediatrics

- * Editors: Dr. Vijay P. Makhija and Dr. Sanwar Agrawal. * More than 1000 questions on useful pediatric problems. * Detailed answers on next page. * Very useful for practitioners and PG students.

Year Book Vol. II

- * Second 12 issues of the monthly newsletter in Book form.
- * To be ready by the end of 1996.

All payments by D/D or MO favoring "Pediatrics for You A/C Dr. Sanwar Agrawal" Payable at Raipur (MP) and mailed to Dr. Sanwar Agrawal, Agrawal Nursing Home, Shantinagar, Raipur (MP) 492 001.