

## Adrenoleukodystrophy

**Uma Raja**  
**K.A. Krishnamurthy**

Adrenoleukodystrophy (ALD) is an X linked disorder associated with progressive demyelination of cerebral white matter and adrenal insufficiency. We are reporting this case due to its rarity. The first recorded example of this disorder was by Siemerling and Creutzfeldt in 1923(1). The first case to be reported in an Indian child was in 1981(2).

### Case Report

A six and a half year old boy was brought in August '93 with the complaints of seizures, impaired vision and hearing and behavioral changes of one month duration. This boy was the 4th child of second degree parental consanguinity. The mother had 2 still births and has 2 female and one male child in apparently normal health. The patient's neonatal period and milestones were normal. He was apparently in good health till May 1992, when he developed hyperpigmentation of lips, buccal mucosa, nails and body associated with vomiting. A diagnosis of Addison's disease was made and he was put on corti-

---

*From the Department of Pediatrics, Meenakshi Mission Hospital and Research Centre, Lake Area, Melur Road, Madurai 625 107, Tamilnadu.*

*Reprint requests: Dr. (Mrs.) Uma Raja.*

*Received for publication: December 22, 1993;*

*Accepted: November 14, 1994*

costeroid replacement therapy which the child was not taking regularly.

In August 1993, 15 months after the diagnosis of Addison's disease was made, he presented with right focal fits, becoming generalized and deterioration of previously normal functions of vision, hearing and intelligence. General examination revealed an alert, normally nourished boy with diffuse hyperpigmentation more marked over lips, toe and finger nails. He was groping for objects while walking implying impaired vision. He spoke irrelevantly at times and laughed unprovoked. His cardiovascular, respiratory and abdominal systems were clinically normal. Power and tone in all muscles and the sensory system was clinically normal. Fundoscopic examination of both eyes were normal. Visual acuity testing revealed right homonymous hemianopia.

A clinical diagnosis of adrenoleukodystrophy was made as he had features of Addison's disease and those of cerebral white matter degeneration. The following investigations were done to support the diagnosis. Serum electrolytes showed a sodium of 120 meq/L, potassium of 4.6 meq/L, bicarbonate of 18 meq/L and chloride of 88 meq/L. Random blood sugar was 128 mg/dl. Mantoux was negative and VDRL was non-reactive. X-ray chest showed microcardia with normal lung fields. Serum cortisol was 3.1 mcg/dl at 8 AM and 2 mcg/dl at 8PM. CT scan brain showed hypodense areas over the parieto-occipital areas consistent with cerebral white matter degeneration (*Fig. 1*).

The child is being treated with oral corticosteroids for Addison's disease

and carbamazepine for convulsions. Although the child is free from seizures and pigmentation has almost disappeared, his vision is gradually deteriorating. He has no motor deficit at present.

### Discussion

ALD (adrenotesticuloleukomyeloneuropathic complex) is an x linked inherited disorder with considerable phenotypic variation(3). The defective gene is located on the long arm of the x chromosome (x q27-q28). It is due to a deficiency of peroxisomal enzyme that oxidises the very long chain fatty acids (C24:C26 Hexicosanoic acid)(4). The most common form occurs in childhood when progressive adrenal failure, seizures, nystagmus, impaired hearing and

neurological deterioration develop. Visual disturbances, deterioration in school performance behavior and memory are early features of this disorder. The disease is progressive, culminating within a few years in dementia, blindness, quadriplegia and death(5). Neurological manifestations may precede, follow or occur concomitantly with symptoms of adrenocortical insufficiency. Reduced adrenocortical reserve may be demonstrable even in children without clinical manifestations of the disorder. In this child the symptoms of adrenocortical insufficiency preceded the onset of neurological manifestations.

Adrenomyeloneuropathy is the second most commonly observed phenotype presenting with signs of

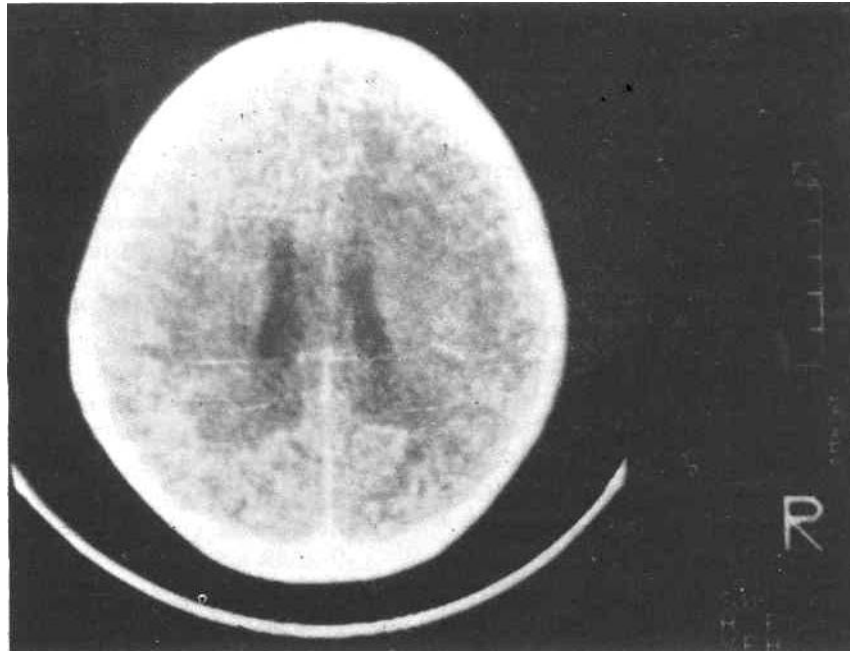


Fig. 1. CT scan brain-contrast study shows hypodense areas in parieto-occipital region in white matter close to the gyrus, consistent with leukodystrophy. The sulci and gyri appear normal.

myelopathy with progressive polyneuropathy and bladder dysfunction(3,5). Neonatal ALD has also been described though it must be sharply differentiated from the x linked disorder(6). Ohno *et al.* have reported a sporadic instance of ALD presenting as olivo pontocerebellar atrophy, illustrating how variable the symptomatology of the disorder can be(7).

The important laboratory findings are low serum sodium and chloride levels and elevated potassium levels reflecting the atrophy of the adrenal glands. The latter results in reduced excretion of corticosteroids, low serum cortisol levels and lack of rise in 17 hydroxy-ketosteroids after ACTH stimulation. CSF protein may be elevated. Massive degeneration of myelin occurs often asymmetrically in various parts of the cerebrum, brain stem, optic nerves and sometimes spinal cord. The cortex of the adrenal glands is atrophic and the cells and invading histiocytes contain an abnormal lipid material. The testes show marked interstitial fibrosis and atrophy of seminiferous tubules. Electronmicroscopically electron dense leaflets enclosing an electrolucent space are found in cerebral white matter, peripheral nerves, adrenal cortex and Leydig cells of testes(1). There is increased accumulation of C26-C30 fatty acids in the involved tissues. The C26: C22 ratio in mothers of ALD patients was between that found in patients and controls(4). There is impaired oxidation of very long chain fatty acids in leukocytes, cultured skin fibroblasts and amniocytes. This method should allow diagnosis of patients from only a skin biopsy and allow prenatal diagnosis in cultured amniotic fluid cells from at risk pregnancies(8).

Therapy is directed towards control of seizures with anticonvulsants and glucocorticoid replacement therapy. In x linked ALD, dietary restriction of very long chain fatty acids and addition of glycerol trioleate to the diet has lowered the plasma levels but has had only a marginal clinical effect. A pilot study has shown that addition of erucic acid (C22:1) to this regime normalizes the plasma very long chain fatty acids. However, the long term clinical and biochemical outcome of this therapy is not clear(9). Bone marrow transplantation has been done in one case of X-linked ALD(10).

#### REFERENCES

1. Adams RD, Victor M. Inherited metabolic disorders of the nervous system-Sudanophilic leukodystrophy with bronzing of skin and adrenal atrophy. *In: Principles of Neurology*, 5th edn. New York, Me Graw Hill Inc 1993, pp 840-841.
2. Desai M, Khatri JV, Pandit AN. Adrenoleukodystrophy. *Indian Pediatr* 1981,18:127-130.
3. Powers JM. Adrenoleukodystrophy (adreno-esticololeukomyeloneuropathic complex). *Clinical Neuropathology* 1985, 4:181-189.
4. Moser HW, Moser AB, Kawanmura N, *et al.* ALD: Studies of the phenotype, genetics and biochemistry. *Johns Hopkins Med J* 1980. 147: 217.
5. Moser HW, Naidu S, Kumar AJ, Rosenbaum AE. The Adrenoleukodystrophies. *Crit Rev Neurobiol* 1987, 5: 29-88.
6. Kelley RI, Datta NS, Dobyns WS, *et al.* Neonatal adrenoleukodystrophy: New cases, biochemical studies and differentiation from Zellweger related peroxisomal polydystrophy syndromes.

- Am J Med Genet 1986, 23: 869-901.
7. Ohno T, Tsuchida H, Fukuhara N, *et al.* Adrenoleukodystrophy: A clinical variant presenting as olivopontocerebellar atrophy. *J Neurol* 1984, 231:167
  8. Moser HW, Moser AE, Trojak JE, *et al.* Identification of female carriers of adrenoleukodystrophy. *J Pediatr* 1983, 103: 54.
  9. Rizzo WB, Leshner RT, Odone A, *et al.* Dietary erucic acid therapy for x-linked adrenoleukodystrophy. *Neurology* 1989, 39:1415-1422.
  10. Auborg P, Blanche S, Janbaque I, *et al.* Reversal of early neurologic and neuroradiologic manifestations of x-linked adrenoleukodystrophy by bone marrow transplantation. *N Engl J Med* 1990, 322:1860-1866.

## Noma Neonatorum

**N.C. Prajapati**  
**P. Chaturvedi**  
**R.R. Bhowate**  
**S. Mishra**

Noma, a Greek word meaning to '*deavour*' was described by Tourdes in 1848 as reported by Tempset(1). The term noma neonatorum (NN) was coined by Ghosal *et al.* in 1977(2). It is a rare gangrenous disease, that results in mutilating loss of tissue. We report two such

*From the Neonatal Unit, Departments of Pediatrics and Dental Surgery, Mahatma Gandhi Institute of Medical Sciences, Sevagram, Wardha 442 102.*

*Reprint requests: Dr. N.C. Prajapati, Reader in Pediatrics and Incharge Neonatal Unit, M.G. Institute of Medical Sciences, Sevagram, Wardha 442 102.*

*Received for publication: August 3, 1994;*

*Accepted: November 4, 1994*

cases along with review of literature.

### Case Reports

*Case 1:* A male baby, first of twins, was delivered vaginally at 34-36 weeks of gestation with a birth weight of 1340 g and Apgar score of 9, 10 and 10 at 1, 5 and 10 minutes, respectively to a second gravida. The second male twin weighed 1240 g. Both of them were kept in Special Care Neonatal Unit (SCNU) and fed expressed breastmilk (EBM) by nasogastric (NG) tube.

On 8th postnatal day, the first of the twins developed induration of lips and erythema of labial, palatal and alveolar mucosa with few black spots on the gum pad. Intravenous benzyl penicillin, gentamicin and metronidazole were started after taking samples for culture. By 10th day, there was conjunctivitis of both eyes and vesicular necrotic lesions developed in the groin. In view of clinical deterioration, nasogastric feeds were discontinued and cefotaxime was added to the therapy. Sclerema along with erythema and edema of the scrotum were also noticed. Culture reports (taken