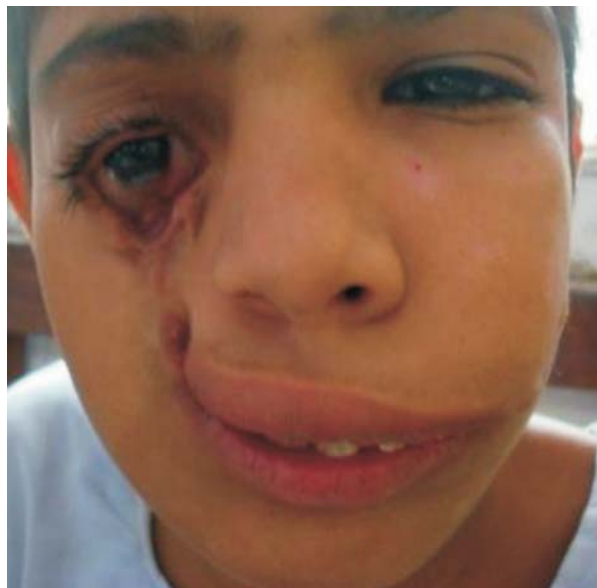


## Tessier Number 5 Cleft

Oblique facial cleft is an extremely rare and disfiguring congenital anomaly of the face manifests in a variety of patterns. Tessier classified craniofacial clefts from 0 to 14, which follow constant lines or axes through the eyebrows or eyelids, the maxilla, the nose and the lip. In these facial clefts, soft tissue and bony skeleton are often not involved to the same degree; the globe can be functional or may be microphthalmic or anophthalmic. The medial canthal tendon is intact but is displaced laterally and inferiorly. The nasolacrimal system is involved as the cleft runs medial to the punctum and through inferior canaliculus.

Among all facial clefts Tessier cleft No. 5 is least frequently found. Morian first drew attention to the infraorbital foramen in distinguishing different categories of facial clefts. In Tessier cleft no 5, the cleft passes lateral to infraorbital foramen (Tessier cleft No. 4 cleft passes medial to foramen). The pyriform aperture is not violated. The American Association of Cleft Palate Rehabilitation classified this anomaly as oro-ocular cleft type II.

AJAY GARG AND \*SHEETAL GOYAL



**FIG. 1** Clinical photograph showing cleft extending from right angle of mouth to lower eyelid at its middle and lateral junction.

Departments of Otorhinolaryngology, and  
\*Obstetrics and Gynaecology,  
PT BDS PGIMS, Rohtak, Haryana, India.  
E-mail: dr\_ajay\_garg@yahoo.co.in

## Persistent Swelling of Lip

A 10-year-old boy presented with history of recurrent swelling of both lips for 6 months and persistent swelling since 20 days. There was no history of applied irritants, local trauma or atopy. On examination his lips were swollen, firm and non tender (Fig. 1). There was no urticarial rash, facial palsy or fissured tongue. The findings of systemic examination were normal. The findings of routine blood workup and X-ray chest were normal. Based on the clinical features a diagnosis of granulomatous

cheilitis was made. Biopsy of lip showed multiple epitheloid cells in the dermis along with giant cells and perivascular infiltrate of lymphocytes, histiocytes and plasma cells suggestive of granulomatous cheilitis. The child was started on clofazimine and steroids.

Granulomatous cheilitis is a chronic, painless swelling of lips due to granulomatous inflammation. Episodic enlargement of the lips ultimately persists. Miescher cheilitis is the term used when