

Tessier Number 5 Cleft

Oblique facial cleft is an extremely rare and disfiguring congenital anomaly of the face manifests in a variety of patterns. Tessier classified craniofacial clefts from 0 to 14, which follow constant lines or axes through the eyebrows or eyelids, the maxilla, the nose and the lip. In these facial clefts, soft tissue and bony skeleton are often not involved to the same degree; the globe can be functional or may be microphthalmic or anophthalmic. The medial canthal tendon is intact but is displaced laterally and inferiorly. The nasolacrimal system is involved as the cleft runs medial to the punctum and through inferior canaliculus.

Among all facial clefts Tessier cleft No. 5 is least frequently found. Morian first drew attention to the infraorbital foramen in distinguishing different categories of facial clefts. In Tessier cleft no 5, the cleft passes lateral to infraorbital foramen (Tessier cleft No. 4 cleft passes medial to foramen). The pyriform aperture is not violated. The American Association of Cleft Palate Rehabilitation classified this anomaly as oro-ocular cleft type II.

AJAY GARG AND *SHEETAL GOYAL

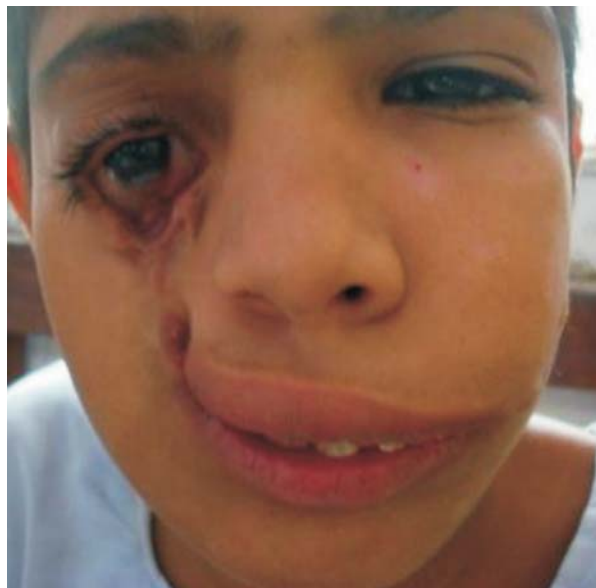

FIG. 1 Clinical photograph showing cleft extending from right angle of mouth to lower eyelid at its middle and lateral junction.

Departments of Otorhinolaryngology, and
*Obstetrics and Gynaecology,
PT BDS PGIMS, Rohtak, Haryana, India.
E-mail: dr_ajay_garg@yahoo.co.in

Persistent Swelling of Lip

A 10-year-old boy presented with history of recurrent swelling of both lips for 6 months and persistent swelling since 20 days. There was no history of applied irritants, local trauma or atopy. On examination his lips were swollen, firm and non tender (Fig. 1). There was no urticarial rash, facial palsy or fissured tongue. The findings of systemic examination were normal. The findings of routine blood workup and X-ray chest were normal. Based on the clinical features a diagnosis of granulomatous

cheilitis was made. Biopsy of lip showed multiple epitheloid cells in the dermis along with giant cells and perivascular infiltrate of lymphocytes, histiocytes and plasma cells suggestive of granulomatous cheilitis. The child was started on clofazimine and steroids.

Granulomatous cheilitis is a chronic, painless swelling of lips due to granulomatous inflammation. Episodic enlargement of the lips ultimately persists. Miescher cheilitis is the term used when

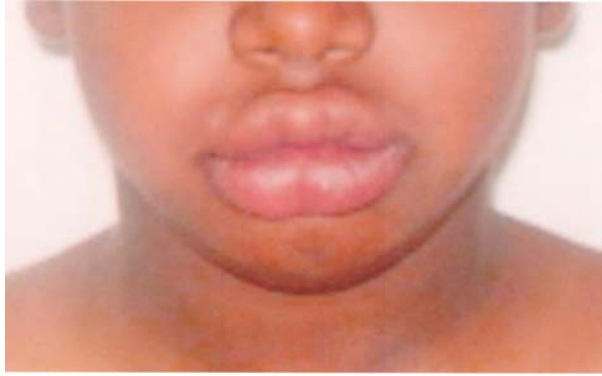

FIG. 1 Swollen lips due to granulomatous cheilitis.


granulomatous changes are confined to lip. Melkerson-Rosenthal syndrome is the term used

when cheilitis occurs with facial palsy and fissured tongue. The cause of granulomatous cheilitis is unknown. The differential diagnosis of granulomatous cheilitis includes angioedema, crohn disease, sarcoidosis, actinic cheilitis, cheilitis glandularis, neoplasms and infections such as tuberculosis, syphilis and leprosy. Treatment of granulomatous cheilitis is difficult and rate of recurrence is high. Treatment options include corticosteroids, clofamine, metronidazole, sulfasalazine, infliximab and cheiloplasty.

AM Vijayalakshmi and A Jayavardhana

*PSG Institute of Medical Sciences and Research,
Peelamedu, Coimbatore 641 004, TN, India.
dramvs@gmail.com*

BOOK REVIEWS



Practical and Viva in Pediatrics
BALARAM CHAUDHARY AND
VARSHA CHAUDHARY
Paras Medical Publisher:
Hyderabad
Pages: 315, Price: Rs. 275.00

This is a book with a novel idea of collection of practical and *viva voce* related question and answers. Undergraduate and postgraduate students will find it very useful for fast reviewing the practical aspects related to pediatrics, especially before the exams. Authors have done a fairly good job in covering most of the common topics.

The book has two sections, section A includes history taking and physical examination – general as

well as system wise. It also includes neonatal examination. Section B includes *viva voce* related to instruments, inhalation devices, x-rays, ECG, emergency drugs etc. It also contains *viva voce* related to infections, hematology, endocrinology, pediatric emergencies and poisoning. Book also contains *viva voce* on various National health programs.

The information provided is in a handy form and in an easily readable format with many useful tables, photographs and EKGs.

Raju C Shah,

*Ankur Institute of Child Health,
B/H City Gold Cinema, Ashram Road,
Ahmedabad 380009,
Gujarat, India.
rajucshah@rediffmail.com*