

- autopsy findings at 19 weeks. *Am J Med Genet* 1990,37: 583-591.
10. Serville F, Carles D, Broussin B. Fraser syndrome: Prenatal ultrasonic detection. *Am J Med Genet* 1989, 32: 561-563.
-

Aplasia Cutis Congenita with Congenital Contracture of Knee

**B.C. Bakane
Bhaidas Patil**

Aplasia cutis congenita is a rare developmental anomaly that most commonly involves vertex of the scalp and may be associated with other congenital anomalies. Although isolated congenital absence of skin and congenital knee contracture is known, association of these two conditions is not reported. We report on a child with absence of skin of left lower limb with contracture of left knee at birth.

Case Report

A two days old full term female child was admitted with complaints of absence of skin on left lower limb and inability to extend the left lower limb since birth. He was the first child of non-con-

sanguineous parents without any significant antenatal or family history. General, systemic and neurological examinations were within normal limits. Local examination revealed circumferential absence of skin on lower two thirds of left thigh, knee, leg and foot. The granulation was healthy. Examination of the knee revealed fixed flexion contracture (*Fig. 1*).

X-ray of left lower limb showed no bony abnormality. The patient was treated with dressing and antibiotics. Posterior plaster slab was applied in extension for knee contracture. The lesions were healing well. We advocated skin grafting but the patient did not turn up.

Discussion

Aplasia cutis congenita is a disorder in which localized or widespread areas of skin are absent at birth. The defect most commonly involves vertex of the scalp(1) and presents as solitary or multiple ulcers measuring upto several centimeters in diameter. Other parts of the body such as the trunk or limbs may be affected, often symmetrically, with or without accompanying scalp lesions(2). Association with other developmental abnormalities such as a cutaneous organoid nevi, cleft lip and palate, syndactyly, clubbing of hands and feet, congenital heart disease, vascular lesions and malformations of the brain are known(2,3).

From the Department of Surgery, J.M.F.'s, A.C.P.M. Medical College, Dhule, Maharashtra State, 424 001.

Reprint requests: Dr. Bhaidas Patil.

Received for publication: August 19,1994;

Accepted: November 27,1994

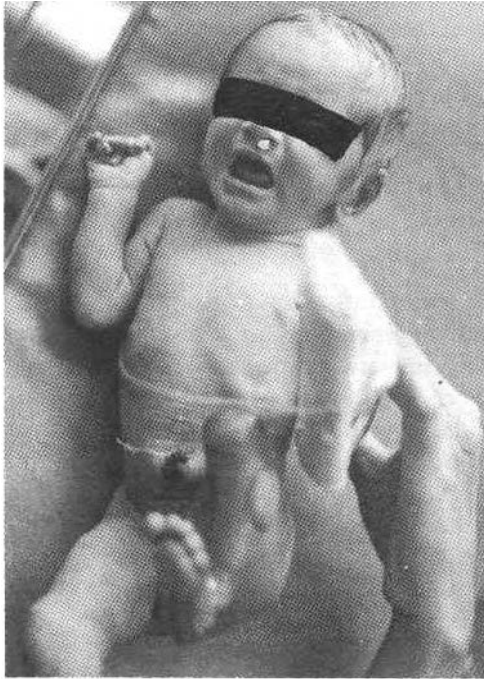


Fig. 1. Clinical photograph showing the lesion along with contracture of the left knee.

Although the exact etiology of the condition is unknown, the various postulated causes are autosomal dominant and autosomal recessive transmission of the defect(2), amniotic adhesions, intrauterine trauma, drugs (particularly the antithyroid drug, methimazole(4) and vascular thrombosis in infants with lesions on the trunk and limbs(5). Lesions on the scalp usually heal uneventfully

with cicatricial alopecia(6). The lesions which fail to heal can be grafted with split thickness skin graft.

The case under discussion had congenital absence of skin on left lower limb but the lesion was asymmetrical and without associated lesion of the scalp. The rare association of congenital contracture of knee with aplasia cutis congenita prompted us to report the case, which is a rare presentation along with aplasia cutis congenita.

REFERENCES

1. Guillen PS, Pichardo AR, Martinez FC. Aplasia cutis congenita. *J Amer Acad Dermatol* 1985,13: 429-433.
2. Sybert VP. Aplasia cutis congenita. A report of 12 new families and review of the literature. *Pediatr Dermatol* 1985, 3:1-14.
3. Frieden I. Aplasia cutis congenita. A clinical review and proposal for classification. *J Amer Acad Dermatol* 1986, 14: 646-660.
4. Kalb RE, Grossman ME. The association of aplasia cutis congenita with therapy of maternal thyroid disease. *Pediatr Dermatol* 1986, 3: 403-405.
5. Levin DL, Nolan KS, Esterly NB. Congenital absence of skin. *J Amer Acad Dermatol* 1980, 2: 203-206.
6. Mukvad JM, Nielsen AO, Asmussen T. Aplasia cutis congenita. A follow-up evaluation after 25 years. *Arch Dermatol* 1981,117: 232-233.