

Half Expressions: A Case of Unilateral Multiple Cranial Nerves Hypoplasia

A 5-month-old male child with normal birth events presented with history of asymmetric face, and inability to close left eye since birth. There was history of deviation of mouth while smiling, and gurgling sound from throat along with regurgitation of feed from nose on and off. Examination was suggestive of left sided infranuclear facial nerve and 8th, 9th, 10th, 12th cranial nerve palsy (**FIG. 1**). Rest of central nervous system and systemic examination was normal.

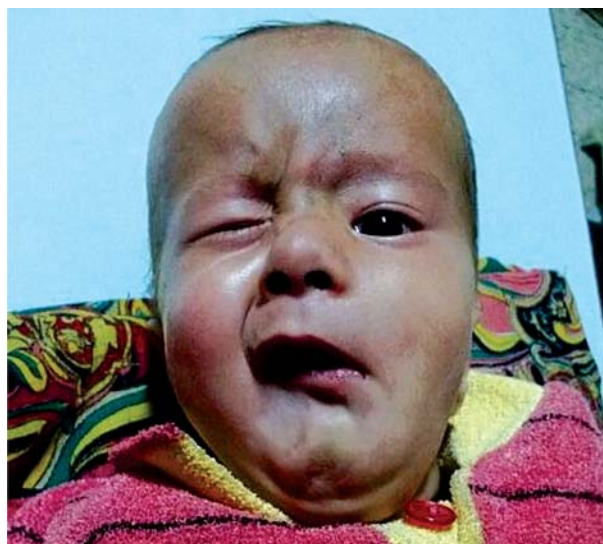

FIG. 1 Photograph of infant showing LMN left sided facial nerve palsy (LMN, lower motor neuron).

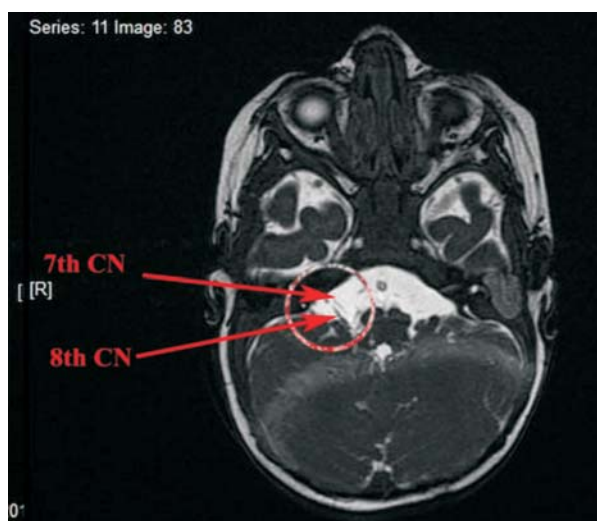


FIG. 2 MRI showing hypoplasia of multiple cranial nerves on the right side.

MRI brain showed hypoplasia of these cranial nerves on right side (**FIG. 2**) including that of 11th cranial nerve. In addition to syndromes like Duane syndrome, Congenital fibrosis of the extra ocular muscles (CFEOM), congenital ptosis, congenital facial palsy and Möbius syndrome, there exist a number of rare cases with congenital abnormalities of other cranial nerves. These occur due to defect in molecular signals that determine neuronal identity and axonal guiding in the brainstem.

*AJAY SHARMA, NAVEEN BHARDWAJ AND
SANDESH GULERIA
Department of Paediatrics,
Dr RPGMC, Tanda,
Kangra (HP)
*ajaysharma9595@gmail.com

Benign Cephalic Histiocytosis

An 8-month-old boy presented with multiple facial lesions present for the last 2 months, beginning as a cluster of small papules on the right cheek. Examination revealed multiple, 3-6 mm, erythematous, discrete as well as confluent, firm papules distributed symmetrically over

the cheeks, chin, forehead, and eyelids (**Fig. 1**). Routine hematological and biochemical tests, including lipid profile were normal. Histopathology of a papule showed a well-circumscribed collection of histiocytes in the upper and mid-dermis. The cells were S100 and CD1a negative but factor XIIIa positive. A diagnosis of benign cephalic histiocytosis was made and the child was kept under periodic follow-up.

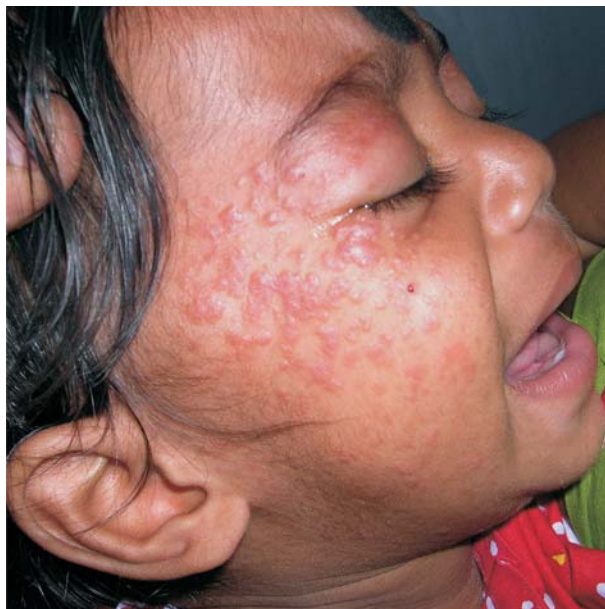

Fig. 1 Erythematous papules of benign cephalic histiocytosis.

Benign cephalic histiocytosis is a rare, self-limiting non-Langerhans cell histiocytic proliferative disorder of young children, primarily affecting the face. The average age of onset is 15 months. Asymptomatic erythematous macules and papules on the face gradually become reddish-brown and may spread to the neck, trunk, and upper limbs; mucous membranes are not involved. The differentials include Langerhans cell histiocytosis (red-brown papules that show erosion, hemorrhage and crusting), juvenile xanthogranuloma (orange/yellow papules often with mucosal/ocular involvement), urticaria pigmentosa (yellowish papules turning into weals on firm stroking), and generalized eruptive histiocytoma (recurrent crops of hundreds of yellowish/red-brown papules on face, trunk, and extensors). The eruption clears spontaneously after a variable period of time and requires no treatment.

***DEBABRATA BANDYOPADHYAY AND ABANTI SAHA**
Department of Dermatology
Medical College, Kolkata, India
**dr_dban@yahoo.com*

Pneumosrotum

A 5-day-old term male neonate presented with scrotal swelling, which was brilliantly transilluminant (even without the use of torch), with shiny overlying skin (**Fig.1**) and gross abdominal distension (inset image). It was soft to touch, easily reducible with characteristic refilling with air. This differentiated it from hydrocele of tunica vaginalis and lymphangioma of inguinoscrotal region. There was history of rectal instrumentation for delayed passage of meconium, following which the symptoms gradually developed. As clinical signs of perforation peritonitis with pneumosrotum were evident, an exploratory laparotomy was performed, which revealed a rent in the recto-sigmoid. The scrotal swelling spontaneously reduced as the peritoneal cavity was opened, which again differentiated it from hydrocele. Repair of perforation was done after taking biopsy from margins. Histopathological examination of the specimen ruled out Hirschsprungs disease. Patient had unevenful recovery and was discharged on 9th day.

Pneumosrotum secondary to recto-sigmoid perforation following rectal instrumentation is extremely rare. Management must be directed towards its cause. Rectal irrigation must be performed gently with small volume (5-10 mL) of normal saline, using soft red rubber catheter to prevent such complications.

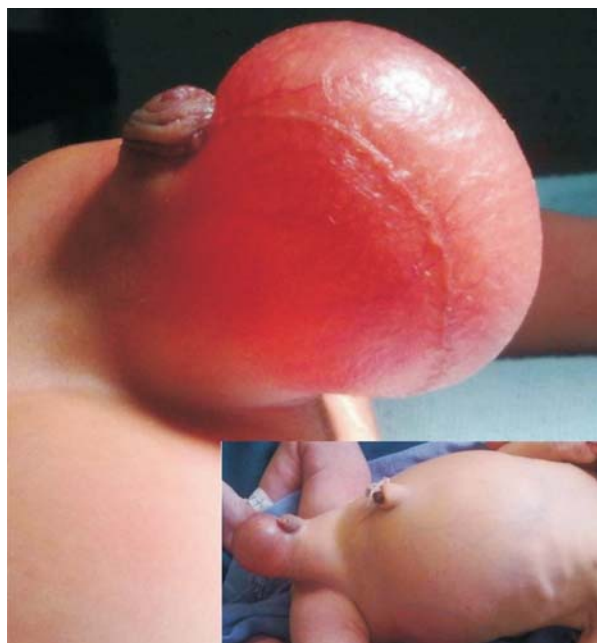

FIG.1 Brilliantly transilluminant scrotum suggestive of pneumosrotum.

RAHUL GUPTA AND SHYAM BIHARI SHARMA
Department of Paediatric Surgery,
NIMS University Medical College,
Jaipur, Rajasthan, India.
meetsurgeon007@yahoo.co.in