

thalassemia patients; however, it would be desirable that unchelated children older than 12 years should have their serum calcium and phosphate levels estimated at regular intervals of 3-6 months. Supplemental therapy with oral calcium and active form of vitamin D would preclude the occurrence of hypocalcaemia related complications. Although routine neuroimaging (CT scan) cannot be recommended, it should be done in children with neurological dysfunction.

*Contributors:* SV and RKM managed the patient; AKS reported the CT scan, SV reviewed the literature and RKM supervised the same.

*Funding:* None.

*Competing interests:* None.

## REFERENCES

1. Costin G, Kogut MD, Hyman CB, Ortega JA. Endocrine abnormality in thalassemia major. *Am J Dis Child* 1979; 133: 497-502.
2. De Sanctis V, Vullo C, Bagni B, Chiccoli L. Hypoparathyroidism in  $\beta$ -thalassemia major. Clinical and laboratory observation in 24 patients. *Acta Hematol* 1992; 88: 105-108.
3. Zafeiriou D, Athanasiou M, Katzos G, Economou M, Kontopoulos E. Hypoparathyroidism and intracranial calcification in b-thalassemia major. *J Pediatr* 2001; 138: 411.
4. Karimi M, Habibzadeh F, De Sanctis V. Hypoparathyroidism with extensive intracranial calcification in patients with b-thalassemia major. *J Pediatr Endocrinol Metab* 2003; 16: 883-886.
5. Kurz P, Monier-Faugere MC, Bognar B, Werner E, Roth P, Vlachoianis J, *et al* Evidence for abnormal calcium homeostasis in patients with adynamic bone disease. *Kidney Int* 1994; 46: 855-861.
6. Goel A, Bhatnagar MK, V ashisha A, Verma NPS. Hypoparathyroidism with extensive intracranial calcification: a case report. *Postgrad Med J* 1994; 70: 913-915.

## Suprasellar Arachnoid Cyst with Delayed Puberty

**Raj Kumar  
Namit Singhal**

*A 15-year-old female presented with primary amenorrhea and delayed onset of secondary sexual characteristics. Earlier she was operated for endoscopic third ventriculostomy (ETV) for a tense suprasellar arachnoid cyst with obstructive hydrocephalus. MRI revealed recurrence of hydrocephalus. Hormonal levels were suggestive of hypogonadism and deficiency of growth hormone. She was operated for fenestration of cyst. In this case, suprasellar arachnoid cyst presented with delayed puberty, which is unusual.*

**Key words:** *Delayed puberty, Suprasellar arachnoid cyst.*

Arachnoid cysts constitute approximately 1% of intracranial masses, with 50-60% occurring in middle cranial fossa. Other locations include suprasellar/chiasmatic cistern, cerebello pontine

angle (11%), quadrigeminal plate cistern (10%), in relationship to vermis (9%) and prepontine/interpeduncular cistern (3%). Most arise as developmental anomalies. Arachnoid cysts often are an incidental finding on imaging. The most common associated clinical features include headache, calvarial bulging, intracranial hypertension, cranio-megaly, developmental delay, visual loss and seizures. Arachnoid cysts may cause a wide spectrum of endocrinological disorders, most common being precocious puberty and GH deficiency. We report an interesting case of suprasellar arachnoid cyst presenting with delayed puberty and physical developmental delay.

*From the Department of Neurosurgery, Sanjay Gandhi Postgraduate Institute of Medical Science, Lucknow 226 014, U.P., India.*

*Correspondence to: Dr. Raj Kumar, Associate Professor, Department of Neurosurgery, Sanjay Gandhi Postgraduate Institute of Medical Science, Lucknow 226 014, U.P., India. E-mail: rajkumar@sgpgi.ac.in*

*Manuscript received: March 2, 2007;*

*Initial review completed: June 1, 2007;*

*Revision accepted: June 28, 2007.*

### Case Report

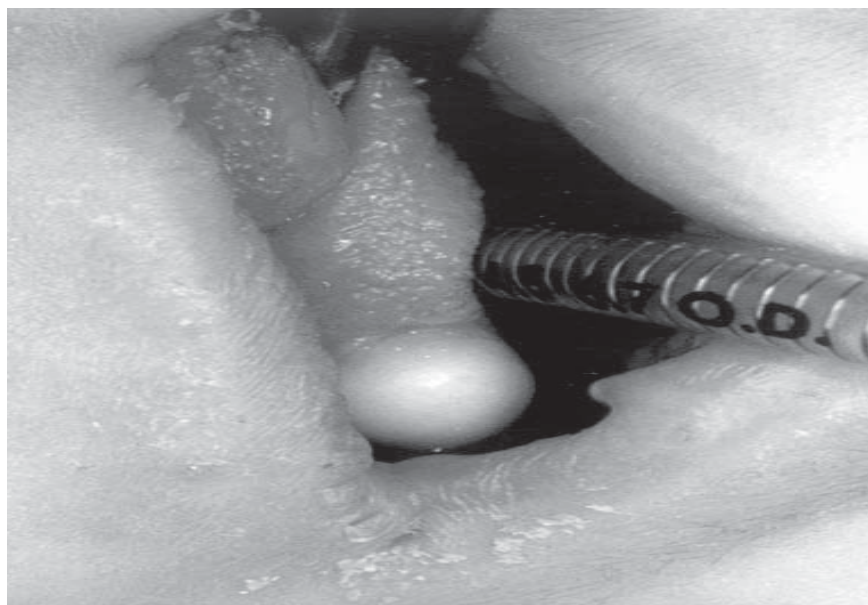
A 15-year-old girl was referred to Neurosurgery OPD at Sanjay Gandhi Postgraduate Institute of Medical Sciences (SGPGIMS) for complaints of primary amenorrhea and delayed onset of secondary sexual characteristics. Earlier she had been operated for endoscopic third ventriculostomy (ETV) 2 years back. MRI done at that time revealed a tense suprasellar arachnoid cyst indenting third ventricle with obstructive hydrocephalus. Following ETV and probably fenestration of cyst, the symptoms of raised ICP improved but there was no improvement in pubertal delay. Examination revealed an alert girl of normal stature with delayed secondary sexual characteristics. MRI showed a large well defined cyst in suprasellar cistern extending from interpeduncular cistern to base of third ventricle superiorly causing obstructive hydrocephalus (*Fig.1*). Hormonal evaluation revealed low FSH (2.03 mIU/mL), low LH (<1.0 mIU/mL) and a low insulin stimulated GH (<.05 ng/mL). Serum cortisol, prolactin, TSH and free T4 were normal. Insulin stimulated serum cortisol level was not performed. Ultrasound abdomen showed presence of both the ovaries without any associated tubo-ovarian mass. Genetic analysis revealed normal XX karyotype. A right pterional craniotomy and fenestration of cyst

was done via a transsylvian approach. Post operatively patient started having irregular menses after three months. Hormonal assay at 3 months showed increase in values of FSH (5.01 mIU/mL) and LH (3.4 mIU/mL). The patient refused further investigations because of financial constraints.

### Discussion

Puberty is said to be delayed when symptoms do not appear by age 13 for girls and 14 for boys. A complete medical history, review of systems, growth pattern, and physical examination is essential. The most valuable blood tests are the gonadotropins, because an elevation confirms immediately a defect of the gonads or deficiency of the sex steroids. CT/MRI of the head must be obtained in every case to rule out a central pathology.

Review of literature shows association of arachnoid cyst with precocious puberty in most of the cases(1). A study by Mohn, *et al.*(2) revealed that not only precocious puberty but a variety of other hormonal symptoms may be associated with arachnoid cysts. Sugawara, *et al.*(3) reported that pressure effect of these cysts on hypothalamus, at least in part, is responsible. Only few case reports suggest association of delayed puberty with



*Fig. 1. Tense suprasellar arachnoid cyst reaching upto interpeduncular cistern.*

arachnoid cyst(4). This association could be multifactorial including panhypopituitarism, pressure effect on pituitary stalk, pressure effect on hypothalamus or could be a result of hydrocephalus. Tasar, *et al.*(5) also reported hypogonadotrophic hypogonadism in association with middle fossa arachnoid cyst which was extending to suprasellar cistern. Cholley, *et al.*(6) has reported delayed puberty in children with non tumoral hydrocephalus. The role of a paracrine factor, however, cannot be ruled out. The lack of association of delayed puberty with arachnoid cyst in other locations rules out the presence of an inhibiting endocrine factor.

Hormonal evaluation suggested partial hypothalamic or direct pituitary dysfunction; and excluded any stalk compression. Management in such cases includes hormonal replacement therapy, anabolic steroids in case of associated developmental delay and surgical decompression of the cyst, as carried out in the present case. Simultaneously, it is anticipated that opening of lamina terminalis and floor of third ventricle will re-establish the CSF pathway. Shunt in such cases may result into secondary aqueductal stenosis which may lead to a requirement of life long shunt and its complications(7,8). Review of literature suggests that treatment of such cases by ETV and cyst wall fenestration is the procedure of choice, but as evident in present case, it was not found to be a sustained option. Sood, *et al.*(9) has reported wide endoscopic fenestration and coagulation shrinkage of suprasellar arachnoid cyst to prevent cyst recurrence and obstruction of aqueduct by remnants of cyst wall-the two main reasons for failure of a simple endoscopic fenestration.

There is not enough evidence in literature regarding the follow up improvement in patients of suprasellar arachnoid cyst with delayed puberty(4). It is anticipated that relief of pressure on hypothalamus/pituitary by decompression of cyst is likely to induce secondary sexual characteristics in these patients. The extent of recovery in function however, cannot be predicted. This could be explained on basis of residual hypothalamic dys-

function or end organ resistance due to prolonged stimulus deprivation.

*Contributors:* RK finalized the manuscript and is the guarantor. NS was responsible for composition of manuscript and literature.

*Funding:* None.

*Competing interests:* None stated.

## REFERENCES

1. Starzyk J, Swiatkowski S, Starzyk B, Bartnik-Mikuta A, Harasiewicz M, Dziatkowiak H. Suprasellar arachnoidal cysts as cause of precocious puberty. *Endokrynol Diabetol Chor Przemiany Materii Wieku Rozw* 2001; 7: 11-15.
2. Mohn A, Schoof E, Fahbusch R, Wenzel D, Dorr HG. The endocrine spectrum of arachnoid cysts in childhood. *Pediatric Neurosurg* 1999; 31: 316-321.
3. Sugawara A, Ebina K, Ohi H, Sawataishi J, Akabane M, Itoh T, *et al.* Suprasellar arachnoid cyst associated with precocious puberty-report of an operated case and review of the literature. *No Shinkei Geka* 1992; 20: 1107-1112.
4. Adan L, Bussieres L, Dinand V, Zerah M, Pierre-Kahn A, Brauner R. Growth, puberty and hypothalamic-pituitary function in children with suprasellar arachnoid cyst. *Eur J Pediatr* 2000; 159: 348-355.
5. Tasar M, Bozlar U, Yetisher S, Bolu E, Tasar A, Gonul E. Idiopathic hypogonadotrophic hypogonadism associated with arachnoid cyst of the middle fossa and forebrain anomalies. *J Encrinol Invest* 2005; 28: 935-939.
6. Cholley F, Trivin C, Sainte-Rose C, Souberbielle JC, Cinalli G, Brauner R. Disorders of growth and puberty in children with non-tumoral hydrocephalus. *J Pediatr Endocrinol Metab* 2001; 14: 319-327.
7. Kirolos RW, Javadpour M, May P, Mallucci C. Endoscopic treatment of suprasellar and third ventricle-related arachnoid cysts, *Childs Nerv Syst* 2001; 17: 713-718.
8. Kumar R, Jindal Y, Jha S. Suprasellar arachnoid cyst with precocious puberty, *J Pediatr Neurol* 2005; 3: 189-193.
9. Sood S, Schuhmann MU, Cakan N, Ham SD. Endoscopic fenestration and coagulation shrinkage of suprasellar arachnoid cysts. Technical note. *J Neurosurg* 2005; 102: 127-133.