

Idiopathic Epilepsy with Myoclonic–Absences

An 8-year-old boy presented to us with daily, multiple seizures for the last 6 months. The parents reported brief jerking of limbs lasting for few seconds resulting in occasional falls. These episodes had been treated elsewhere as generalized tonic-clonic seizures with phenytoin and carbamazepine, with no response. There were no other seizure types or any history of cognitive decline. The family history was unremarkable. Clinical examination, and magnetic resonance imaging (MRI) of the brain were unremarkable and video-EEG is shown (**Fig. 1** and **Web Video 1**). The clinico-EEG features were consistent with a diagnosis of idiopathic epilepsy with myoclonic absences (MAE). His karyotype was normal. The seizures stopped after 2 months on valproate and clobazam.

MAE is very rare epileptic syndrome and the classical semiology consists of brief, bilateral myoclonic-jerks involving shoulders, arms and legs (time-locked with EEG-discharges), with variable impairment in consciousness with abrupt onset and termination. The predominant tonic contraction of shoulder muscles result in the classical elevation of the arms. Co-occurrence of the other seizure types is unusual in idiopathic subtype.

These repetitive myoclonic jerks are often mistaken for rhythmic clonic jerks. Presence of multiple such episodes in a day of brief duration with period of unresponsiveness and immediate recovery to normalcy along with ictal EEG correlate of 3 Hz suggests myoclonic absence seizure rather than generalized clonic seizures. Such seizure semiology may be seen in a neurologically normal child; but more commonly, it is seen in a neurologically abnormal child who may have abnormal EEG, abnormal neuroimaging or chromosomal abnormalities.

The treatment requires high-doses of valproate with lamotrigine or ethosuximide. However, the seizures may be resistant to treatment.

Contributors: PJ, SS: provided the clinical care to the patient; PJ: drafted the manuscript which was read and approved by both the authors.

Funding; None; *Competing interest:* None stated.

***PUNEET JAIN AND #SUVASINI SHARMA**

**Division of Pediatric Neurology,*

Department of Neonatal,

Pediatric and Adolescent Medicine,

BL Kapur Super Speciality Hospital;

and # Epilepsy Services, Division of Neurology,

Department of Pediatrics,

Lady Hardinge Medical College and

Associated Kalawati Saran Children's Hospital;

*New Delhi India. *puneet_mpa@yahoo.com*

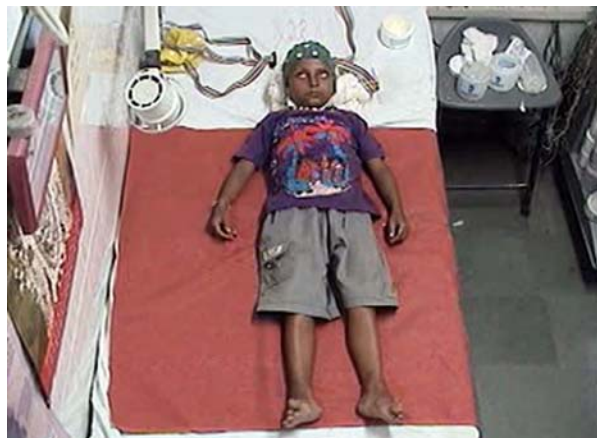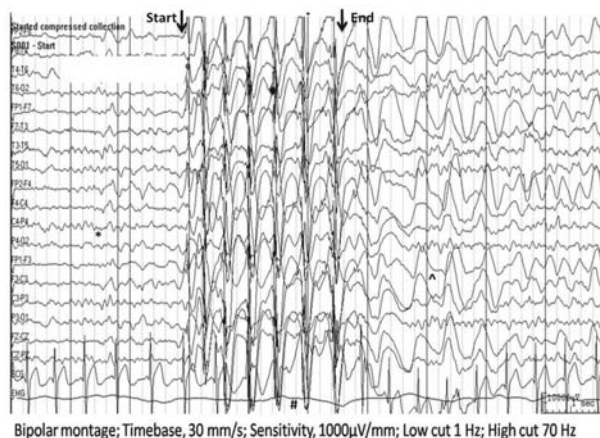


Fig. 1 and Web Video 1 Abrupt onset and offset of rhythmic, repetitive and bilateral myoclonic jerks involving shoulder, arms and legs associated with uprolling of eyeballs and period of unresponsiveness that lasts for 3 sec in Video 1. Onset of this brief clinical event was time-locked with generalized, high amplitude 3 Hz spike wave discharges (#) that lasted for 3 seconds till the end of clinical event followed by frontocentral delta slowing(^) (**Fig. 1**). This burst of generalized discharges was preceded by normal 8-9 Hz posterior dominant awake EEG rhythm (*) (**Fig. 1**).