

Fanconi anemia genes in leukemogenesis.

*Contributors:* All authors were involved with the treatment of the patient and writing of the manuscript. VS will act as a guarantor of the case report. All authors approved the manuscript.

*Funding:* None; *Competing interests:* None stated.

REFERENCES

1. Rosenberg PS, Greene MH, Alter BP. Cancer incidence in persons with Fanconi anemia. *Blood*. 2003;101:822-6.
2. Velez-Ruelas MA, Martinez-Jaramillo G, Arana-Trejo RM, Mayani H. Hematopoietic changes during progression from Fanconi anemia into acute myeloid leukemia: case

report and brief review of the literature. *Hematology*. 2006;11:331-4.

3. Alter BP. Cancer in Fanconi anemia, 1927-2001. *Cancer*. 2003;97:425-40.
4. Rosenberg PS, Huang Y, Alter BP. Individualized risks of first adverse events in patients with Fanconi anemia. *Blood*. 2004;104:350-5.
5. Tischkowitz M, Dokal I. Fanconi anaemia and leukaemia - clinical and molecular aspects. *Br J Haematol*. 2004;126:176-91.
6. Popp HD, Bohlander SK. Genetic instability in inherited and sporadic leukemias. *Genes Chromosomes Cancer*. 2010;49:1071-81.

## Johanson-Blizzard Syndrome

KOUMUDI GODBOLE,\*SUKALO MAJA,†HIREMATH LEENA AND \*ZENKER MARTIN

*From the Department of Genetic Medicine, Deenanath Mangeshkar Hospital and Research Center, Erandawane, Pune, India;*

*\*Institute of Human Genetics, University Hospital Magdeburg, Germany and †Consultant, Department of Pediatrics, Jehangir Hospital, Pune, India.*

*Correspondence to: Dr K. Godbole, Consultant Clinical Geneticist, Department of Genetic Medicine, Deenanath Mangeshkar Hospital and Research Center, Erandawane, Pune 411 004, India. koududig@rediffmail.com*  
*Received: November 27, 2012;*  
*Initial review: December 10, 2012;*  
*Accepted: December 20, 2012.*

We present clinical features and genetic diagnosis in an Indian infant diagnosed with Johanson-Blizzard syndrome. This is a rare, autosomal recessive genetic condition with multi-system involvement and a characteristic facies. Molecular genetic testing is important to confirm the clinical diagnosis and offer prenatal diagnosis in future pregnancies.

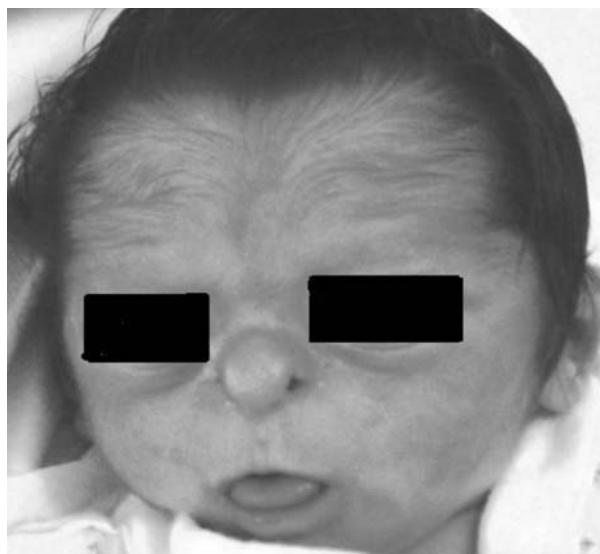**Key words:** Johanson-Blizzard syndrome, India.

**J**ohanson-Blizzard syndrome (MIM2G3800) is a rare, autosomal recessive genetic condition with a characteristic 'diagnostic facies'. We present an Indian infant with this condition.

CASE REPORT

A 12-day-old female newborn was referred for Genetics consultation for her unusual facies and congenital heart defect. She was the first born to 3rd degree consanguineous parents without any family history of major medical or genetic disorders, except for well-controlled maternal hypothyroidism. She was born normally at term with a birthweight of 2.45 kg and suffered from a secondary apnea requiring resuscitation followed by feeding difficulties and poor weight gain.

On examination, on day 12, she weighed 2.3 kg, had head circumference of 32 cm and length of 50 cm. She had a striking facies (**Fig. 1**) with a small beak-like nose with hypoplastic alae nasi, long narrow upper lip, open mouth with protruding tongue, prominent eyes with palpebral fissures slanting upwards and epicanthic folds. She had a



**FIG. 1** Patient at age of 12 days: Characteristic facies with beaked nose, hypoplastic alae nasi, long philtrum with thin upper lip and frontal hirsutism with upsweep of hair.

frontal upsweep of hair with hypertrichosis, especially on forehead. Additionally, she had clinodactyly of 5<sup>th</sup> fingers bilaterally. There was a systolic murmur on auscultation and she was noted to be hypotonic and lethargic. The rest of the systemic examination was normal. Her echocardiogram revealed an atrial septal defect with persistent ductus arteriosus while her abdominal ultrasound was normal. She was reported to have normal TSH and a normal 46, XX karyotype. Additionally otoacoustic emission screening had reported sensorineural hearing loss which was confirmed by BERA test later. A clinical diagnosis of Johanson-Blizzard syndrome was considered and molecular genetic testing including sequencing of *UBR1* gene was done homozygous mutation in the *UBR1* gene was detected.

On review at 7 months of age, pancreatic insufficiency with excess fat globules in stool sample and hypothyroidism had been diagnosed. She was receiving thyroxin supplement and pancreatic supplements for malabsorption secondary to pancreatic insufficiency with some improvement in weight (6.1 kg). She was prescribed bilateral hearing aids and regular physiotherapy with early intervention program for her developmental delay. Parents reported repeated hospital admissions for recurrent respiratory infections.

#### Molecular analysis

DNA from peripheral blood was extracted using standard method. All 47 exons including the flanking intron regions of *UBR1* gene were amplified by PCR. PCR amplicons were purified and subjected to direct sequencing using an automated sequencer. Sequences were compared to the reference sequences deposited in the public database (NM\_174916).

Homozygosity for a nucleotide substitution in intron 4 of the *UBR1* gene was found. The identified change c.529-13G>A has not been published, so far, but it was previously discovered in our laboratory in patient of Hispanic origin with the syndrome. The G to A substitution was demonstrated to introduce an ectopic splice site 11 base pairs upstream of the authentic splice acceptor of exon 5, thus leading to a shift of the reading frame (p.N177Lfs\*10) (**Fig. 2**). This change can therefore be assumed to represent a disease-causing mutation.

#### DISCUSSION

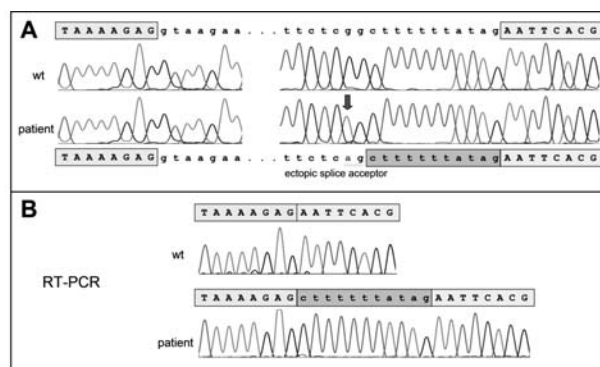
JBS in its typical expression can be diagnosed at birth with its characteristic facies. Ultrasound-based prenatal diagnosis has been reported previously [4,5] suspected by a beak-like nose and a dilated sigmoid colon suggestive of imperforate anus at 21 weeks of gestation. No such prenatal ultrasound features were detected in our patient and

ultrasound may not be the best modality to make a specific diagnosis of JBS especially in absence of a family history.

Patients with JBS need long-term care including management of pancreatic insufficiency and hypothyroidism, treatment of frequent respiratory infections, management of hearing loss, physiotherapy and educational rehabilitation depending on the intelligence level. Pancreatic insufficiency and severe hypoproteinemia may lead to death in infancy or early childhood, but for patients managed appropriately, survival into adulthood is not rare.

*UBR1* gene located on chromosome 15q15.2 is currently the only gene associated with JBS. It encodes E3 ubiquitin ligase of the N-end rule pathway which is an ubiquitin (Ub) dependent proteolytic pathway. *UBR1* is essential in the development and maintenance of acinar cells and *in-utero* destruction of acinar tissue followed by fatty replacement as well as eventual progression to endocrine deficiency leading to diabetes in older children has been previously reported [7-9].

Most patients have biallelic mutations predicting complete loss of function while cases with missense mutations or small in-frame deletions proposed to be hypomorphic mutations have been described with somewhat milder phenotypes and normal intelligence [3]. Our patient has an intronic mutation close to but not directly affecting the splice acceptor site of exon 5. We could demonstrate that this alteration creates an ectopic splice site resulting in an inclusion of 11 nucleotides from intron 4 into the coding sequence; those 11 additional base pairs cause a frameshift that lead to a premature stop codon (p.N177Lfs\*10). No evidence of a normally spliced transcript could be found by RNA analysis. We therefore presume that this mutation leads to a complete or near-complete loss of function which is in line with the classical JBS phenotype seen in this girl.



**FIG. 2** Electropherograms derived from gDNA and cDNA sequencing.

It is important for pediatricians to consider molecular testing of *UBR1* gene not only for the confirmation of diagnosis in the affected child but also for confirming carrier status in both parents and to offer appropriate counseling to the family.

*Contributors:* KG and LH were involved in the diagnosis and management writing the manuscript. MS and MZ performed laboratory analysis, critically reviewed the manuscript and also helped in writing it. The final manuscript was approved by all authors.

*Funding:* None; *Competing interests:* None stated.

## REFERENCES

- Johanson A, Blizzard R. A syndrome of congenital aplasia of the alae nasi, deafness, hypothyroidism, dwarfism, absent permanent teeth and malabsorption. *J Pediatr.* 1971;79: 982-7.
- Moeschler JB, Lubinsky MS. Johanson-Blizzard syndrome with normal intelligence. *Am J Med Genet.* 1985;22:69-73.
- Hwang C-S, Sukalo M, Batygin O, Addor MC, Brunner H, Aytes AP, *et al.* Ubiquitin ligases of the N-end rule pathway: assessment of mutations in *UBR1* that cause the Johanson-Blizzard syndrome. *PLoS ONE.* 2011;6:e24925.
- Vanlieferinghen P, Gallot D, Francannet Ch, Meyer F, Dechelotte P. Prenatal ultrasonographic diagnosis of a recurrent case of Johanson-Blizzard syndrome. *Genet Couns.* 2003;14:105-7.
- Auslander R, Nevo O, Diukman R, Morrad E, Bardicef M, Abramovici H. Johanson-Blizzard syndrome: a prenatal ultrasonographic diagnosis. *Ultrasound Obstet Gynaecol.* 1999;13:450-2.
- Townes PL, White MR. Identity of two syndromes. Proteolytic, lipolytic and amyolytic deficiency of exocrine pancreas and congenital anomalies. *Am J Dis Child.* 1981;135:248-50.
- Hurst JA, Baraitser M. Johanson-Blizzard syndrome. *J Med Genet.* 1989;26:45-8.
- Zenker M, Mayerle J, Lerch MM, Tagariello A, Zerres K, Durie PR, *et al.* Deficiency of *UBR1*, a ubiquitin ligase of the N-end rule pathway, causes pancreatic dysfunction, malformations and mental retardation (Johanson-Blizzard syndrome). *Nat genet.* 2005;37:1345-50.
- Steinbach EJ, Hintz RL. Diabetes mellitus and profound insulin resistance in Johanson-Blizzard syndrome. *J*

## Primary Vertebral Lymphoma Presenting with Fracture

ERMAN ATAS, VURAL KESIK, EROL KISMET AND VEDAT KOSEOGLU

*From Gulhane Military Medical Academy, School of Medicine and Department of Pediatrics, Ankara, Turkey.*

*Correspondence to:* Erman Atas, Gülhane Military Medical Academy, Department of Pediatric Oncology, 06018 Etilik, Ankara/Turkey. *e\_atas@yahoo.com*  
*Received:* October 08, 2012; *Initial review:* November 05, 2012; *Accepted:* December 20, 2012.

We report a 15-year-old girl admitted with back pain and multifocal osteolytic lesions without systemic symptoms at T7, L5, and S1 spinal vertebrae. The child was diagnosed as having primary multifocal osseous lymphoma, in which multiple bones are involved in the absence of lymph node or visceral disease for at least 6 months following initial presentation.

**Key words:** Bone, Lymphoma, Vertebra.

**P**rimarily lymphoma of bone occurs rarely in children and accounts nearly 2.8 to 5.9 percent of Non-Hodgkin lymphomas [1,2]. The incidence of a single vertebral lesion is reported to be 1.7% of all primary lymphoma of bones [3]. Most of the involved bones are long bones of the extremity, like femur [1]. The disease may resemble fracture, trauma and mimic inflammatory, neuropathic, and infectious conditions with these symptoms [4,5].

### CASE REPORT

A 15-year-old girl was admitted with back pain. On physical examination, there was tenderness on thoraco-

lumbar vertebrae. There was no history of trauma. Lymphadenopathy, mass and organomegaly were not detected. Laboratory data were as follows: Hb: 12g/dL, WBC: 6500/mm<sup>3</sup>, Platelet: 300000/mm<sup>3</sup>, sedimentation: 14 mm/h, LDH: 146 U/L, renal and liver function tests were normal. Thoracic vertebra X-ray showed lytic lesions on T7 vertebrae. Thoracic computed tomography (CT) showed reduced T7 vertebral corpus height, and lytic, hypodense areas in the L5 and S1 vertebrae. 18F-Fluorodeoxyglucose positron emission tomography (18F-FDG-PET) revealed increased activity on vertebral corpus of T7, T11 and L4 vertebra and normal lungs. Bone marrow aspiration and biopsy were normal. Pathologic