

## **Pulmonary Veno-Occlusive Disease**

**Shyam S. Kothari**  
**Mukti Sharma**  
**Zeba N. Singh**  
**Selina Bhatarai**

Pulmonary veno-occlusive disease (PVOD) is a rare disorder characterized by pulmonary hypertension secondary to progressive obstruction of the pulmonary veins and venules. The disease is known since its first description by Hora in 1934(1), but a case of PVOD, to the best of our knowledge, has not been reported in the Indian literature. The clinical diagnosis is often not made during life. We report a case of pulmonary veno-occlusive disease in a seven year old boy with typical clinical features of PVOD in whom the diagnosis was confirmed at autopsy.

### **Case Report**

A 7-year-old boy, resident of Rajasthan,

presented with the complaints of exertional breathlessness and paroxysmal nocturnal dyspnea for the last 5 months. There was no preceding history of fever, joint pains or cough. He was in good health previously and was not known to have any congenital heart disease.

On admission he was pale, with pedal edema and a raised JVP. The respiratory was at the rate 80/min and BP 120/90 mm Hg. There was no cyanosis. Severe pulmonary hypertension and gross tricuspid regurgitation were evident on examination. There was no mitral stenosis. The X-ray chest revealed a cardiothoracic ratio of 55%, prominent pulmonary arteries and right atrial enlargement. In addition, prominent upper lobe pulmonary veins, interstitial haze and Kerley B lines were present (*Fig. 1*). ECG revealed right axis deviation and right ventricular hypertrophy.

---

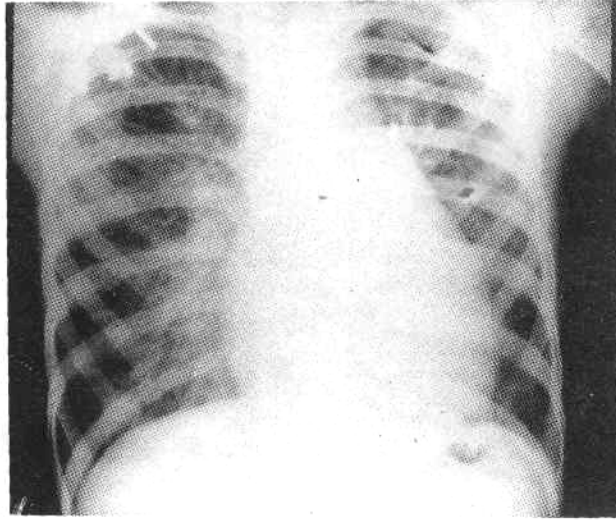
*From the Departments of Cardiology and Pathology,  
All India Institute of Medical Sciences,  
New Delhi 110 029.*

*Reprint requests: Dr. Shyam S. Kothari,  
Cardiothoracic Center, AIIMS, Ansari Nagar,  
New Delhi 110 029.*

*Received for publication: September 28, 1995;*

*Accepted: December 21, 1995*

---



*Fig. 1. X-ray chest showing prominent pulmonary arteries, right atrial enlargement, prominent upper lobe pulmonary veins, interstitial haze and Kerley B lines.*

Echocardiography showed an enlarged right atrium and ventricle, dilated pulmonary arteries, with severe tricuspid regurgitation. The Doppler signals suggested right ventricular systolic pressure to be approximately 95 mm Hg. No right to left shunt at atrial level was detected. There was no ventricular septal defect or patent ductus arteriosus. The mitral valve was normal. There was no evidence of pulmonary venous ostial stenosis. A clinical diagnosis of pulmonary arterial hypertension with tricuspid regurgitation and right heart failure was made. The possibility of PVOD was entertained because of orthopnea and the evidence of pulmonary venous hypertension on the chest X-ray. He was treated with diuretics and digoxin with no improvement. Vasodilators could not be given as he developed hypotension with test dose of nifedipine.

The patient did not improve and succumbed to a febrile episode possibly due to chest infection.

A partial autopsy revealed that both lungs were firm and crepitant and together weighed 825 g. There were multiple areas of hemorrhages 1-2 mm in diameter on the serosal surface. The cut surface also showed multiple areas of hemorrhages, the larger vessels did not show any evidence of thrombosis or occlusion, the bronchi were unremarkable. Microscopic sections from both lungs showed that majority of the medium and small sized pulmonary veins had eccentric/concentric intimal thickening due to fibrous tissue proliferation. Some of these veins showed multiple irregular openings representing recanalization (*Fig. 2*). In the pulmonary arteries, the changes were most marked in the muscular

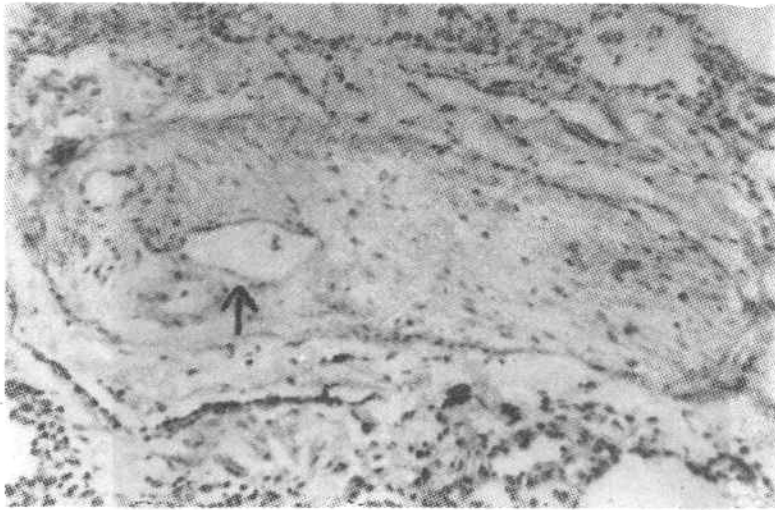


Fig. 2. Photomicrograph of the lung showing concentric intimal thickening of the pulmonary vein with areas of recanalization (arrow).

arteries with mild to moderate medial hypertrophy and intimal thickening. Small focal areas of necrosis were identified in the lung parenchyma with surrounding inflammatory reaction. Some of the vessels around these areas showed evidence of perivascular chronic inflammation. Numerous haemosiderin laden macrophages were seen in the alveoli. The paratracheal, cranial and parabronchial lymph nodes revealed reactive hyperplasia. Based on these findings a final diagnosis of pulmonary veno-occlusive disease was made.

### Discussion

Primary pulmonary hypertension may be idiopathic, thromboembolic or due to PVOD. These sub-sets are often clinically indistinguishable(2). However, a history of orthopnea or evidence of pulmonary venous hypertension on chest X-ray as in our case, might suggest the diagnosis of PVOD. Other causes of post capillary pulmonary hypertension like mitral stenosis, cor triatrium and proximal

pulmonary vein ostial stenosis should be excluded by echocardiography(3,4).

PVOD is characterized by narrowing or obliteration of the lumina of the small pulmonary veins by intimal fibrosis, often in association with acute or recanalized thrombi. Inflammatory changes around the veins are sometimes striking but may be absent(5). Nearly one third of the cases have occurred in children(6). The youngest reported patient was an 8 weeks young infant(5). The etiology of PVOD is not known. Viral infection, coagulation abnormalities and autoimmune mechanisms have been suspected(1,3). Radiation and anti-metabolites are known to cause PVOD(7).

It is interesting to note that an epidemic of veno-occlusive disease of the liver following ingestion of cereals contaminated with seeds of a crotalaria species has been reported from central India(8), and crotalaria is known to induce pulmonary hypertension in rats(9). However, no case

of crotalaria induced pulmonary hypertension or PVOD has been reported in humans(1).

Diagnosis of PVOD was seldom made during life previously, but more cases are now reported with the use of open lung biopsy(3). Anecdotal reports of clinical improvement in these patients with the use of steroids, antimetabolites, anticoagulants(1,3) and vasodilators(6) have been published, but the prognosis is usually dismal. Regardless of the etiology, the disease is fatal in the majority within 2 years of the onset of symptoms(3). Recently however, single lung transplant has been found to be very effective(10) A wider appreciation of the disease seems warranted.

#### REFERENCES

1. Wagenvoort CA, Wagenvoort N, Takahashi T. Pulmonary veno-occlusive disease: Involvement of pulmonary arteries and review of literature. *Hum Pathol* 1985,16:1033-1041.
2. Pietra GG, Edwards WD, Kay JM Rich S, Kernis J, Schloo B, *et al.* Histopathology of primary pulmonary hypertension. *Circulation* 1989, 80:1198-1206.
3. Justo RN, Dare AJ, Whight CM, Radford DJ. Pulmonary veno-occlusive disease: Diagnosis during life in four cases. *Arch Dis Child* 1993, 68: 97-100.
4. Dev V, Shrivastava S. Diagnosis of pulmonary vein obstruction by Doppler echocardiography. *Int J Cardiol* 1989, 22: 129-133.
5. Wagenvoort CA. Pulmonary veno-occlusive disease: Entity or syndrome ? *Chest* 1976, 69: 82-86.
6. Palevsky HI, Pietra GG, Fishman AP. Pulmonary veno-occlusive disease and its response to vasodilator agents. *Am Rev Respir Dis* 1990,142: 426-429.
7. Kramer MR, Estenne M, Berkman N, Antoine M, Franquen PD, Lipski A, *et al.* Radiation induced pulmonary veno-occlusive disease. *Chest* 1993, 104: 1282- 1284.
8. Tandon BN, Tandon HD, Tandon RK. Narendranathan M, Joshi YK. An epidemic of veno-occlusive disease of the liver in central India. *Lancet* 1976, 2: 271-272.
9. Wilson DW, Segall HJ, Pan LC, Lame MW, Estep JE, Morin D. Mechanisms and pathology of monocrotaline pulmonary toxicity. *Crit Rev Toxicol* 1992, 22: 307-325.
10. Wong J, Loyd JE, Merrill WH, Frist WH. Single lung transplant: A replacement therapy for end-stage lung disease. *South Med J* 1992,85: 887-893.