

Sacral Agenesis

Sacral agenesis belongs to spectrum of aplastic vertebral malformations ranging from agenesis of coccyx to lower thoracic vertebrae and the term sacral agenesis has been used synonymously with caudal regression syndrome. Higher the defect, severe is the neurological deficit. Mangeau and Leclaire described a patient with ninth thoracic vertebra as the lowest segment(1). Sacral agenesis is more common in the infants born to diabetic mothers. Sacral agenesis has been reported rarely in Indian literature(2).

A 6-year-old male child presented in 1984 with history of urinary incontinence and thinning of legs. Mental and motor milestones were normal except for delay in walking which he started at the age of two years. He had stress incontinence of urine but there was no history of incontinence of bowel. Thinning of thighs and legs had been noted since birth and it was not progressive. There was no such history in the family or siblings.

On examination, there was wasting of muscles of calves and thighs. Power was Grade IV-Grade III in the lower limbs. Knee and ankle jerks were absent in the lower limbs. Plantars were not elicitable. Buttocks were flat and hips were narrow. Intergluteal cleft was shallow and bilateral gluteal dim-

pling was there. Plain X-ray brought by the patient showed complete absence of sacrum, hemivertebrae of L3 and L4 and ilia fused with 5th lumbar vertebra. (Fig. 1.). Myelo/CT were suggested to the mother and she never brought the patient for follow up.

Caudal regression in the human is an exceedingly rare nongenetic developmental anomaly of tail bud formation. The buttocks are characteristically flattened, hips are narrow, with a presence of dimples and foreshortened intergluteal fold as seen in our case. Legs are usually tapered and there

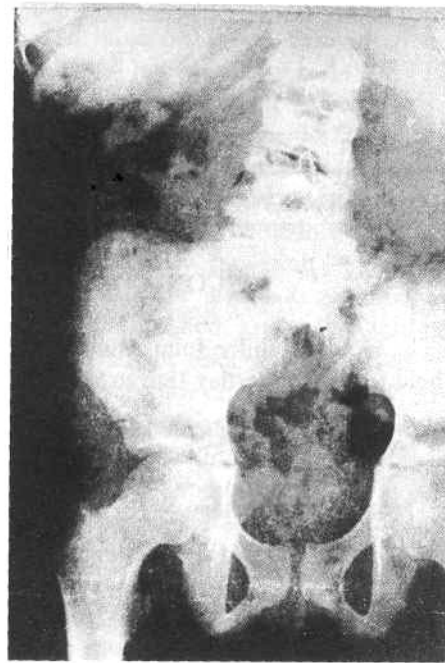


Fig. 1. Anteroposterior view of lumbosacral spine showing complete absence of sacrum, hemivertebrae of L3, L4 and ilia fused with 5th lumbar vertebra.

is calf atrophy. The motor loss parallels the last developed vertebra and sensory loss is at a lower level. Bladder dysfunction is quite common because of failure of development of 2nd to 4th sacral nerve roots.

Children with sacral agenesis may show progressive neurological deficit so these patients should be followed up regularly clinically and radiologically to rule out surgically correctable lesions like tethered cord, dermoid cyst, lipoma, *etc.*, the correction of which will improve the patient. MRI is the ideal present day investigation for it if the patient can afford it as it provides excellent anatomic resolution and saggital and axial views can be obtained.

Renshaw classified sacral agenesis into four types(3): Type I-partial or total unilateral sacral agenesis; Type II-partial sacral agenesis with a partial but bilateral symmetrical defect and a stable articulation between ilia and a normal or hypoplastic first sacral vertebra; Type H-variable lumbar and total sacral agenesis with ilia articulating with the sides of the lowest vertebra present; and Type-IV-variable lumbar and total sacral agenesis, the caudal

end-plate of the lowest vertebral resting above either fused ilia or an iliac amphiarthrosis. Our case belongs to Type III of Renshaw's classification. Treatment consists of correction of associated pathologies by neurosurgeon and orthopedic surgeon.

REFERENCES

1. Mongeau M, Leclaire R. Complete agenesis of the lumbosacral spine. *JBJS* 1972, 54A: 161-164.
2. Bhutani N, Tayal JP. Lumbosacral agenesis in a neonate. *Indian Pediatr* 1978,15: 363-365.
3. Renshaw TS. Sacral agenesis - A classification and review of twenty three cases. *JBJS* 1978, 60A: 373-383.

**S. Kumar,
M. Mehndiratta,
V. Puri,
S. Gupta,
A. Bhutani,**

*Departments of Neurosurgery, Neurology
and Radiology, G.B. Pant Hospital,
New Delhi 110 002.*

Superior Sternal Cleft

Superior sternal cleft is a rare congenital anomaly. Only one case has been reported, to our knowledge, in the Indian literature(1).

A fullterm baby was delivered to a fourth gravida mother. His birth weight was 2880 g with Apgar score of 9, 10 and 10 at 1, 5

and 10 minutes, respectively. Examination showed a 'U' shaped depression in the upper sternal region durring inspiration (Fig. 1). During expiration a large mass of tissue bulged in this region (Fig. 2). A hypopigmented cutaneous patch of 0.8 cm diameter with hyperpigmented rim was present in the region of the cleft (Fig. 2). On palpation a 'U' shaped notch in superior sternum extending upto the sternal angle could be appreciated.