

TABLE IV—Time of Disappearance of PEP

Time of disappearance	No. of cases
Within 24 h	2
Within 48 h	7
Within 72 h	6
Within 96 h	5
4 to 7 days	5
7+ days	2
Total	27

condition disappeared usually within 4 days and almost always within 7 days.

REFERENCES

1. Dubowitz LMS, Dubowitz V, Goldberg GC. Clinical assessment of gestational age in the newborn infant. *J Pediatr* 1970, 77: 1-10.

2. Faridi MMA, Adhami S. Prepuccial Epstein Pearls. *Indian J Pediatr* 1989, 56: 653-655.
3. Lawrence RA. Physical examination. *In: Assessment of newborn—A Guide for the Practitioner*, 1st edn. Eds Ziai M, Clarke TA, Meritt TA. Boston, Little Brown and Company, 1984, pp 91-95.
4. Milner RDG, Herber SM. A Colour Atlas of the Newborn. London, Wolfe Medical Publication Ltd, 1984, Fig 209, p 81.
5. Esterly NB. Diseases of the skin. *In: Nelson Textbook of Pediatrics*. 14th edn. Eds Behrman RE, Kliegman RM, Nelson WE, Vaughan III VC. Philadelphia, WB Saunders Co, 1992, p 1626.
6. Behrman RE, Kliegman RM, Nelson WE, Vaughan VC. Physical examination of the newborn infant. *In: Nelson's Textbook of Pediatrics*, 14th edn. Eds Behrman RE, Kliegman RM, Nelson WE, Vaughan III VC. Philadelphia, WB Saunders Co, 1992, p. 424.

Landau-Kleffner Syndrome in Cerebral Cysticercosis

M.S. Bhatia
S. Shome
R.K. Chadda
Saurabh

An aphasic syndrome, first described by Landau and Kleffner(1), occurs exclusively in children and consists of motor aphasia, EEG epileptic discharges, epileptic seizures in three-fourth cases and behavioral disor-

ders in about two-third of previously normal children, usually boys(1,2). The first symptoms appear between two to thirteen years of age, with a maximum incidence between 3-7 years of age. Since the description of this syndrome, about 90 cases(2-9) have been described. The aim of presentation of the present case is the rarity of this

From the Department of Psychiatry, University College of Medical Sciences and Associated Guru Teg Bahadur Hospital, Shahdara, Delhi 110095.

Reprint requests: Dr M.S. Bhatia, D-1, Naraina Vihar, New Delhi 110028.

Received for publication: March 11, 1993;

Accepted: October 28, 1993.

syndrome, its unusual presentation without classical seizures or cognitive decline and its association with neurocysticercosis.

Case Report

The case reported here was a seven-year-old girl who presented with episodes of motor aphasia lasting two to ten minutes, occurring 2-3 times in a week for last six months. They were not associated with any tonic clonic movements or disturbance in consciousness. According to the mother, the child had shown more obstinacy since the

onset of the problem. There were symptoms suggestive of situational hyperactivity at home but her scholastic performance showed no decline. The child had normal development. There was no past or family history of psychiatric or chronic physical disorder. The case was referred from the Pediatric Outpatient Department where a battery of investigations including complete hemogram, Mantoux test, X-ray chest and skull and fundus examination were conducted and found to be within normal limits. General physical examination including de-

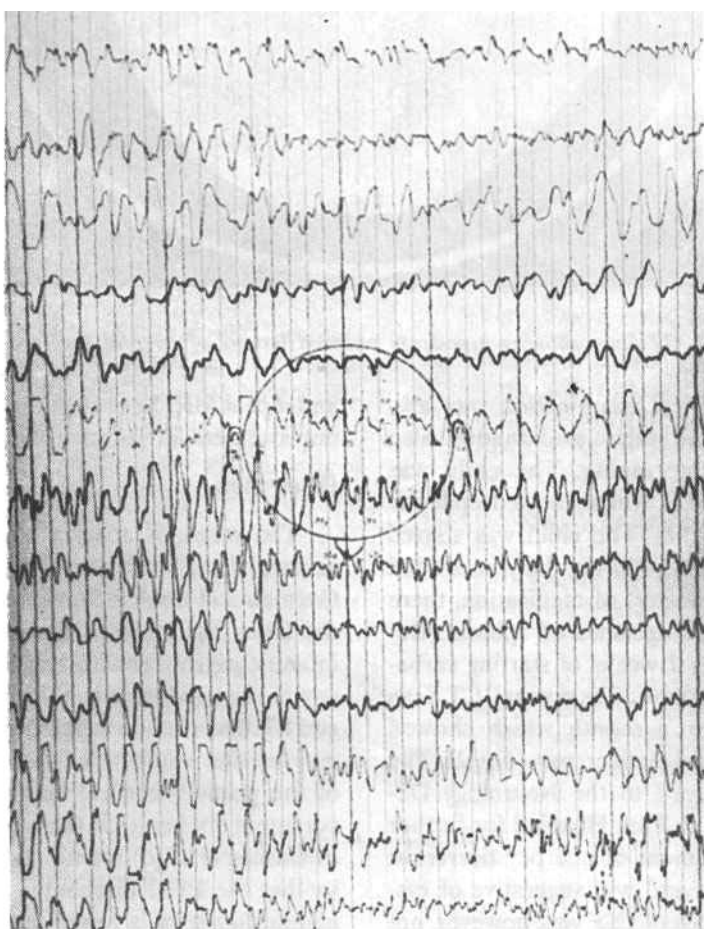


Fig. 1. EEG showing epileptic discharges (Montages FP2-C 4-P3-01)

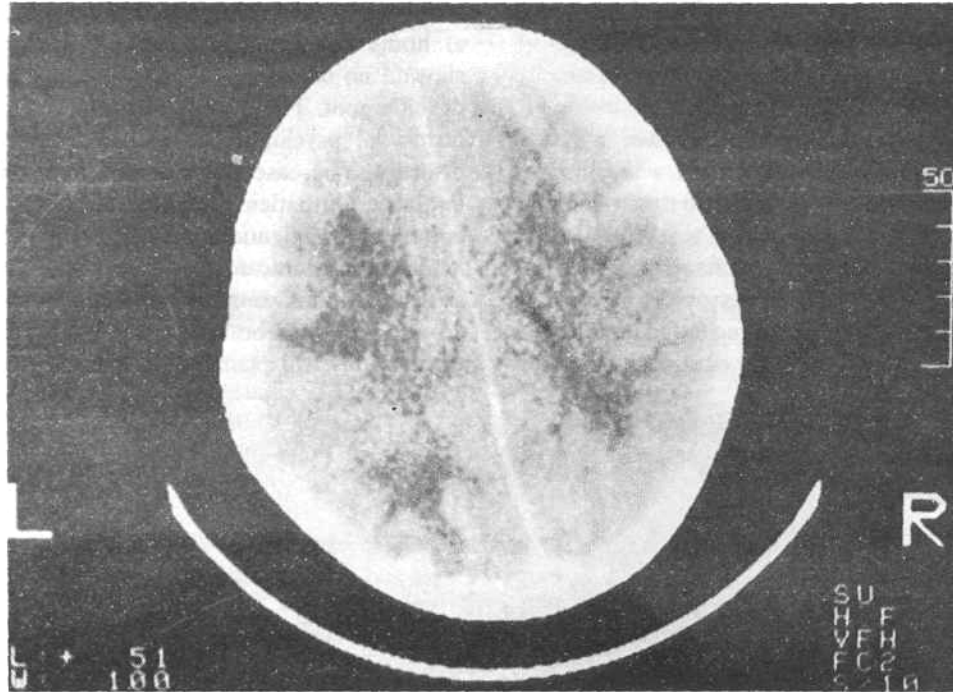


Fig 2 CT Scan showing hypodense rounded lesions of cerebral cysticercosis.

tailed neurological examination was also normal. Mental status examination also showed no abnormality. The child was subjected to EEG which showed epileptic discharges (*Fig. 1*). The child was started on carbamazepine 300 mg daily in divided doses. After the start of medication, there were no further episodes of aphasia. Repeat EEG after 2 weeks of starting carbamazepine was reported as normal. CT Scan was done after a month which showed multiple cerebral cysticercosis (*Fig. 2*). The child was referred to the Neurology Department of G.B. Pant Hospital for further indoor management of neurocysticercosis. MRI was done and was suggestive of cysticercosis. ELISA of CSF was, however, not done. The child was put on praziquantel

and repeat MRI Scan after 2 months showed improvement in parenchymal cysts.

Discussion

The cases of aphasia with subclinical seizure disorder have been reported in German and English literature(10), though the latter has stressed the relationship of infantile psychoses with aphasia. The etiology of this syndrome is not known. Landau and Kleffner(1) had suggested that aphasia may be the result of a functional ablation of the primary cortical language areas by persistent discharges in these regions whereas Gascon *et al.* (6) mentioned the possibility that the EEG discharges are a cortical manifestation of a lower level subcortical differentiating process. The global aphasia

experienced by child seems to be related to constant EEG spike activity in left temporo-occipital region. The studies(9,10) made on a cortical biopsy reported findings suggestive of 'slow virus' meningoencephalitis. However, the present case had neurocysticercosis, an association not yet reported.

Medical anticonvulsant treatment has no obvious influence on the aphasia(2), seizures may respond to anticonvulsants(11) but the present case showed good response to carbamazepine, thus showing the aphasia was closely related functionally to the abnormal electrical activity.

This syndrome has been more frequently reported among males(11-13) but the present case was a girl.

REFERENCES

1. Landau WM, Kleffner FR. Syndrome of acquired aphasia with convulsive disorder in children. *Neurology*. Minneap 1957, 7: 523-525.
2. Landau WM, Kleffner FR. Acquired aphasia with convulsive disorder in children. Report of 12 cases. *Rev Neurol* 1982, 138: 755-780.
3. Worster-Drought C. An unusual form of aphasia in children. *Dev Med Child Neurol* 1971, 13: 563.
4. Bhatia MS, Singhal PK, Balkrishna, Mittal S. Aphasic syndrome. *Indian J Pediatr* 1988, 55: 987-990.
5. Dugas N. The Landau-Kleffner syndrome—infantile acquired aphasia, paroxysmal electroencephalographic changes and epileptic seizures. *Nouv Presses Med* 1982, 11: 3787-3791.
6. Gascon G, Victor D, Lambroso CT, Goodglass H. Language disorder, convulsive disorder and EEG abnormalities. *Arch Neurol* 1973, 28: 156-158.
7. Deonna T, Beaumencir A, Galilard F, Assal G. Syndrome of acquired aphasia in childhood with seizure disorder and EEG abnormalities. Zurich, *Eur Group Child Neurol*, 2nd Conference, September 1975.
8. Foester C. Aphasia and seizure disorders in childhood (a case report). *In: Epilepsy. The Eighth International Symposium*. Ed Penry JK. New York, Raven Press, 1977, p305.
9. Rasnau T, Me Cann W. Clinical studies of patients with focal epilepsy due to "Chronic encephalitis". *Trans Am Neurol Assoc* 1968, 93: 89-92.
10. Lou HC, Sven B, Bruhn P. Progressive aphasia and epilepsy with a self-limited course. *In: Epilepsy. The Eighth International Symposium*. Ed Penry JK. New York, Raven Press, 1977, pp 295-296.
11. Dugas M, Masson M, Le Heuzey MF, Regnier N. Aphasie 'acquise' de 1 enfant avec epilepsie (Syndrome de Landau et Kleffner). *Revue Neurologique* 1982, 138: 755-780.
12. Deonna T, Beaumanoir A, Gaitlard F, Assal G. Acquired aphasia in childhood with seizure disorder: A heterogenous syndrome. *Neuropaediatric* 1977, 8: 263-273.
13. Clevrie JJ. Epileptic seizures and epilepsies in childhood. *In: Clinical Neurology*. Eds Swash M, Oxbury J. Edinburgh, Churchill Livingstone, 1991: 233-254.