

Post-Traumatic Intradiploic Pseudomeningocele

DEEPAK AGRAWAL AND SHASHWAT MISHRA

From the Department of Neurosurgery and Gamma Knife, Neurosciences Centre, All India Institute of Medical Sciences, New Delhi 110 029, India.

Correspondence to: Dr Deepak Agrawal, Assistant Professor, Department of Neurosurgery & Gamma Knife, Neurosciences Centre, All India Institute of Medical Sciences, New Delhi 110 029, India. ved@vsnl.com

Received: May 22, 2007;

Initial Review: August 14, 2007;

Accepted: February 10, 2009.

We report a four year old boy who was detected to have an occipital intradiploic pseudomeningocele three years following a traumatic skull fracture, and which was managed by ventriculo-peritoneal shunt placement. Traumatic intradiploic pseudomeningoceles behave differently from traditional growing skull fractures and may require individualized management decisions.

Key words: *Intradiploic pseudomeningocele, Leptomeningeal cyst, Skull fracture.*

A pseudomeningocele is formed when there is a tear in the dura with protrusion of the leptomeninges and the subarachnoid space through the dural defect. Classically, growing skull fractures caused by the pseudomeningoceles have been described in the pediatric age group. However an intradiploic location of these pseudomeningoceles is rare; and only twenty cases are described(1-12). We present a four year old child who developed this uncommon condition following a traumatic injury.

CASE REPORT

A four-year-old boy had sustained a head injury when a heavy object had fallen on him at the age of about one year. The child was comatose for about a week following injury and had made gradual recovery. Presence of a progressive occipital swelling caused the parents to seek medical advice at 3 years of age. A plain CT head was performed at another centre revealed a fracture in the inner table of the occipital bone with the presence of an intradiploic pseudomeningocele (*Fig 1a*). The outer table is seen to bulge outwards along this location but is otherwise intact. The pseudomeningocele was misinterpreted by the treating surgeon to be a calcified chronic subdural hematoma and a burr-

hole evacuation was attempted. However, as only cerebrospinal fluid was obtained, the procedure was abandoned. One month following the procedure the child developed a progressively enlarging swelling at the surgical site which became more prominent when the child cried.

The child was referred to us in an unconscious state, with a Glasgow coma score of E1V1M3. A repeat CT head showed gross hydrocephalus with a subcutaneous CSF collection in the occipital region which was communicating with the intradiploic pseudomeningocele through the burr-hole (*Fig 1b, 1c*). An emergency ventriculo-peritoneal shunt was placed, following which there was dramatic recovery in the child's sensorium along with resolution of the occipital swelling. The child is presently on follow up and remains asymptomatic.

DISCUSSION

An intradiploic pseudomeningocele is rare sequel of skull fracture in the pediatric age group. The varied presentation of this condition and the time span between the trauma and the formation of the pseudomeningocele may result in misdiagnosis and in cases with concomitant hydrocephalus, a ventriculoperitoneal shunt may be considered as the

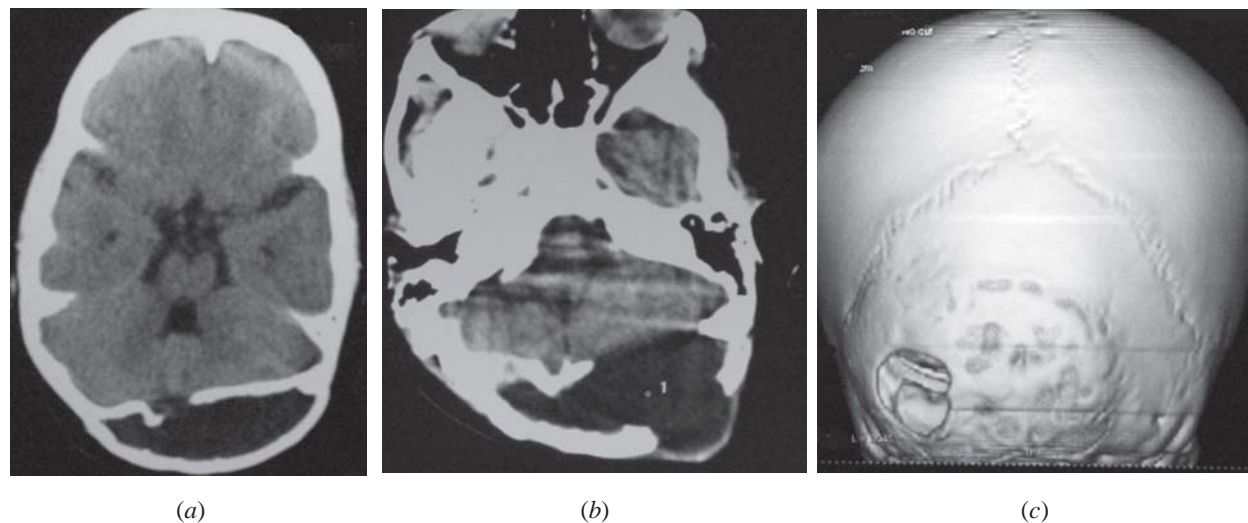


FIG. 1 (a) Plain CT head, axial section demonstrating a defect in the inner table of the occipital bone with associated hydrocephalus. The outer table is seen to be bulging outwards. (b) Plain CT head, axial section showing the subcutaneous bulge through the burr hole site. (c) 3D reconstruction CT of the occipital region demonstrating the defect in the inner and outer table of the occipital bone.

first line of treatment. Several mechanisms have been postulated for the formation of growing skull fractures(5-7,11,12). It is widely agreed that the leptomeninges prolapse through the bony defect in the fractured skull bone and the pulsations of the normally growing brain prevents the approximation of the dural as well as bony margins. Growing skull fractures are uncommon in the occipital region because, the thickness of the occipital bone and the overlying thick muscle cover, render it quite resilient(8), nevertheless, in certain cases the inner table of the occipital bone may be fractured leaving the outer table intact. A concomitant dural laceration at the fracture site subsequently leads to the progressive insinuation of the leptomeninges into the intradiploic space. The growing brain provides a ball valve effect resulting in an intradiploic leptomeningeal cyst. The mechanism of formation of the intradiploic meningocele is essentially similar to that of the growing skull fracture with some important differences. Due to their tendency to develop in the occipital region it is hypothesized that an abundant muscle cover buttressing the outer table of the occipital bone and the thickness of the bone prevents the development of the classical lytic bony defect associated with the growing skull fracture (8). Unlike growing skull fractures, pencephaly, cystic encephalomalacia,

ipsilateral ventricular dilatation and seizures are not seen to be associated with an intradiploic meningocele(11).

The largest series of post traumatic intradiploic cysts have been reported by Mahapatra, *et al.*(7). Of the 8 cases reported by them 6 were in the parieto-occipital region with 1 each in the frontal region, parietal region and roof of the orbit. The time span between injury and presentation ranged from one year to ten months. Patil, *et al.*(10) described a variant of the intradiploic cyst with protrusion of the parenchyma through the dural defect. They theorized that the recoiling edges of the fractured bone might create the requisite negative pressure for the leptomeninges and the cortex to be sucked into the defect.

These cysts must also be differentiated from the intradiploic arachnoid cysts which are probably congenital in origin, are typically located within 3 cm of the midline in the occipital region, and generally causes loss of the inner table of the skull and thinning of the outer table without producing sclerotic bony margins. They are formed because of an obstruction to the flow of CSF from the arachnoid granulations into the venous system and usually present late in life with local pain, swelling, seizures or neurological deficit (11).

Communicative type of hydrocephalus is usually associated with the pseudomeningocele and may be caused by intraventricular bleed at the time of the initial trauma. The treatment for this condition ranges from a simple ventriculo-peritoneal shunting to elaborate cranioplasty and dural repair.

Contributors: SM was involved in data collection and preparation of the manuscript. He will act as guarantor of the study. DA helped in manuscript writing.

Funding: Nil.

Competing interests: None stated.

REFERENCES

1. D'Almeida AC, King RB. Intradiploic cerebrospinal fluid fistula. Report of two cases. *J Neurosurg* 1981; 54: 84-88.
2. Dunkser SB, McCreary HS. Leptomeningeal cyst of the posterior fossa. *J Neurosurg* 1971; 34: 687-692.
3. Goel A, Desai KI, Nadkarni TD, Muzumdar DP. An unusual post-traumatic occipitocervical pseudomeningocele: case report. *Surg Neurol* 2001; 56: 62-65.
4. Halliday AL, Chapman PH, Heros RC. Leptomeningeal cyst resulting from adulthood trauma: case report. *Neurosurgery* 1990; 26: 150-153.
5. Kumar R, Verma A, Sharma K, Rathi B, Malik V. Post-traumatic pseudomeningocele of the orbit in a young child. *J Pediatr Ophthalmol Strabismus* 2003; 40: 110-112.
6. Macmillan AI, Bartlett RJ, Brocklehurst G. Intradiploic meningocele in a 16-year-old girl. *Br J Neurosurg* 1997; 11: 359-361.
7. Mahapatra AK, Tandon PN. Post-traumatic intradiploic pseudomeningocele in children. *Acta Neurochir (Wien)* 1989; 100: 120-126.
8. Martinez-Lage JF, Lopez F, Piqueras C, Poza M. Iatrogenic intradiploic meningoencephalocele. Case report. *J Neurosurg* 1997; 87: 468-471.
9. Natale M, Bocchetti A, Scuotto A, Rotondo M, Cioffi FA. Post traumatic retropharyngeal pseudomeningocele. *Acta Neurochir (Wien)* 2004; 146: 735-739.
10. Patil AA, Etemadrezaie H. Posttraumatic intradiploic meningoencephalocele. *J Neurosurg* 1996; 84: 284-287.
11. Tizzard S, Gleave J, Antoun N, Macfarlane R. Occipito-clival intradiploic meningocele following skull fracture in infancy. *Br J Neurosurg* 2001; 15: 188-190.
12. Turgut M, Ozcan OE, Karaman CZ. Post-traumatic intra-osseous pseudomeningocele of the occipital bone. *Australas Radiol* 1998; 42: 262-263.