follow up study. Indian Pediatr 1978, 15: 393-397..

5. Deshpande PG, Wagle SU, Mehta SD, Bharucha BA, Irani SF. Neonatal osteomyelitis and septic arthritis. Indian Pediatr 1990, 27: 453-457.

Fetus in Fetu

R. Samujh
K.L.N. Rao
N. Bhardwaj
S. Katariya

The term "fetus in fetu" was used by Meckel in 1800 to describe the presence of a fetus within a fetus. The fetus in fetu is a monochorionic, diamniotic, monozygotic twin of its bearer due to anastomosis of vitelline circulation.

Case Report

An 8-month-old boy presented with progressively increasing painless lump in the abdomen of 1 month duration. There were no bowel or bladder symptoms. The child was the last sibling in a family of 5. There was no history of twin pregnancy.

From the Departments of Pediatric Surgery, Anesthesiology and Radio-Diagnosis, Postgraduate Institute of Medical Education and Research, Chandigarh 160 012.

Reprint requests: Dr. K.L.N. Rao, Additional Professor and Head, Department of Pediatric Surgery, Post Graduate Institute of Medical Education and Research, Chandigarh 160 012.

Received for publication: May 26, 1992;
Accepted: September 10, 1992

On examination the infant appeared well nourished, healthy and weighed 6 kg. There were no signs of dehydration or anemia. The abdominal examination revealed a round, firm, nontender mass approximately 10 × 8 cm in size, slightly movable in the transverse direction, with smooth surface and well defined margins except its upper margin. Plain *X*-ray of the abdomen revealed a soft tissue shadow in the left upper quadrant with long bones and an area of calcification. No vertebral column could, however, be seen. Intravenous urography revealed normal renal excretory function of both sides. A clinical diagnosis of retroperitoneal teratoma was made. At laparotomy, the mass was found retroperitonealy below the pancreas and anteromedial to the left kidney. The mass was well encapsulated and could be enucleated. The arterial supply to the mass was by a branch from the superior mesenteric artery and also posteriorly by tiny branches arising directly from the aorta. A large vein drained into the left renal vein from the tumor. The left adrenal was compressed. The left kidney was compressed superiorly by the tumor.

The tumor weighed 500 g. It was found to have an intact greyish brown thick fibrous sac with a fetus inside it (*Fig.*). The fetus was attached to the sac by an umbilical cord. The upper limb length was 13 cm, whereas the lower limbs were fused. The foot length was 2.5 cm with well developed nails. Fine lanugo hair were present over the head. The abdominal cavity contained intestinal loops.

Discussion

The "fetus in fetu" is defined as a vertebrate fetus included within the abdomen of its partner(1). A review of literature showed only 30 cases being reported dur-

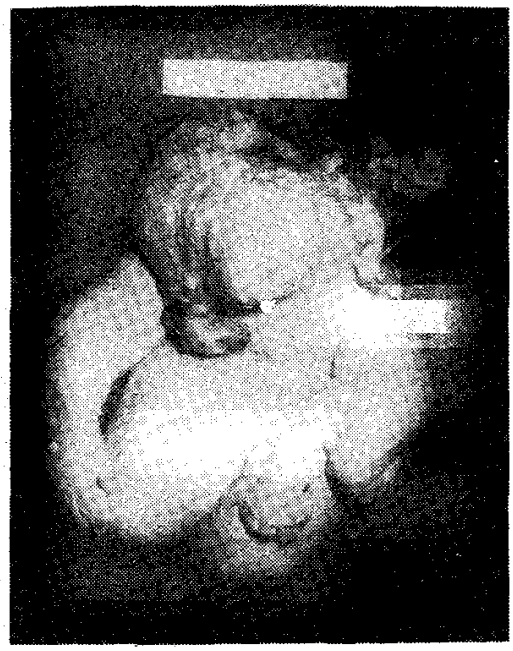

Fig. Specimen photograph showing a well formed fetus with head, and limb formation and umbilical cord attachment.

ing this century(2). Practically all the reported cases of fetus in fetu were noted in the first 12 months of life, usually in early infancy.

Fetus in fetus is discovered as an intra-abdominal mass, situated in the upper part of the retroperitoneal space. Less common sites are cranial cavity, pelvis, scrotal sac, sacrococcygeal(3), mesentery and right iliac fossa. Generally, only one fetus is found although occasionally multiple fetuses have been reported(4). Fetus in fetu is surrounded by a membrane that is analogous to the amniotic sac and characterized by a single feeding vessel and the absence of a true placenta. The fetus in fetu commencing existence as a true twin, grows initially in parallel with its fellow. soon, however, because of either vascular dominance of the host twin or some inherent defect in its parasitic partner, it lags behind its host.

The presence of a vertebral axis (having passed through a primitive streak stage) and an appropriate arrangement of other organs or limbs with respect to the axis was adopted as a criterion to distinguish fetus in fetu from teratoma. A teratoma is a true neoplasm arising from embryonic totipotential cells with benign or malignant properties. Teratomas lack a vertebral column (not having passed through a primitive streak stage).

Although the specimen in this case did not contain any vertebral bodies of a normal fetus, it was thoroughly covered with skin having hair follicles and sweat glands and it had well developed limbs with nails, well formed long bones with marrow, abdominal cavity with intestinal loops and pancreatic tissue, thoracic cavity with well developed respiratory lining with mucus glands. The presence of a well developed amniotic sac and umbilical cord structures leaves no doubt the entity being a fetus in fetu. We believe that these two features also should be given due importance in differentiating teratomas from fetus in fetu. It is true that tumors with definite axiation resemble fetuses more than tumors without vertebral organization but a clear diffrentiation cannot be established under all circumstances, as is well illustrated by the five fetuses found in the brain of a hydrocephalic infant by Kimmel *et al.*(4). Although two of the fetuses had well defined spinal rudiments, three did not. This illustrates the dilemma of those who believe that the presence of an axial skeleton is the decisive criterion in the differentiation between fetus in fetu and teratoma. That this is a rather arbitrary delineation is also illustrated by a case of intracranial teratoma found in brain of a stillborn infant(5). There was no vertebrae in the tumor, but well formed primitive spinal cord with

central canal was seen in every section and it was questioned whether a spinal cord was less representative of "axiation" than a vertebral column.

REFERENCES

1. Willis RA. The structure of a teratoma. J Pathol Bacteriol 1935: 1-14.
2. Martinez-Urrutia MJ, Pereira PL, Lassaletta L, *et al.* Abdominal mass: "Fetus in fetu". Acta Pediatr Scand 1990, 79: 121-122.
3. Narasimha Rao KL, Mitra SK, Pathak IC. Sacrococcygeal fetus in fetu. Indian Pediatr 1984, 21: 820-822.
4. Kimmel DL, Moyer EK, Peale AP, *et al.* A cerebral tumor containing five human fetuses: A case of fetus in fetus. Anat Rec 1950, 106: 141-158.
5. Warkany J. Congenital Malformations. Chicago, Year Book Medical, 1971, pp 1244-1245.

Intradiploic Hemangioma of Skull Bone

S. Kumar
S. Gupta
V. Puri
M.M. Mehndiratta
V. Malhotra

Primary hemangiomas of the skull are rare cranial tumors(1). Wyke(1) reported its incidence to be 0.7% of all osseous neoplasms and 10% of primary benign neoplasms of skull are hemangiomas. Usually these tumors present in the 4th and 5th decade. Because of its extreme rarity in children especially in females with particular affinity for frontoparietal region, the present case is being reported.

Case Report

An 11-year-old female child was admitted to hospital with a slowly increasing painless swelling in the right parietal region with occasional headaches of 5 months. In the past she had been having cyanotic spells since the age of 2 years.

On examination, the child was cyanosed and had clubbing of nails. Nervous system appeared normal but on auscultation of heart there was a continuous apical murmur and P2 was loud. Local examination of scalp revealed a bony hard swelling of 3 cm diameter in the right parietal region which was non tender diffuse and the overlying skin was freely mobile.

Investigations revealed a Hb of 17.5 g/dl while TLC, DLC, ESR and blood chemistry were normal. Plain *X*-ray skull revealed a well circumscribed area of rarefaction with a honeycomb pattern. Plain computed tomography bone window revealed biconvex expansion of diploic space by mixed density mass with bony spicules (*Fig. 1a*).

The lesion enhanced uniformly on contrast administration (*Fig. 1b*). Electrocardiography showed right atrial enlargement, small r/s pattern from lead V1 to

From the Departments of Neurosurgery, Radiology, Neurology and Pathology, G.B. Pant Hospital, New Delhi 110 002.

Reprint requests: Dr. Sushil Kumar, Professor, Department of Neurosurgery, G.B. Pant Hospital, New Delhi 110 002.

Received for publication: August 12, 1992; Accepted: November 12, 1992