number of hospital visits did not affect the number of correct responses. This was probably result of busy clinics and less time spent per patient on every subsequent visit. Moreover on subsequent visits, once the diagnosis has been established the doctor as well the parent is concerned about the concurrent illness.

Although medical personnel are often aware that particular attention is given to the parents who are at socioeconomic disadvantage in terms of better communication, other groups which require extra help are mothers with advanced age and those with more children. A cross check on mothers' understanding is recommended so that gaps in knowledge can be mended.

REFERENCES

1. Ferencz C, Weigmann FL, Dunning RE. Medical knowledge of young persons with heart disease. J School Health 1980, 50: 133-136.
2. Kaden G, McCarter RJ, Johnson SF, Ferencz C. Physician patient communication. Am J Dis Child 1985, 139: 995-999.
3. Kupst MJ, Blatterbauer S, Westman J, Schulman JL, Paul MH. Helping parents cope with the diagnosis of congenital heart defect. Pediatrics 1977, 59: 266-272.
4. Simon T, Karpati P, Hollo J. What do parents know about the congenital disease of their children. Health News 1966, pp 107-109.
5. Mattsson A. Long-term physical illness in childhood: A challenge to psychosocial adaptation. Pediatrics 1972, 50: 801-811.
6. Ley P, Spelman MS. Communications in an outpatient setting. Brit J Soc Clin Psychol 1965, 4: 114-116.

Spontaneous Regression of Bilateral Retrobulbar Masses in a Newborn —? Neuroblastoma

R. Dalvi
N. Birewar
M.R. Lokeshwar
A.R. Fernandez

Retrobulbar orbital lesions are uncommon in the newborn. Their etiology includes hemorrhages, vascular malformations, dermoids, teratomata, orbital encephaloceles, tuberculous granulomas, abscesses, and tumors like neuroblastoma, neurofibroma and rhabdomyosarcoma(1). Bilateral lesions, however, are extremely rare(1). A neonate with bilateral retrobulbar masses and a probable diagnosis of neuroblastoma is reported.

Case Report

A male child weighing 3.1 kg, born at full term of an uneventful vaginal delivery, was noted to have bilateral proptosis at birth. Examination revealed extensive subconjunctival hemorrhages, chemosis, semidilated sluggish pupils and incomplete lid closure bilaterally. Ocular fundoscopy and systemic examination were normal. The clinical impression was bilateral

From the Division of Neonatology, Department of Pediatrics, LTMG Hospital and LTM Medical College, Sion, Bombay-400 022.

Reprint requests: Dr. A.R. Fernandez, 53, Sea Springs, Bandstand, Bandra, Bombay-400 050.

Received for publication June 8, 1990; Accepted October 11, 1990

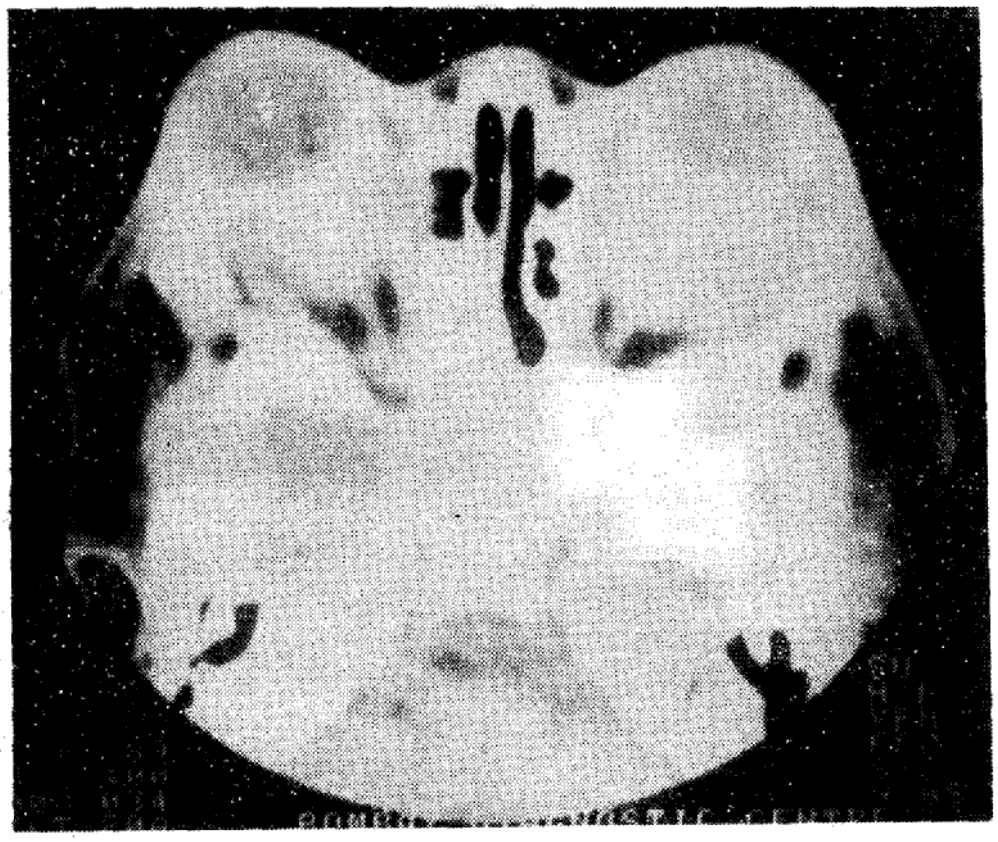

Fig. 1a. Computerised tomographic (CT) scan of the orbits showing bilateral retrobulbar masses.

retrobulbar hemorrhage. Investigations revealed, hemoglobin 17 g/dl, total leucocyte count 6400/cu mm, platelet count 2.7 lacs/cu mm, prothrombin time 19 sec (19 sec control) and partial thromboplastin times 50 sec (48 sec control). Ultrasonographic (USG) orbital scan showed well-defined hypo-echoic areas located posterolaterally and superiorly in the retrobulbar spaces bilaterally. The lesions measured 2.2 cm (anteroposterior diameter) × 2.1 cm (transverse diameter) and 2.1 cm × 2.2 cm in the right and left eyes, respectively. Ocular structures were normal. Computerised tomography of the brain and orbits similarly revealed bilateral contrast-enhancing lesions with a density suggestive of soft tissue masses, with a normal ventricular system and no evidence of intracranial pathology (*Figs. 1a & 1b*). There was no history or evidence of tuberculosis in the mother. Bone marrow examination showed no evi-

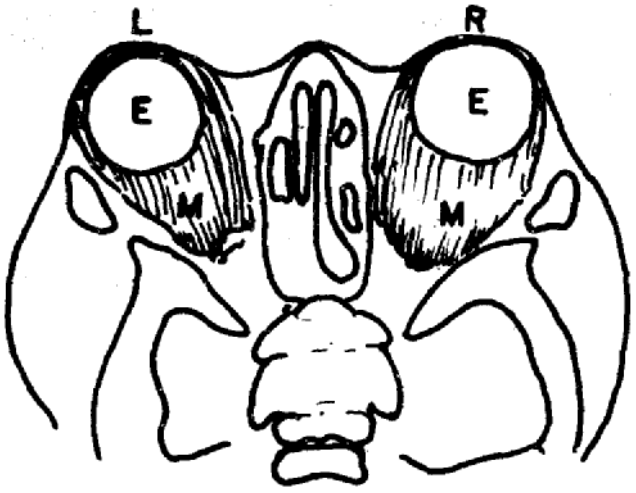

Fig. 1b. Illustration of CT scan of orbits. L = Left eye, R = right eye, E = ocular structures, M = retrobulbar masses.

dence of malignant cells. Ultrasonogram of the abdomen and roentgenographic skeletal survey were normal. Renal biochemistry and liver function tests were normal. A 24-hour urine sample on day 10 of life showed elevated venyl mandelic acid (VMA) levels of 23.8 μg/mg creatinine (Cr) with a laboratory normal of 1-10 μg/mg Cr. At about the same time the proptosis was noted to be decreasing and by 3 weeks of age the ophthalmologic features mentioned earlier had disappeared. Orbital USG, repeated at 4 weeks showed no evidence of hypoechoic lesions in the retrobulbar space. Twenty four hour urinary VMA levels tested at 6 weeks and 6 months of age were 11 μg/mg Cr and 5.5 μg/mg Cr, respectively. The baby has been followed up till 9 months of age and is clinically normal.

Discussion

Congenital neuroblastoma accounts for almost 50% of malignancies in the neonate(2) and is known to manifest with skin deposits, liver metastasis, intra or para-spinal masses or placental metastases. Presentation with solitary orbital metastasis at birth has not been reported. It is speculated that the undifferentiated neuroblast cells seen upto 16-18 weeks of gestation, are the origin of neuroblastomas, manifesting in the neonatal period or infancy(3,4).

A specific diagnosis of neuroblastoma can be made by histopathology of tumor tissue and measurement of urinary excretion of catecholamine metabolites. Elevated urinary VMA levels seen in 95% of patients with neural crest tumors is the most constant biochemical aberration associated with neuroblastomas(5). In the present case, the critical location of the masses did not permit tissue diagnosis, however, the 24-hour urine VMA levels were elevated. The VMA excretion in the urine of normal neonates is reported to be 0.5-12 μg/mg Cr(5) and false positives are generally seen in older children(5).

The variability of clinical course in patients with neuroblastoma(4) and biologic differences in the tumor seen on oncogene amplification(6) and nuclear magnetic resonance spectroscopy(7) have shown Stages I and IV-S of the disease (Evans classification)(8), to be the least aggressive forms. It is also well known that neuroblastoma has the highest rate of spontaneous remission described in malignant neoplasms(9). This is known to occur only in patients with stage IV-S disease, and it is suggested that in such cases instead of therapy, only close observation is warranted, unless life threatening complications occur(4). The presence of orbital metastasis however, conventionally puts the disease into Stage IV where spontaneous remisson is not described.

There may be one plausible explanation in this case. It has been suggested that patients with Stage IV-S neuroblastoma do not have metastases, but they harbour widely disseminated, multiple primary tumors, arising from different foci of neural crest cells(10,11). These are termed as "Neurocristopathies". It is, therefore, possible that the orbital masses in our patient were neurocristopathies, with biological characteristics of Stage IV-S disease.

In conclusion this was a newborn, with bilateral retrobulbar soft tissue masses occuring in association with elevated urinary VMA levels, with subsequent regression coincident with a fall in VMA levels, which is highly suggestive of a neuroblastoma.

REFERENCES

1. Behrman RE, Neonatology: Diseases of

the Fetus and the Infant. St Louis, CV Mosby Company, 1973, pp 626-629.

2. Gale GB, D'Angio GJ, Uri A, *et al.* Cancer in neonates, the experience at the Children's Hospital of Philadelphia. Pediatrics 1982, 70: 409-413.

3. Ikeda Y, Lister J, Bouton JM, Buyukpamukcu M. Congenital neuroblastoma, neuroblastoma *in situ* and the normal fetal development of the adrenal. J Pediatr Surg 1981, 16: 636-644.

4. Finklestein JZ. Neuroblastoma: The challenge and the frustration. Hematol Oncol Clin N Amer 1987, 1: 675-696.

5. Gitlow SE, Bertam LM, Rausen A, *et al.* Diagnosis of neuroblastoma by qualitative and quantitative determination of catecholamine metabolites in urine. Cancer 1970, 25: 1377-1384.

6. Seeger RC, Brodeur GM, Sather H, *et al.* Association of multiple copies of N-myconcogene with rapid progression of neuroblastomas. N Engl J Med 1985, 313: 1111-1116.

7. Maris JM, Evans EA, McLaughlin AC, *et al.* 31-P nuclear magnetic resonance spectroscopic investigation of human neuroblastoma *in situ*. N Engl J Med 1985, 312: 1500-1505.

8. Evans AE. Staging and treatment of neuroblastoma. Cancer 1980, 45: 1799-1802.

9. Everson TC, Cole WH. Spontaneous Regression of Cancer. Philadelphia, WB Saunders Co, 1966, pp 18-163.

10. Knudson AG, Meadow AT. Regression of neuroblastoma IV-S: A genetic hypothesis. N Engl J Med 1980, 302: 1254-1259.

11. Evans AE, Chatton J, D'Angio GJ, *et al.* A review of 17-IV-S neuroblastoma patients at the Children's Hospital of Philadelphia. Cancer 1980, 45: 833-839.

A Translocation Between Chromosome 1 and 10 in a Boy with Mental Retardation and Dysmorphic Features

P.S. Gambhir
L.A. Gole
M.V. Tembe
A.A. Saraph
M.A. Phadke
V.A. Khedkar

This report describes a boy with delayed physical and mental milestones, dysmorphic features, congenital anomalies of the feet and convulsions. He was found to have translocation between long arms of 1st and 10th chromosome. Such a 1:10 translocation with phenotypic consequences has not been reported in Indian literature so far.

Case Report

A two-year-old proband was a product of Grade I consanguinous marriage between healthy young first cousins. The antenatal period was uneventful and the child was delivered normally. Abnormalities of both feet were noted at the time of birth. The child was referred to us for convulsions; generalised tonic and clonic, off and on for one year. History revealed that mental and physical milestones were delayed even before the onset of convulsions.

From the Department of Pediatrics, BJ Medical College, Pune.

Received for publication May 25, 1989; Accepted December 10, 1990