

Ventricular Ectopic Beats in a Child Receiving Carbamazepine

Hematopoietic, hepatic and dermatological toxicity of Carbamazepine is well-known, but cardiac side-effects are not that widely recognized. Its use has rarely been reported to cause conduction abnormalities, predominantly in elderly women, with therapeutic (or moderately elevated) plasma concentrations of the drug [1]. We herein report a child with syncopal attacks following carbamazepine use.

An 8-year-old child presented with history of fainting attacks while playing, which lasted for a few seconds, followed by spontaneous recovery. He had two such witnessed episodes in the preceding week, which prompted the present consultation. He was developing normally, studied in class III, and never had any previous episodes of dizziness, syncope, breathlessness or cyanosis. He did not report any other associated cardiac symptoms. He was on regular treatment with carbamazepine (15 mg/kg/d) for Idiopathic generalized epilepsy from another institution since past one year, with no non-compliance, or missing a dose in the last 24-hours. Contrast-enhanced CT head done at that time was normal.

On detailed history, these episodes of fainting did not resemble the seizures that he had experienced in the past, and during this episode he did not have any other neurologic symptoms. The fainting attacks were transient and the child recovered immediately after the fall. On examination, the patient was alert and cooperative with blood pressure of 98/76 mmHg. He was noted to have an irregularly irregular pulse, and ectopic heart beats after every 8 to 10 beats, with a heart rate of 70 to 80 beats per minute. A 12-lead electrocardiogram showed ventricular premature beats (**Fig. 1**). Child was admitted and started on tablet atenolol, 25 mg daily. An echocardiogram ruled out structural heart disease. Holter monitoring for 24 hours

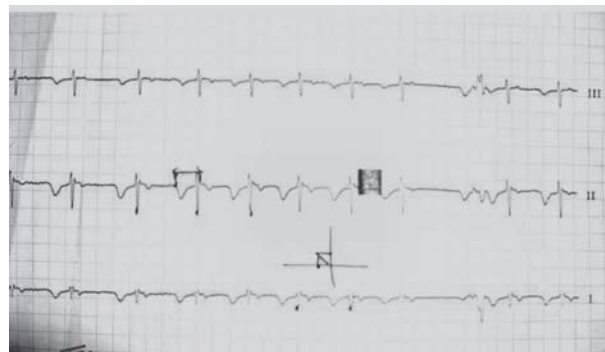


FIG. 1 Ventricular premature beats seen in the child's electrocardiogram on admission.

showed frequent ventricular ectopic beats though the child did not have further fainting episodes during the hospital stay.

In the background of reports of carbamazepine causing conduction disturbances, it was replaced with tablet valproate 15 mg/kg/day. Atenolol was stopped. Serum carbamazepine level six hour after the last dose of the drug was 10.6 µg/mL (therapeutic range 8-12 µg/mL). The patient was discharged on day 5, after documenting a normal ECG. Repeat holter study at 3 months of follow-up, did not show any abnormality. On follow-up at one year, he was asymptomatic without any complaints of fainting attacks or giddiness.

Carbamazepine exerts its effect by acting as a sodium channel blocker, and is known to produce negative chronotropic and dromotropic effects on the heart; thus, it may sometimes lead to conduction disturbances, including Sinus bradycardias, sinus pauses, junctional bradycardias, and AV blocks, ranging from first degree to complete [2]. A recent review of these reports showed that elderly women, particularly those with a pre-existing conduction abnormality, were mostly involved [1], though reports in young also exist. Usually brady-arrhythmias occur at therapeutic doses, whereas sinus tachycardia is the main arrhythmia in massive CBZ overdose [3]. An increase in ventricular premature beats over next five days has also been reported in patients who abruptly discontinued CBZ because of cardiac side-effects [4]. Our patient, however, did not have any history of discontinuation of the drug prior to presentation. Another possibility could have been arrhythmia-related seizures [5]; however, there was no recurrence of the ECG abnormality after stopping carbamazepine. Using the Naranjo Adverse Drug Reaction Probability Scale classified the event as a 'possible' adverse drug reaction.

We wish to highlight that cardiac side-effects may sometimes occur after prolonged carbamazepine therapy, and may be associated with normal or slightly high serum levels. As seen in this child, rapid resolution of symptoms occurs on discontinuing the drug.

Acknowledgement: Dr Priyanka Solanki, Department of Pediatrics, Lok Nayak Hospital; and Dr. Sanjiv Kathuria DM, Department of Cardiology, GB Pant Hospital.

DEVENDRA MISHRA AND MONICA JUNEJA

*Department of Pediatrics,
Lok Nayak Hospital, Maulana Azad Medical College,
New Delhi, India.
drdmishra@gmail.com*

REFERENCES

1. Hewetson KA, Ritch AE, Watson RD. Sick sinus syndrome

- aggravated by carbamazepine therapy for epilepsy. *Postgrad Med J.* 1986;62:497-8.
- Tomson T, Kenneback G. Arrhythmia, heart rate variability, and antiepileptic drugs. *Epilepsia.* 1997; 38:S48-51.
 - Kasarskis EJ, Berger R, Nelson KR. Carbamazepine-induced cardiac dysfunction. Characterization of two distinct syndromes. *Arch Intern Med.* 1992;152:186-91.

- Kennebäck G, Ericson M, Tomson T, Bergfeldt L. Changes in arrhythmia profile and heart rate variability during abrupt withdrawal of antiepileptic drugs. Implications for sudden death. *Seizure.* 1997;6:369-75.
- Venugopalan P, Al-Anquodi ZA, Al-Maamari WS. A child with supraventricular tachycardia and convulsions. *Ann Trop Paediatr.* 2003;23:79-82.

Management of Severe Scorpion Sting at a Rural Hospital

Severe scorpion sting is a life threatening accident not uncommon in Western Maharashtra [1]. Scorpion venom delays closing of sodium neuronal channel resulting in liberation of endogenous catecholamines into circulation, manifesting as “autonomic storm” [2]. In the past, upto 30% fatality due to refractory heart failure due to *Mesobuthus tamulus* envenoming has been reported. Since the advent of prazosin, a postsynaptic alpha blocker, the fatality due to refractory heart failure has reduced to less than 4-8% in pediatric age group [3].

Cottage Hospital is a public health institute situated on Mumbai-Goa highway. The mono specific scorpion antivenom against the *Mesobuthaus tumulus* is prepared at Haffkine Institute, Mumbai has been available at our Institution since 2010. We retrospectively analyzed details of 12 children who suffered autonomic storm due to scorpion sting (**Table I**). Of these, six (2 males) had received scorpion antivenom plus prazosin and the remaining (3 males) received only scorpion antivenom. All gave history of scorpion sting and relatives brought the killed specimen.

Alpha receptor stimulation plays important role in the pathogenesis of acute pulmonary edema. Prazosin, by blocking alpha receptors corrects the abnormal hemodynamic, and metabolic effects of circulating catecholamines [3,4]. Patients treated with prazosin alone are reported to recover in 10-24 hours, till the venom is metabolized by body. In such situation victims needs close monitoring in intensive care [8]. 10-20% of children, irrespective of oral prazosin, were found to develop tachycardia, hypotension and pulmonary edema [8]. Scorpion antivenom neutralizes the circulating venom and it has no action in reverseing the effects of already raised catecholamine and tissue-bound venom

TABLE I CHARACTERISTICS OF CHILDREN WITH AUTONOMIC STORM (N=12)

Treatment	Anti-scorpion venom (AScV)	AScV + Prazosin
Age (y)	9 (7-12)	8.8 (3-13)
Time between sting to hospitalization (hours)	2.41 (1-3.5)	1.5 (1-2.5)
Blood pressure (mm Hg)		
Systolic	140 (80-190)	123 (90-170)
Diastolic	80 (60-100)	80 (70-100)
Pulse rate (per min.)	89 (68-110)	89 (84-100)
AScV dose* ((1.2)vial)	2.33 ((2-5)vial)	1.33
Pulmonary edema	3	0
Recovery	3	6
Time for recovery (h)	7.1 (4-8)	3.75 (2-5)

*1 vial=10 mL; Values in mean (range); AScv-Anti-Scorpion venom.

[5]. Cold extremities occur due to alpha receptor stimulation as a result of vasoconstriction, and delay the venom absorption in circulation from site of sting, which acts as depot. Simultaneous use of oral prazosin, which antagonizes the catecholamine actions and improves the peripheral circulation and rapid absorption of venom in circulation that becomes accessible to already circulating antivenom, thus recovery is shortened in prazosin pluse antivenom group as compared to scorpion anti venom group alone [5]. Rapid recovery of victims treated with prazosin and antivenom prevent the extra load of these cases to intensive care unit, which is beyond the reach of poor people.

SANTOSH GOVIND RATHOD AND SEJAL BHANUDAS TAMBAT
Cottage Hospital Mangaon, Morba Road, Dist. Raigad,
Maharashtra 402 104, India.
Drsgrathod2007@gmail.com

REFERENCES

- Santhannakrishnan BR, Ranganathan G, Anaantha-