

Holoprosencephaly: A Guide to Diagnosis and Clinical Management

MANU S RAAM,[†] BENJAMIN D SOLOMON AND MAXIMILIAN MUENKE

From Medical Genetics Branch, National Human Genome Research Institute, National Institutes of Health, Bethesda, MD, United States; and [†]HHMI-NIH Research Scholars Program, Howard Hughes Medical Institute, Chevy Chase, MD, United States.

Correspondence to: Maximilian Muenke, Building 35, Room 1B-203, 35 Convent Drive MSC 3717, Bethesda, MD 20892-3717, United States. mamuenke@mail.nih.gov

Context: Holoprosencephaly affects 1 in 8,000 live births and is the most common structural anomaly of the developing forebrain, resulting in facial dysmorphism, neurologic impairment, and additional clinical sequelae. Given the increasing relative contribution of genetic diseases to perinatal morbidity and mortality in India, proper recognition and management of holoprosencephaly can improve care for a significant number of affected Indian children.

Evidence Acquisition: We used the PubMed database (search terms: “holoprosencephaly,” “HPE,” “holoprosencephaly India”) and cross-referenced articles regarding holoprosencephaly, using our research group’s extensive experience as a guide for identifying seminal papers in the field.

Results: Holoprosencephaly is classified into four types based on the nature of the brain malformations as seen on neuroimaging and/or pathologic examination, with typically recognizable craniofacial phenotypes. Despite the identification of several genetic loci and other etiologic agents involved in pathogenesis, additional causes are elusive. Moreover, satisfactory explanations for phenomena such as incomplete penetrance and variable expressivity are lacking.

Conclusions: For each patient, pediatricians should follow a diagnostic protocol including dysmorphology examination, complete family history and ascertainment of risk factors, and neuroimaging. Many medical issues, including hypothalamic dysfunction, endocrinologic dysfunction, motor impairment, respiratory issues, seizures, and hydrocephalus should be prioritized in management. Pediatricians should work with genetic specialists to identify syndromic forms and to perform cytogenetic investigation, molecular screening, and genetic counseling in order to fully characterize prognosis and recurrence risk.

Key words: *Diagnosis, Genetics, Holoprosencephaly, Management, Review.*

Holoprosencephaly is the most common structural anomaly of the developing forebrain, resulting from incomplete midline cleavage of the prosencephalon and associated with neurologic impairment and dysmorphism of the brain and face. Studies in humans and animals suggest that the defects associated with holoprosencephaly occur at the human equivalent of approximately two to three weeks post-conception [1], indicating that holoprosencephaly is a disorder of gastrulation. Holoprosencephaly occurs rather frequently, having been observed in 1:250 conceptuses [2]; due to a high rate of fetal demise, the birth prevalence is 1:8000 live births [3]. As subsequently discussed in greater detail, India’s large population size, unique

population structure, and perinatal morbidity and mortality patterns indicate that proper recognition and management of congenital disorders like holoprosencephaly by pediatricians and medical geneticists can improve healthcare for a sizeable number of Indian children.

Our research group, located at the National Human Genome Research Institute (National Institutes of Health) in the United States, has extensive clinical and research experience with holoprosencephaly, and routinely works with patients and families affected by holoprosencephaly, as well as with blood samples sent to us from within and outside the US. In the following text, we aim to provide the practicing Indian pediatrician with

information regarding cardinal clinical and genetic concepts regarding holoprosencephaly, with a special emphasis on clinical management and molecular diagnostic options available to enhance care of Indian children with the condition.

EPIDEMIOLOGY AND IMPLICATIONS

Significant variation from the base prevalence of 1:8000 live births has not been observed among different international populations in several multicenter studies. In the United States, seemingly higher prevalences have been reported in Hispanic, African-American, and Pakistani ethnicities, likely attributable to decreased prenatal diagnosis and termination rates in these groups [4]. This situation may be extrapolated to other countries, including India; as in any population, variable levels of knowledge regarding holoprosencephaly and reduced access to prenatal healthcare in specific communities may lead to higher apparent prevalences and suboptimal clinical management.

There is a paucity of specific information regarding Indian patients with holoprosencephaly in the literature; the largest case series of Indian patients with holoprosencephaly consisted of 13 patients and was described in 2004 [5]. Nevertheless, the lack of such descriptions is not likely to be due to a reduced number of Indian patients with the condition. In fact, large family sizes and high rates of consanguineous marriages in India lead one to expect increased occurrence of certain genetic disorders [6], and the enormous Indian population size translates to a large number of infants (495,000 per year) who are affected by all genetic disorders [7]. Given the increasing relative contribution of genetic disease to perinatal morbidity and mortality [7], it is reasonable to expect that an Indian pediatrician in a large city would encounter and be required to significantly manage critically ill patients with holoprosencephaly.

CLASSIFICATION SCHEMA

Holoprosencephaly is classically divided into four types, based on the degree of nonseparation of the prosencephalon [8,9]. These types, in order of increasing cortical separation, include the alobar form, characterized by diffuse cortical nonseparation;

the semilobar form, characterized by nonseparation of the frontal lobes; the lobar form, characterized by nonseparation of the basal aspect of the frontal lobes; and the middle interhemispheric variant, characterized by nonseparation of the posterior frontal and parietal lobes [10] (**Fig. 1**). Additional nuances specific to each type are described in **Table I**. As further described in the section on clinical management, severity of craniofacial malformations and prognosis tend to correlate with the degree of nonseparation: the alobar form is the most severe in terms of both craniofacial malformations and neurologic impairment; the semilobar form is characterized by milder or absent craniofacial malformations, but persistence of severe motor abnormalities; and, the lobar and middle interhemispheric variant forms are comparatively mild, both in terms of craniofacial malformations and neurologic impairment [10]. Finally, very mildly affected “microforms” have been described, wherein individuals may display subtle craniofacial features including microcephaly, hypotelorism (closely spaced eyes), and single maxillary central incisor but typically do not demonstrate obvious radiologic evidence of nonseparation or severe neurologic impairment [11].

CRANIOFACIAL FINDINGS

In most but not all cases, craniofacial manifestations

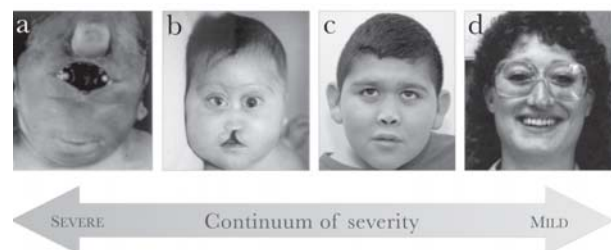


FIG. 2 Craniofacial phenotypes in patients with holoprosencephaly. From left to right: (a) synophthalmia and a proboscis in a patient with alobar holoprosencephaly; (b) severe hypotelorism, flat nasal bridge, bilateral colobomas, and midline cleft lip and palate in a patient with alobar holoprosencephaly; (c) hypotelorism, flat nasal bridge, and closely spaced nostrils in a patient with lobar holoprosencephaly; (d) hypotelorism, sharp nasal bridge, and single maxillary central incisor in an individual with a microform of holoprosencephaly.

(Adapted from [20] and [25] with permission from Nature Publishing Group and BMJ Publishing Group, Ltd., respectively.)

TABLE 1 DESCRIPTIONS OF TYPICAL BRAIN FINDINGS IN EACH OF THE TYPES OF HOLOPROSENCEPHALY

	Alobar	Semilobar	Lobar	MIHV*	Microform
<i>Interhemispheric separation</i>	Complete or near-complete nonseparation, with absent falx cerebri	No anterior separation, some posterior separation	Nonseparation of only the most rostral/ventral frontal neocortex, with hypoplastic falx cerebri	Nonseparation of posterior frontal and parietal lobes	No interhemispheric fusion
<i>Corpus callosal characteristics</i>	Absent corpus callosum	Absent anterior corpus callosum	Absent corpus callosum in affected region	Absent body of the corpus callosum	May have subtle defects
<i>Additional findings</i>	Absent olfactory bulbs, fused deep gray nuclei, and single midline monoventricle	Absent or hypoplastic olfactory bulbs, fused deep gray nuclei, and absent anterior horns of lateral ventricles and septum pellucidum	Hypoplastic olfactory bulbs, hypoplastic falx cerebri, and azygous anterior cerebral artery	Frequent fusion of thalami and caudate nuclei, Gray matter heterotopias, cortical dysplasia, and Azygous anterior cerebral artery	May have subtle midline brain defects

*MIHV: middle interhemispheric variant; Reproduced with permission from reference 10.

tend to follow DeMyer’s 1964 maxim, “the face predicts the brain” [12]. In other words, the severity of the craniofacial phenotype tends to mirror the severity of the brain malformations and correlates inversely with survival [13] (**Fig. 2**). The most severe facial phenotypes include pronounced microcephaly, cyclopia (single, centrally placed eye), synophthalmia (partial union of the two eyes in the center of the face), and a proboscis (a tube-like nasal appendage with a single nostril located above the ocular region) [13]. Less severe facial phenotypes can include microcephaly (except in cases of hydrocephalus, which can cause macrocephaly), hypotelorism, midface hypoplasia with a flat nasal bridge, cleft lip and/or palate, ocular colobomas, and a single maxillary central incisor [13]. Individuals with microforms of holoprosencephaly, usually identified as relatives of probands with frank holoprosencephaly, have isolated craniofacial findings without the classic clinical issues and neurologic impairment seen in holoprosencephaly [11,13]. Conversely, individuals with mutations in *ZIC2*, one of the genes implicated in select cases of holoprosencephaly, present an exception to the “face predicts the brain” maxim, as these patients have severe holoprosencephaly, neurologic impairment, and characteristic clinical sequelae, but have a much milder facial phenotype than that of other patients [13,14].

ETIOLOGY AND MOLECULAR GENETICS

The etiology of holoprosencephaly is extremely heterogeneous and is still being elucidated. With varying levels of evidence, a number of environmental factors and teratogens have been suggested, including maternal diabetes (infants born to diabetic mothers have a 200-fold risk of holoprosencephaly),

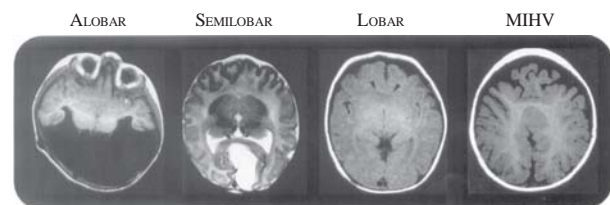


FIG 2. Axial sections through cranial MR images of patients with holoprosencephaly, distinguished by type. MIHV: middle interhemispheric variant. (Adapted from [32] with permission from Elsevier.)

ethanol, cytomegalovirus infection, salicylates, anti-epileptic medications, retinoic acid, and maternal hypocholesterolemia [15,16]. Genetic causes have also been implicated, based on familial occurrences of holoprosencephaly, the presence of known syndromes and associations including holoprosencephaly, and the nonrandom nature of chromosomal aberrations in patients with holoprosencephaly [16]. Between 18%-25% of live births affected by holoprosencephaly have a recognizable monogenic syndrome, including Smith-Lemli-Opitz syndrome (MIM #270400), Pallister-Hall syndrome (MIM #146510), and Rubinstein-Taybi syndrome (MIM #180849) [16]. Chromosomal anomalies have been implicated in 24-45% of live births affected by holoprosencephaly [16-18], most frequently numeric anomalies in chromosomes 13, 18, and 21 [19] and structural anomalies involving 13q, 18p, 7q36, 3p24-pter, 2p21, and 21q22.3 [16]. Intragenic mutations in four genes have also been firmly established as increasing susceptibility to holoprosencephaly: *SHH* (7q36) (20-22), *SIX3* (2p21) (23-25), *ZIC2* (13q32) (14, 26), and *TGIF* (18p11.3) [27]. While testing for mutations in these four genes has led to significant diagnostic advancements and implications for patient care, 75% of chromosomally normal patients with holoprosencephaly do not have identified mutations in any screened genes [28], indicating the need to identify additional susceptibility genes.

The genetics of holoprosencephaly are such that multiple affected individuals can present with holoprosencephaly within the same family, but incomplete penetrance and variable expressivity lead to tremendous intrafamilial phenotypic variability [29]. A related observation is that individuals with certain chromosomal aberrations and intragenic mutations associated with holoprosencephaly may not actually have holoprosencephaly in all cases: only 50% of patients with deletions in 7q36, including *SHH*, have holoprosencephaly, and only 10% with deletions in 18p, including *TGIF*, do so [30]. Thus, holoprosencephaly, like many other entities considered to be "simple" Mendelian disorders, is characterized by complex traits that are not reliably predicted by the presence of a single mutation [31].

DIAGNOSIS

A recommended protocol for clinical and molecular diagnosis in patients with holoprosencephaly is provided in *Fig. 3*. The diagnostic process is typically initiated by abnormal prenatal brain imaging, positive physical examination findings, and/or positive family history. Whenever possible, a thorough dysmorphology examination and an interview to determine risk factors and family history should be obtained. Ascertainment of the specific neurologic findings and holoprosencephaly type in each patient, via brain imaging, is essential to proper counseling of the patient and his/her family, given their effect on prognosis. MR (magnetic resonance) imaging provides the highest quality data for this purpose, allowing detailed analysis of cortical white matter and structural abnormalities of the deep gray nuclei [10], although logistic issues and the risks of the sedation required in neurologically impaired patients can make this impractical. If MR imaging cannot be performed, other options include ultrasound, which can be performed while the fontanelles are patent, and CT (computed tomography) imaging, which carries risks associated with radiation exposure. If a patient is found to have microcephaly, a large dorsal cyst, or rapidly enlarging head size, serial imaging is indicated [32].

Prenatally, providing an early date of diagnosis is important from both scientific and psychologic points of view, because the severity of malformations leads to emotional effects among family members and may include consideration of pregnancy termination [33,34]. Prenatal ultrasound of the face and falx cerebri can be used to diagnose lobar and semilobar holoprosencephaly as early as the first trimester [10,33], while fetal MRI provides more sensitive diagnosis for milder forms of holoprosencephaly during the third trimester [35]. Ultrasound remains the gold standard due to its relative imperviousness to maternal obesity, fetal position, bone reverberation, and oligohydramnios [34]. In a recent study comparing ultrasound-based diagnosis to postmortem autopsy findings, autopsy confirmed the prenatal diagnosis of holoprosencephaly in 17/21 cases, with two patients unable to receive a precise pathological diagnosis due to extensive severity of malformations, and two additional patients found to

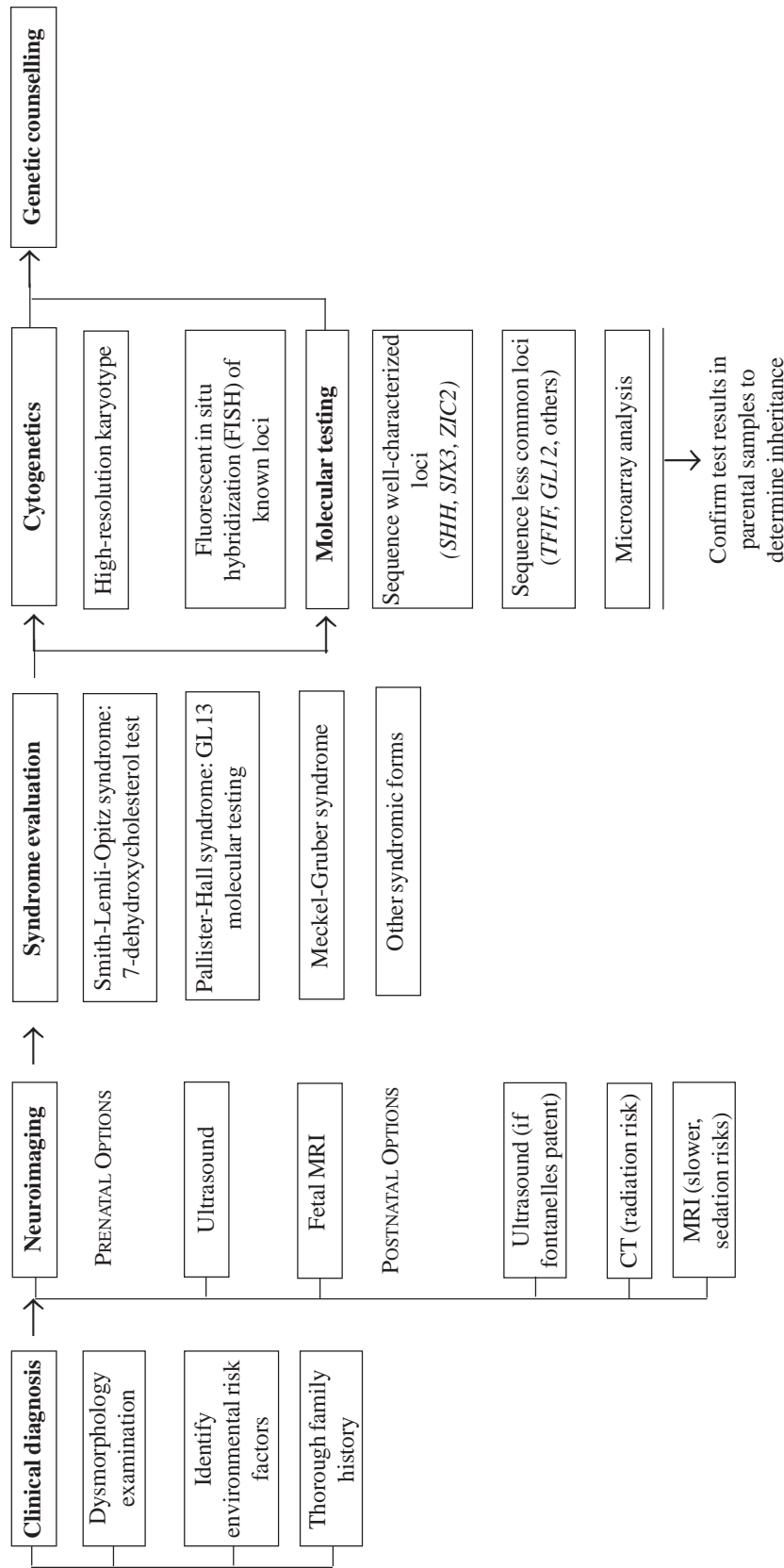


FIG 3 Recommended clinical protocol for diagnosing and elucidating causes of holoprosencephaly in patients. Each of the six major steps is medically indicated; within each step, bolded items are medically indicated or preferred, while others are performed if suggested by the clinical characteristics of the patient or at the discretion of the clinical laboratory. See text for more details.

have severe complex brain and facial malformations other than holoprosencephaly [34]. Ultrasound is not completely accurate in determining holoprosencephaly type: in 7/17 cases, the holoprosencephaly type determined through prenatal diagnosis differed from that determined via postmortem autopsy [34]. In families with an existing child with holoprosencephaly and an identified disease-causing mutation, prenatal molecular diagnosis is possible, although presence of the mutation does not necessarily portend holoprosencephaly [35].

PROGNOSIS

Survival rates vary in each type of holoprosencephaly, but in general, mortality correlates positively with the severity of the brain malformation and, by extension, severity of the facial phenotype [13]. Of children with alobar holoprosencephaly, those with severe facial anomalies such as cyclopia and proboscis rarely survive the immediate postnatal period, while those with less severe facial malformations can survive for months or, in a minority of cases, longer than one year [36]. In very rare instances, survival into the twenties has been observed (authors' own experience). In contrast to most children with alobar holoprosencephaly, children with holoprosencephaly types other than alobar may more often survive into adulthood [36]. Frequent causes of death include respiratory infections, dehydration secondary to uncontrolled diabetes insipidus, intractable seizures, and sequelae of brainstem malfunction, including aberrant control of respiration and heart rate [36].

As with survival, developmental outcomes generally correlate with the severity of the brain malformation, although again, tremendous variability can occur. Children with alobar holoprosencephaly may develop to a stage equivalent to that of a healthy, early infant: while they may track objects or sounds, they typically cannot speak words, sit without assistance, or reach for objects [37]. In contrast, some children with semilobar holoprosencephaly can develop receptive language skills, and while speech is still frequently impaired, they can communicate through eye movements, gestures, or other non-verbal communication systems, and may be socially engaging [37]. The severe motor

impairment observed in alobar and semilobar holoprosencephaly is less frequently seen in the lobar type and the middle interhemispheric variant; patients with the latter forms may walk with assistance, adequately control their limbs, and even speak words or sentences [37]. The enhanced vocal communication in these patients may be explained by more complete separation of the deep gray nuclei, but because separation of the deep gray nuclei does not appear to correlate with social awareness, visual attention, and auditory comprehension, differences in those constructs may be caused by structural changes in different regions [38]. The Carter Neurocognitive Assessment (CNA) may be useful to clinicians for assessing cognitive function in children with more severe impairment [38].

CLINICAL MANAGEMENT

Due to the medial and rostral location of the hypothalamus, nonseparation of the hypothalamus occurs frequently, leading to a variety of issues involving homeostatic and hypothalamic-pituitary endocrine functions [39]. One disturbed homeostatic function is body temperature regulation, which is significant for two reasons: first, ascertainment of baseline body temperature helps identify abnormal deviations in temperature due to infections or other causes of morbidity; second, temperature instability in itself can cause morbidity and organ dysfunction if the core temperature falls below 34°C or rises above 40°C [37]. Other impaired homeostatic functions include thirst, appetite, and sleep-wake cycles, disturbances of all of which can pose significant problems for caregivers [37].

From an endocrinologic perspective, dysfunction of the posterior pituitary, in the form of central diabetes insipidus, is much more commonly observed than anterior pituitary insufficiency [39,40], typically manifesting with polyuria, dehydration, hypernatremia, and decreased urine osmolality [40]. The severity of diabetes insipidus generally correlates with the degree of hypothalamic nonseparation but not with pituitary gland defects observed via imaging [40]. Due to the high incidence of posterior pituitary dysfunction, and because diabetes insipidus in these patients may be asymptomatic, routine screening of electrolyte levels for evidence

of posterior pituitary endocrinopathies is recommended in all patients, with repeated testing even in the event of an initial negative result and also in the acute setting [37,40]. Anterior pituitary issues, occurring with lower frequency than posterior pituitary issues, include hypothyroidism, hypocortisolism, growth hormone deficiency, and multiple pituitary hormone deficiency [40]. As signs of hypothyroidism and hypocortisolism can be difficult to distinguish from those seen classically in holoprosencephaly, and because the effects of those endocrinologic deficiencies can be life-threatening, we recommend basic screening evaluations in all patients, but with in-depth stimulation tests only if clinical suspicion is high.

Motor impairment in holoprosencephaly generally manifests as hypotonia, dystonia, and/or spasticity, frequently requiring pharmaceutical interventions such as intrathecal baclofen pumps and oral trihexyphenidyl, as well as physical and occupational therapy and surgical interventions [37]. One of the most detrimental effects of motor impairment is oromotor dysfunction, which significantly compounds the thirst and appetite disturbances resulting from hypothalamic dysfunction, and may also exacerbate unique feeding challenges secondary to cleft lip and palate [37]. Children with such issues frequently develop oropharyngeal dysphagia and respiratory symptoms related to aspiration and difficulty managing secretions, compromising oral intake and increasing the risk of respiratory infections. Additional respiratory issues can include chronic lung disease with decreased pulmonary reserve and chronic inflammation. A gastrostomy tube is placed in many children with oromotor dysfunction to address these issues. Gastrointestinal issues related to poor nervous regulation, including poor gastric and colonic motility and gastroesophageal reflux, can still impair feeding despite placement of a gastrostomy tube, sometimes indicating medications and anti-reflux procedures [37].

Finally, the nature of the brain malformation may predispose patients to seizures and/or hydrocephalus. Seizures occur in approximately half of the patients [39], most commonly complex partial seizures, and typically develop during infancy [37]. In addition, "epileptiform" activity has been noted

on electroencephalograms (EEGs) of some patients without overt clinical seizures [41], suggesting that routine EEG screening of patients may be useful. Of patients with recurring seizures, most are managed with one or two antiepileptic medications; intractable seizures occur in one-third to one-half, typically in patients with more severe cortical malformations [37,39]. As seizure triggers can include fluid and electrolyte imbalances from diabetes insipidus, proper management of seizures requires consideration of endocrinologic issues [37]. Hydrocephalus is another common finding that depends on the specific brain malformation, correlating highly with thalamic nonseparation and the presence of a dorsal cyst; it is thought to result from blocked cerebrospinal fluid egress from the third ventricle [42]. Because holoprosencephaly typically results in microcephaly, hydrocephalus should be suspected in patients with normal head sizes or macrocephaly and followed using serial head circumference measurements and ultrasound imaging [37]. Placing a cerebrospinal fluid shunt, while taking particular care to avoid overdrainage, can improve developmental outcomes, improve other issues, and reduce macrocephaly [37].

Thus, diverse clinical sequelae can result from a primary insult of holoprosencephaly. Clinicians should have a low threshold for testing for these sequelae, as specific abnormalities are difficult to predict in advance and may be challenging to diagnose.

FURTHER STEPS TO ELABORATE GENETIC CAUSES AND INHERITANCE

Indian pediatricians are well-equipped to clinically diagnose holoprosencephaly and to manage the clinical sequelae of the condition, but full benefit to the patient and his/her family cannot be achieved without genetic investigation. We recognize that there are many barriers to the consistent application of genetic testing and interpretation to each Indian patient with holoprosencephaly, as the current state of medical genetics in India leaves many clinicians without formal training in genetics and easy access to affordable genetic testing laboratories [43]. Nevertheless, for a proper discussion with the family regarding etiology and recurrence risk, pediatricians

KEY MESSAGES

- Holoprosencephaly is characterized by failure of the prosencephalon to divide into complete hemispheres, and is associated with facial dysmorphism and neurologic impairment.
- Essential components of diagnosis include a thorough interview to determine family history and teratogenic exposures, dysmorphology exam, and neuroimaging, which is critical for prognosis determination.
- Medical management should focus on hypothalamic and endocrinologic dysfunction, motor and developmental impairment, respiratory issues, seizures, and hydrocephalus.
- Pediatricians should follow up medical management by collaborating with a genetic specialist, with the aim of performing genetic testing, determination of associated syndromes, and genetic counseling.

should seek out genetic specialists within or outside India who are familiar with holoprosencephaly and discuss the feasibility of genetic testing with them. Here, we briefly discuss what is needed so that the pediatrician may be familiar with the process.

As previously mentioned, holoprosencephaly frequently occurs as part of a syndrome, and additional diagnostic steps should be undertaken if the patient is clinically suspected to be affected by one of these syndromes. For instance, patients suspected to have Smith-Lemli-Opitz syndrome should have total cholesterol and 7-dehydroxycholesterol levels checked for a decrease and an increase outside the normal range, respectively [44].

To determine genetic causes of holoprosencephaly in each patient, a combination of cytogenetic and molecular testing is recommended. Due to the high incidence of chromosomal anomalies, a high-resolution karyotype at the 550 band level or greater is indicated in all patients. Direct DNA sequencing of *SHH*, *ZIC2*, and *SIX3* is also indicated, due to the high prevalence of intragenic mutations in those genes [45]. DNA sequencing results should be compared to analyses of biologic effects and results of functional studies [22,24] for each potential mutation, which are essential to help determine the true pathogenic import of each variant. Routine sequencing of minor loci is not performed unless indicated by specific observations in a patient: for instance, pituitary abnormalities in a patient with holoprosencephaly may warrant molecular testing of *GLI2* [45] due to an emerging genotype/phenotype correlation [13]. Microarray analysis, including array-based comparative genomic hybridization

(array CGH, or aCGH) and single nucleotide polymorphism (SNP) arrays, is a relatively new molecular technique that allows for identification of deletions and duplications at resolutions far exceeding that of a karyotype, but currently, the novelty of this technique indicates that logistical and financial barriers, as well as the inadequacy of information allowing us to separate benign copy number variants from pathogenic deletions and duplications [46], may need to be addressed before the technique is used more routinely.

All of the information gathered through the steps outlined above is necessary for proper genetic counseling, the need for which is established by the poor prognosis in the most severely affected patients and the relative uncertainty of each patient's severity *a priori* due to the extreme phenotypic variability of the condition. Effective genetic counseling takes into account the inconsistency of strict genotype-phenotype correlations for each identified genetic variant, indicating the need for caution while interpreting molecular results. Although medical genetics may not be a particular physician's area of expertise, we urge pediatricians to familiarize themselves with the above recommendations and to correspond with medical geneticists, so that the quality of genetic counseling can be enhanced and further morbidity and mortality related to holoprosencephaly can be ameliorated.

Contributors: All authors participated in the critical editing of this review article.

Competing interests: No authors have any financial/personal disclosures or competing interests.

Funding: Support was provided in part by Division of Intramural Research at the National Human Genome Research Institute

(National Institutes of Health, Department of Health and Human Services, United States of America).

REFERENCES

- O'Rahilly R, Müller F. Interpretation of some median anomalies as illustrated by cyclopia and symmelia. *Teratology*. 1989;40:409-21.
- Matsunaga E, Shiota K. Holoprosencephaly in human embryos: epidemiologic studies of 150 cases. *Teratology*. 1977;16:261-72.
- Leoncini E, Baranello G, Orioli IM, Annerén G, Bakker M, Bianchi F, *et al.* Frequency of holoprosencephaly in the International Clearinghouse Birth Defects Surveillance systems: searching for population variations. *Birth Defects Res A*. 2008;82:585-91.
- Orioli IM, Castilla EE. Epidemiology of holoprosencephaly: prevalence and risk factors. *Am J Med Genet C Semin Med Genet*. 2010;154C:13-21.
- Thakur S, Singh R, Pradhan M, Phadke SR. Spectrum of holoprosencephaly. *Indian J Pediatr* 2004;71:593-7.
- Verma IC. Medical genetics in India. *Indian J Pediatr*. 1986;53:437-40.
- Verma IC. Burden of genetic disorders in India. *Indian J Pediatr*. 2000;67:893-8.
- DeMyer W, Zeman W. Alobar holoprosencephaly (arhinencephaly) with median cleft lip and palate: clinical, electroencephalographic and nosologic considerations. *Confin Neurol*. 1963;23:1-36.
- Barkovich AJ, Quint DJ. Middle interhemispheric fusion: an unusual variant of holoprosencephaly. *AJNR Am J Neuroradiol*. 1993;14:431-40.
- Hahn JS, Barnes PD. Neuroimaging advances in holoprosencephaly: refining the spectrum of the midline malformation. *Am J Med Genet C Semin Med Genet*. 2010;154C:120-32.
- Solomon BD, Lacbawan F, Jain M, Domené S, Roessler E, Moore C, *et al.* A novel *SIX3* mutation segregates with holoprosencephaly in a large family. *Am J Med Genet A*. 2009;149A:919-25.
- DeMyer W, Zeman W, Palmer CG. The face predicts the brain: diagnostic significance of median facial anomalies for holoprosencephaly (arhinencephaly). *Pediatrics*. 1964;34:256-63.
- Solomon BD, Mercier S, Vélez JI, Pineda-Alvarez DE, Wyllie A, Zhou N, *et al.* Analysis of genotype-phenotype correlations in human holoprosencephaly. *Am J Med Genet C Semin Med Genet*. 2010;154C:133-41.
- Solomon BD, Lacbawan F, Mercier S, Clegg NJ, Delgado MR, Rosenbaum K, *et al.* Mutations in *ZIC2* in human holoprosencephaly: description of a novel *ZIC2*-specific phenotype and comprehensive analysis of 157 individuals. *J Med Genet*. 2010;47:513-24.
- Johnson CY, Rasmussen SA. Non-genetic risk factors for holoprosencephaly. *Am J Med Genet C Semin Med Genet*. 2010;154C:73-85.
- Muenke M, Beachy PA. Holoprosencephaly. *In*: Scriver CR, Beaudet AL, Sly WS, Valle D, editors. *The Metabolic and Molecular Bases of Inherited Disease*. 8th ed. New York: McGraw-Hill; 2001. p.6203-30.
- Croen LA, Shaw GM, Lammer EJ. Holoprosencephaly: epidemiologic and clinical characteristics of a California population. *Am J Med Genet*. 1996; 64:465-72.
- Olsen CL, Hughes JP, Youngblood LG, Sharpe-Stimac M. Epidemiology of holoprosencephaly and phenotypic characteristics of affected children: New York State, 1984-1989. *Am J Med Genet*. 1997;73:217-26.
- Solomon BD, Rosenbaum KN, Meck JM, Muenke M. Holoprosencephaly due to numeric chromosome abnormalities. *Am J Med Genet C Semin Med Genet*. 2010; 154C:146-48.
- Roessler E, Belloni E, Gaudenz K, Jay P, Berta P, Scherer SW, *et al.* Mutations in the human *Sonic Hedgehog* gene cause holoprosencephaly. *Nat Genet*. 1996;14:357-60.
- Nanni L, Ming JE, Bocian M, Steinhaus K, Bianchi DW, de Die-Smulders C, *et al.* The mutational spectrum of the *Sonic Hedgehog* gene in holoprosencephaly: *SHH* mutations cause a significant proportion of autosomal dominant holoprosencephaly. *Hum Mol Genet*. 1999;8: 2479-88.
- Roessler E, El-Jaick KB, Dubourg C, Vélez JI, Solomon BD, Pineda-Álvarez DE, *et al.* The mutational spectrum of holoprosencephaly-associated changes within the *SHH* gene in humans predicts loss-of-function through either key structural alterations of the ligand or its altered synthesis. *Hum Mutat*. 2009;30:E921-35.
- Wallis DE, Roessler E, Hehr U, Nanni L, Wiltshire T, Richieri-Costa A, *et al.* Mutations in the homeodomain of the human *SIX3* gene cause holoprosencephaly. *Nat Genet*. 1999;22:196-8.
- Domené S, Roessler E, El-Jaick KB, Snir M, Brown JL, Vélez JI, *et al.* Mutations in the human *SIX3* gene in holoprosencephaly are loss of function. *Hum Mol Genet*. 2008;17:3919-28.
- Lacbawan F, Solomon BD, Roessler E, El-Jaick K, Domené S, Vélez JI, *et al.* Clinical spectrum of *SIX3*-associated mutations in holoprosencephaly: correlation between genotype, phenotype and function. *J Med Genet*. 2009;46:389-98.
- Brown SA, Warburton D, Brown LY, Yu C-y, Roeder ER, Stengel-Rutkowski S, *et al.* Holoprosencephaly due to mutations in *ZIC2*, a homologue of *Drosophila odd-paired*. *Nat Genet*. 1998;20:180-3.
- Gripp KW, Wotton D, Edwards MC, Roessler E, Ades L, Meinecke P, *et al.* Mutations in *TGIF* cause holoprosencephaly and link NODAL signalling to human neural axis determination. *Nat Genet*. 2000;25:205-8.
- Roessler E, Muenke M. The molecular genetics of holoprosencephaly. *Am J Med Genet C Semin Med Genet*. 2010;154C:52-61.
- Odent S, Le Marec B, Munnich A, Le Merrer M, Bonaïti-Pellié C. Segregation analysis in nonsyndromic holoprosencephaly. *Am J Med Genet*. 1998;77:139-43.
- Ming JE, Muenke M. Multiple hits during early embryonic development: digenic diseases and holoprosencephaly. *Am J Hum Genet*. 2002;71:1017-32.
- Dipple KM, McCabe ERB. Phenotypes of patients with "simple" Mendelian disorders are complex traits:

- thresholds, modifiers, and systems dynamics. *Am J Hum Genet.* 2000;66:1729-35.
32. Hahn JS, Plawner LL. Evaluation and management of children with holoprosencephaly. *Pediatr Neurol.* 2004;31:79-88.
 33. Joó GJ, Beke A, Papp C, Tóth-Pál E, Szigeti Z, Bán Z, *et al.* Prenatal diagnosis, phenotypic and obstetric characteristics of holoprosencephaly. *Fetal Diagn Ther.* 2005;20:161-6.
 34. Wenghoefer M, Ettema AM, Sina F, Geipel A, Kuijpers-Jagtman AM, Hansmann H, *et al.* Prenatal ultrasound diagnosis in 51 cases of holoprosencephaly: craniofacial anatomy, associated malformations, and genetics. *Cleft Palate Craniofac J.* 2010;47:15-21.
 35. Mercier S, Dubourg C, Belleguic M, Pasquier L, Loget P, Lucas J, *et al.* Genetic counseling and “molecular” prenatal diagnosis of holoprosencephaly (HPE). *Am J Med Genet C Semin Med Genet.* 2010;154C:191-6.
 36. Barr Jr. M, Cohen Jr. MM. Holoprosencephaly survival and performance. *Am J Med Genet.* 1999;89:116-20.
 37. Levey EB, Stashinko E, Clegg NJ, Delgado MR. Management of children with holoprosencephaly. *Am J Med Genet C Semin Med Genet.* 2010;154C:183-90.
 38. Roesler CP, Paterson SJ, Flax J, Hahn JS, Kovar C, Stashinko EE, *et al.* Links between abnormal brain structure and cognition in holoprosencephaly. *Pediatr Neurol.* 2006;35:387-94.
 39. Plawner LL, Delgado MR, Miller VS, Levey EB, Kinsman SL, Barkovich AJ, *et al.* Neuroanatomy of holoprosencephaly as predictor of function: beyond the face predicting the brain. *Neurology.* 2002;59:1058-66.
 40. Hahn JS, Hahn SM, Kammann H, Barkovich AJ, Clegg NJ, Delgado MR, *et al.* Endocrine disorders associated with holoprosencephaly. *J Pediatr Endocr Met.* 2005;18:935-41.
 41. Hahn JS, Delgado MR, Clegg NJ, Sparagana SP, Gerace KL, Barkovich AJ, *et al.* Electroencephalography in holoprosencephaly: findings in children without epilepsy. *Clin Neurophysiol.* 2003;114:1908-17.
 42. Simon EM, Hevner RF, Pinter JD, Clegg NJ, Delgado M, Kinsman SL, *et al.* The dorsal cyst in holoprosencephaly and the role of the thalamus in its formation. *Neuroradiology.* 2001;43:787-91.
 43. Agarwal SS. Medical genetics in India – what needs to be done? *Indian J Med Res.* 2009;130:354-56.
 44. Weaver DD, Solomon BD, Akin-Samson K, Kelley RI, Muenke M. Cyclopia (synophthalmia) in Smith-Lemli-Opitz syndrome: first reported case and consideration of mechanism. *Am J Med Genet C Semin Med Genet.* 2010;154C:142-5.
 45. Pineda-Alvarez DE, Dubourg C, David V, Roessler E, Muenke M. Current recommendations for the molecular evaluation of newly diagnosed holoprosencephaly patients. *Am J Med Genet C Semin Med Genet.* 2010;154C:93-101.
 46. Sharp AJ. Emerging themes and new challenges in defining the role of structural variation in human disease. *Hum Mutat.* 2009;30:135-44.
-