

Is Female Infanticide Spreading to Karnataka?

Female infanticide is a social evil that is said to be prevalent in states of Tamil Nadu, Rajasthan and Bihar. Various methods are used to kill the female at birth. We report a novel method that was tried in a female newborn.

A six day old, first born female child was brought to the hospital with a complaint of refusal to feed, respiratory distress and bleeding from oral cavity. The infant was born at home and the delivery was conducted by an untrained "Dai". The child was said to be apparently well for the first three days taking regular feeds from breast.

On physical examination, the infant was a term baby weighing 2.8 kg and was in respiratory distress. There was no cyanosis and peripheral pulses were well felt. There was profuse bleeding from the oral cavity. The breath sounds were decreased all over both lung fields. Oral cavity was cleared of blood and there was no obvious source of bleeding.

An attempt to pass a FG 8 infant feeding tube into the stomach failed which made us suspect some esophageal obstruction. An X-ray of the neck and chest showed a dense foreign body in the esophagus (*Fig. 1*). The baby was immediately shifted to operation theatre and the esophageal foreign body was removed. The foreign body was a pebble with an irregular surface measuring about 2.5 cm in

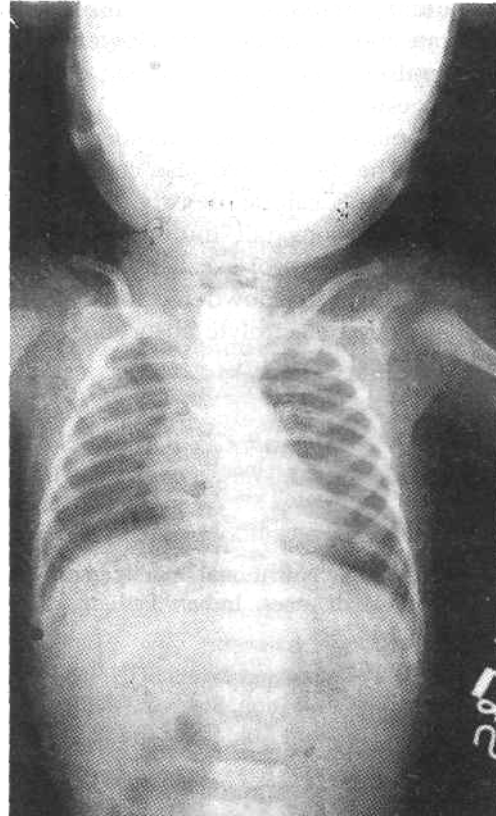


Fig.1. X-ray Chest AP view showing dense opaque foreign body in the neck.

diameter. Unfortunately the baby died of cardiac arrest in the immediate post operative period.

The parents denied having intentionally introduced the foreign body into the child's mouth and further there was no older sibling or any other child in the family to suspect such an act due to rivalry.

We suspect that in all probability this was an attempt at infanticide. It is reported that in Bihar, the killing is done by the 'Dais' or traditional mid wives, at the behest of husband on payment of fee that varies from Rs 60 plus a saree to Rs 150(1). In Tamil Nadu female infanticide is carried out by covering the faces by a wet towel or feeding them with poisonous milk of a plant; in Bihar the child's spinal cord is snapped by holding it from the waist, throwing it backward and forward, by feeding salt or stuffing the child into a clay pot(1). It is reported that in Bihar each 'Dai' has claimed to have killed 1-2 babies a month and there are 5,30,000 Dais in the State of Bihar(1).

In our present case the introduction of a foreign body in the child's throat seems to be yet another method of female infanticide. Female infanticide is a very sensitive issue that needs to be eliminated by socio-cultural reforms.

**M.L. Kulkarni,
Kallesh Hebbal,
Koujalgi, M.B.
Ramesh, M.B.**

*Department of Pediatrics,
J.J.M. Medical College,
Davangere 577 004, Karnataka.*

REFERENCE

1. Rai U. A life for a sari and Rs. 60. 'Nexus' New Delhi, Population Services International, October-November, pp 1-2.