

Darier-White disease or keratosis follicularis is said to occur as a result of mutation in the *ATP2A2* gene located on chromosome 12q23-24.1, responsible for coding sarco/endoplasmic reticulum calcium ATPase type 2 (SERCA2). It is characterized clinically by hyperkeratotic papules distributed mostly on the seborrheic areas of the body. Nail involvement is characterized by V-shaped nicking at the distal aspect of the nail bed, longitudinal red and white alternating bands, and subungual hyperkeratosis. Mucosal membrane involvement may occur as white papules on the buccal mucosae, palate, and gingiva with a cobblestone appearance. Palmoplantar involvement usually presents as discrete, punctate keratoses that appear as small, hyperkeratotic papules or small, centrally depressed pits. In flexures like axilla and groin, the lesions may become large exuberant growth. They may get infected due to constant maceration resulting in malodorous purulent discharge. Heat, sweat, humidity, sunlight, oral corticosteroids and mechanical trauma have been reported to exacerbate this condition.

Conventional therapy for severe disease still relies greatly on oral retinoids. Acitretin is effective at 0.6 mg/kg/day, the hyperkeratosis is reduced and papules are flattened. Basic measures include use of sunscreens, cool cotton clothing, and avoidance of hot environment. Moisturizers with urea or lactic acid can reduce scaling and hyperkeratosis. Surgical treatment includes dermabrasion, carbon dioxide laser, and the erbium YAG laser. The condition runs a chronic relapsing course, with exacerbations throughout life.

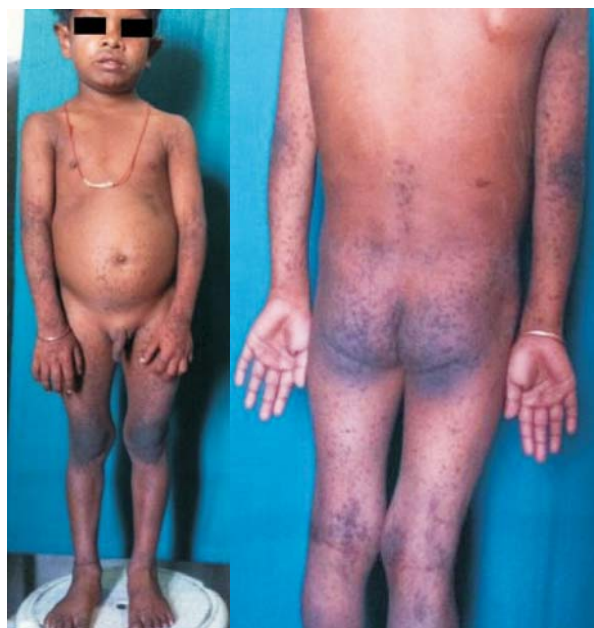


FIG. 1 Multiple hyperkeratotic lesions including (a) knees and elbows, and (b) buttocks.

**NIRUPAMA PARWANDA, *NEETI KUMARI AND
#PRAVEEN BHARDWAJ**

*From the Department of Dermatology,
Patna Medical College and Hospital, Patna;
*SGRRIMHS, Dehradun; and #Dermatology,
Bangalore Medical College, Bangalore, India.
dr.nirupama9@gmail.com*

BOOK REVIEW



**Clinical Assessment and
Management of Childhood
Psychiatric Disorders**

SAVITA MALHOTRA
*CBS Publishers & Distributors; New
Delhi.*

Pages: 226; Price: Rs. 350/-

This edition contains 12 chapters and a glossary of terms, Child Guidance Clinic Proforma and important assessment scales (many by the author) adapted for India. The development perspective of the child has been provided with an emphasis on the roles of family and school. The approach to psychological, psychiatric and neurodevelopment assessment is elucidated in detail. The

International classifications of childhood psychiatric disorders is also given. The important issues related to adolescence are discussed separately. The book provides steps to diagnose and treat common childhood psychiatric emergencies. The simple presentation style of the book makes it useful for undergraduate and postgraduate students, pediatricians and mental health professionals. Inclusion of case reports, photographs, and childhood problems related to schools in future edition will enrich the text and make it also useful for teachers and parents.

MS BHATIA

*Professor & Head, Department of Psychiatry,
UCMS & GTB Hospital, Dilshad Garden,
Delhi 110 095, India.
manbhatia@rediffmail.com*