

Case Reports

Right Atrial Mass Due to Fungal Endocarditis in an Infant

Shyam S. Kothari
Mukti Sharma
Anita Saxena
Rajesh Sharma

Systemic fungal infection occurs in approximately one per cent of the infants in neonatal intensive care units(1,2). Prematurity, prolonged endotracheal intubation, arterial and central venous catheters, use of broad spectrum antibiotics and steroids, necrotizing enterocolitis and gastrointestinal surgery have been associated with development of invasive fungal infections in these infants(1-3). Fungal endocarditis is an uncommon manifestation of systemic fungal infections and is usually related to the presence of indwelling catheters in the right atrium(4). We report a 40-day-old infant who developed a large right atrial mass due to fungus ball in the absence of any indwelling catheters.

Case Report

A 3 kg, 10-day-old boy was referred because of a cardiac murmur. He was born of a normal delivery at term and had normal APGAR score at birth. A diagnosis of mild valvular aortic stenosis with

coarctation of aorta was made because of the murmur and palpable but weak femoral pulses. There were no dysmorphic features. The heart rate was 100/min and blood pressure 90 mm Hg systolic. There were no features of congestive heart failure. The chest X-ray showed a normal thymic shadow, no cardiomegaly and normal pulmonary vessels. The echocardiogram confirmed the diagnosis. A gradient of 25 mm Hg was found across the bicuspid aortic valve and a gradient of 50 mm Hg was present at the site of coarctation. The left ventricular function was normal. The child was treated with intravenous cefotaxime (50 mg/kg in 2 divided doses) and amikacin (15 mg/kg in 2 divided doses) for 10 days for chest infection. The intravenous antibiotics were given by a scalp vein in a routine manner. Repeat echocardiogram showed same findings. Surgery for coarctation of the aorta was refused by the parents.

The child was readmitted when 40-day old with complaints of refusal to feed and lethargy for one day. Marked pallor, tachycardia and 6 cm hepatomegaly were recorded. An urgent echocardiogram showed a large mass in the right atrium attached to the tricuspid valve (*Fig. 1*). The mass was causing tricuspid stenosis and mild tricuspid regurgitation. The hemoglobin level was 4 g/dl, TLC 9000/cu mm, ESR 20 mm fall in first hour, serum calcium 9 mg/dl and magnesium 1.8 mEq/L. A diagnosis of infective endocarditis was considered as the echocardiogram done 2 weeks prior did not show the mass. The blood culture grew *Candida* spp. Anemia was corrected by packed cell transfusion and immediate surgery was considered in view of the large

From the Cardiothoracic Center, All India Institute of Medical Sciences, New Delhi 110 029.

Reprint requests: Dr. Shyam S. Kothari, Cardiothoracic Center, All India Institute of Medical Sciences, Ansari Nagar, New Delhi 110 029.

*Received for publication: May 15, 1995;
Accepted: September 20, 1995*

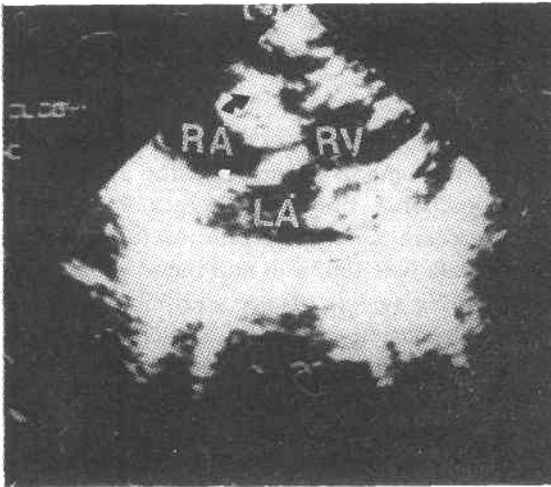


Fig. 1a. Echocardiogram (subcostal oblique cut) showing large vegetation in right atrium attached to the tricuspid valve (arrow). RA- right atrium; LA- left atrium; RV- right ventricle

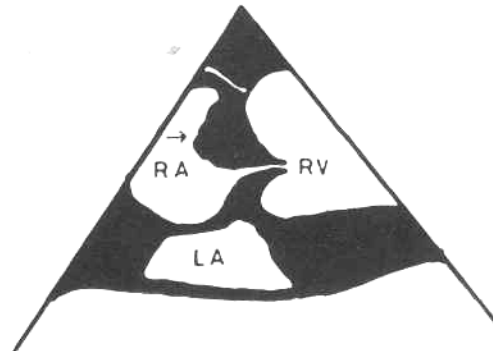


Fig. 1b. Schematic diagram of the echocardiogram

size of the mass and the risk of embolization. A 2 x 2 cm fungus ball attached to the tricuspid valve was removed at surgery and coarctation was repaired by subclavian flap angioplasty. The histopathology of the fungus ball showed *Candida* with branching and yeasts. The patient received amphotericin B (1 mg/kg/ day) postoperatively. However he died on the fifth postoperative day because of low cardiac output.

Discussion

Fungal endocarditis in neonates, usually due to *Candida* species is being increasingly recognised. *Candida* is ubiquitous in the environment of the neonate and systemic candidiasis usually results in presence of predisposing factors, immune deficiency states, abnormalities of leucocyte function(5) and magnesium deficiency(6).

The right atrial mass in neonates could be an uninfected thrombus, a tumor or a vegetation. A normal echocardiogram few days prior made tumor unlikely, and in the

absence of an indwelling catheter large spontaneous thrombus was also unlikely. *Candida* endocarditis was suspected due to a large mass and few constitutional features. Unexplained episodes of apnea, bradycardia and hypotension could result from unanticipated right atrial mass in neonates(7). Therefore, echocardiogram should be done in neonates with such symptoms and indwelling catheters, and also in neonates with persistent candidemia.

Fungal endocarditis carries a high mortality and surgery is the management of choice(8). More recently cure of fungal endocarditis with a long course of anti-fungal drugs has been reported(9). Amphotericin B in the dose of 1 mg/kg/ day for 40 to 70 days is well tolerated. The addition of flucytocine to the treatment is also reported(10). Cardiac surgery was considered in our patient because of a large mass and associated cardiac lesion. However, the decision must be individualized. Increased awareness of the entity is warranted so that an early diagnosis be made and optimal treatment instituted.

REFERENCES

1. Weese-Mayer DE, Fondriest DW, Brouillette RT, Shulma ST. Risk factors associated with candidemia in the neonatal intensive care unit: a case control study. *Pediatr Inf Dis J* 1987, 6: 190-196.
 2. Butler KM, Baker CJ. *Candida*: An increasingly important pathogen in the nursery. *Pediatr Clin North Am* 1988, 35: 543-653.
 3. Bailey JE, Kliegman RM, Fanaroff AA. Disseminated fungal infection in very low birth weight infants: Clinical manifestations and epidemiology. *Pediatrics* 1984, 73:144-152.
 4. Millard DD, Shulman ST. The changing spectrum of neonatal endocarditis. *Clin Perinatol* 1988,15: 587-608.
 5. Coen R, Gursh O, Kauder E. Studies of bactericidal activity and metabolism of leucocyte in full term neonates. *J Pediatr* 1969,75: 400-406.
 6. Larvor P. Magnesium, humoral immunity and allergy. *In: Magnesium in Health and Disease*, proceedings of the 2nd International Symposium on Magnesium. Eds. Cannin M, Seelig MS. New York, Medical and Scientific Books, 1976. pp 11-38.
 7. Panidis P, Kotler MN, Mintr GS, Ross J. Clinical and echocardiographic features of right atrial masses. *Am Heart J* 1984, 107: 745-758.
 8. Turnier EK, Kay JH, Bernstein S, Mendez AM, Zubiato P. Surgical treatment of *Candida* endocarditis. *Chest* 1975, 67: 262- 268.
 9. Zenker PN, Rosenberg EM, Van Dyke RB, Robalais GP, Daum RS. Successful medical treatment of presumed *Candida* endocarditis in critically ill infants. *J Pediatr* 1991,119: 472-477.
 10. Sanchez PJ, Siegal JD, Fishbein J. *Candida* endocarditis: Successful medical management in three preterm infants and review of literature. *Pediatr Inf Dis J* 1991, 10: 239-243.
-