

Successful Treatment with Cyclophosphamide in a Large Hepatic Hemangioendothelioma

M. Manglani
G. Chari
U. Sharma
A. Jog
K. Raghavan
M.R. Lokeshwar

Hemangioendotheliomas are uncommon benign vascular tumors usually presenting during infancy. Most of them resolve spontaneously, and complete disappearance by 5 years with or without treatment is the rule(1). Though benign, they can have an unfavorable outcome when symptomatic. Various modalities of treatment are recommended, which include steroids, radiotherapy, hepatic artery ligation or embolization and surgical resection, either alone or in combination. Corticosterpids are recommended as the first line of management, and are usually very effective. The excellent response to cyclophosphamide following a failure of steroid therapy prompted us to report this case.

From the Division of Hematology-Oncology, Department of Pediatrics, L.T.M.G. Hospital and L. T.M. Medical College, Sion, Bombay 400 022.

Reprint requests: Dr. Mamta Manglani, 51, Sea Springs, B.J. Road, Band Stand, Bandra (W), Bombay 400 050.

*Received for publication: February 1, 1993;
Accepted: May 2, 1994*

Case Report

A 4-year-old boy was admitted to our intensive pediatric care unit with history of fever, cough and breathlessness of 4 days duration, with a history of similar such episodes 3-4 times in the past. Examination revealed a toxic, febrile, pale child with respiratory distress and signs of congestive cardiac failure. He had a firm tender hepatomegaly of 6 cm. Clinically, a differential diagnosis of pyemic liver abscess, amebic liver abscess and hepatic hemangioendothelioma was kept in mind. On investigations, he had a hemoglobin of 7 g/dl, a total leucocyte count of 17,400/cu mm with a normal differential leucocyte count and normal platelet count. Liver function test showed a mild direct hyperbilirubinemia (total serum bilirubin 2.8 mg/dl, and direct serum bilirubin 2.2 mg/dl) and an SGOT of 114 IU. Renal function tests and serum electrolytes were within normal range. USG abdomen with doppler study revealed enhanced hypoechoic areas interspersed in a mass lesion in the right lobe of liver, suggestive of a hemangioendothelioma, the diagnosis of which was confirmed by a dynamic CT Scan (*Fig.1*). Meanwhile the child developed bleeding tendencies and coagulation profile confirmed presence of DIC. The child was treated with parenteral broad spectrum antibiotics, digitalis, furosemide, fresh frozen plasma and packed cell transfusions. Steroids (prednisolone) were started in the dose of 2 mg/kg/day. Unfortunately, the child did not improve even after 3 weeks of steroid therapy, though his infection was controlled. Hence, alternative treatment modalities were considered. Since the patient's general condition was poor and the tumor was in the right lobe of liver, hence unresectable, a conservative approach was adopted. Cyclophosphamide was given in

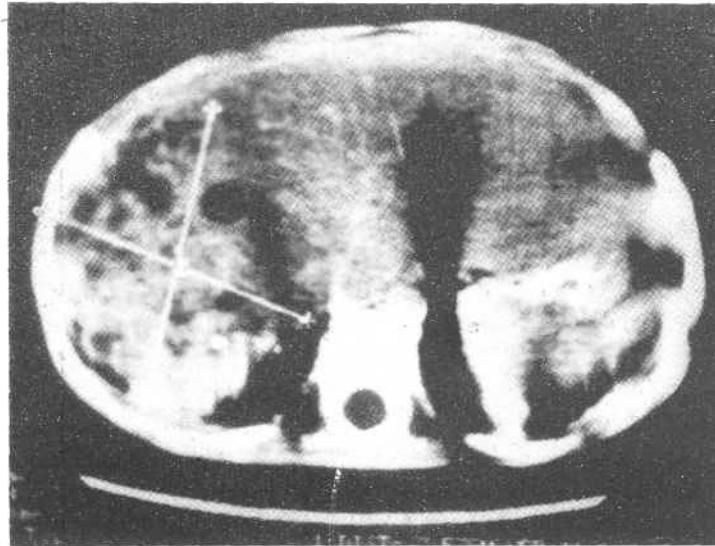


Fig. 1. Abdominal CT scan showing the lesion.

the dose of 10 mg/kg/day for 3 days in an intravenous infusion. A significant response was observed with regression of liver size and control of CCF within a couple of days. A repeat USG abdomen at this stage showed a dramatic reduction of the tumor, which completely healed within a week after completion of this treatment. On subsequent follow up for almost a year 'now, the child is doing very well.

Discussion

Hepatic hemangioendotheliomas usually present in the newborn period and almost always before 6 months of age(2). Involution preceded by development of small A-V fistulas begins by 6 months in 16% of infants, by 1 year in 85% and in the remainder after 1 year of age. Complete disappearance by 5 years with or without treatment is the rule(1). The presenting features include classic triad of hepatomegaly, CCF and cutaneous hemangiomas(2,3), the mortality

being as high as 90% in presence of CCF(1). Other clinical features which may be present are jaundice, thrombocytopenia and consumptive coagulopathy. Though hepatic arteriography was the gold standard of diagnosis in the earlier years, it has been completely replaced by dynamic CT Scanning and doppler USG (color). Treatment is directed at systemic manifestations of the tumor, along with specific measures. CCF can be managed with digitalis and diuretics, and consumption coagulopathy can be successfully treated with EACA and cryoprecipitate. Corticosteroids have been well established as a specific therapeutic modality in hemangioendotheliomas(4). Radiation therapy is effective, however, because this treatment may cause organ damage and bears the potential of malignant changes, it should not be considered unless other modes of therapy have failed. Transcatheter arterial embolization and hepatic artery ligation are useful only when arteriography

demonstrates suitable vascular anatomy. This involves an invasive procedure with its inherent risks of infection and bleeding, as well as a possibility of bioincompatibility of particles used for embolization. When possible, surgical excision can be an effective treatment. However, in inoperable cases, cyclophosphamide has been recommended as the next best alternative where steroids have failed. Cyclophosphamide in combination with steroids and radiation has been tried as early as 1971, with a striking response attributed to cyclophosphamide(5). A similar response has been reported with cyclophosphamide alone(6). In our patient too, we found an excellent response with a single cycle of cyclophosphamide. The mechanism by which it helps is unknown, but thought to be related to its corrosive action. It probably causes damage to the endothelial cells of the tumor vessels resulting in collapse, shrinkage and fibrosis, and subsequent regression of the tumor. Being an antimetabolite, it also reduces the proliferation of newer capillaries. Though serious long term side effects such as gonadal damage and second malignancies are well known with cyclophosphamide, the short duration of treatment makes them highly

improbable. Thus, to conclude, cyclophosphamide may be considered in all cases of large hemangioendotheliomas failing to respond to steroids.

REFERENCES

1. Charles J, Harry LG, James O'Neil, Sandra K. Hepatic hemangioendothelioma. *Am J Dis Child* 1977, 131: 74-77.
2. Links FT, Yazbeck S, Brandt ML, *et al.* Benign liver tumors in children: A 25 year experience. *J Pediatr Surg* 1991, 26: 1326-1330.
3. Braun P, Ducharme JC, Riopelle JL, Davignon A. Hemangiomas of the liver in infants. *J Pediatr Surg* 1975, 10: 121-126.
4. Fost NC, Esterley NB. Successful treatment of juvenile hemangiomas with prednisolone. *J Pediatr* 1968, 72: 351-357.
5. Rashid AL. Cyclophosphamide and radiation therapy in the treatment of hemangioendothelioma with disseminated intravascular clotting. *Cancer* 1971, 27: 364-368.
6. Neviwitz CH, Alkalay AL, Sloninsky L, Kallus W, Pomerance JJ. Cyclophosphamide therapy in life-threatening vascular tumors. *J Pediatr* 1986, 109: 360-362.