

Infantile Cortical Hyperostosis

Sourabh Dutta

Naveen Jain

Anish Bhattacharya*

Kanya Mukhopadhyay

Infantile cortical hyperostosis (Caffey disease) is characterized by radiological evidence of cortical hyperostosis, soft tissue swellings, fever and irritability. We report a case of Caffey disease highlighting its presentation as pyrexia of unknown origin, appearance on radionuclide bone scintigraphy and our unsatisfactory experience of treating it with Ibuprofen, a prostaglandin inhibitor.

Key words: Caffey disease, Cortical, Hyperostosis.

Infantile cortical hyperostosis (ICH), also called Caffey disease, occasionally presents as pyrexia of unknown origin (PUO). We report one of a pair of twins, who presented as PUO, was diagnosed to have ICH on a radionuclide bone scintigram and did not improve on treatment with ibuprofen.

Case Report

A 2-month-old boy, one of a pair of dizygotic twins, presented with fever for 2 weeks. He was irritable, but his activity and weight gain were satisfactory. Clinical

From the Division of Neonatology, Department of Pediatrics and Department of Nuclear Medicine, Post Graduate Institute of Medical Education and Research, Chandigarh 160 012, India.*

Correspondence to: Dr. Sourabh Dutta, Assistant Professor, Department of Pediatrics, PGIMER, Chandigarh 160 012, India.

E-mail: sourabhdutta@yahoo.co.in

Manuscript received: March 8, 2004.

Initial review completed: March 15, 2004;

Revision accepted: August 10, 2004.

examination did not reveal any localizing features. His serum C-reactive protein (CRP) was elevated (>10 mg/L) through the illness. There was anemia and persistent severe thrombocytosis (platelet count $1,100 \times 10^9/L$). An extensive laboratory work-up for cause of fever was unrewarding. The bones appeared normal on the initial whole body skiagram. There was no response to empirical antibiotic and anti-malarial therapy.

An abdominal X-ray done on day 84 of life, for abdominal distension, incidentally showed mild widening of 2 lower ribs on the right side. Ultrasonography did not show subperiosteal collections. Bone scintigraphy, performed with methylene di-phosphonic acid (MDP), demonstrated blood pool and delayed phase images suggestive of inflammation in all the ribs on the right side, the lowest rib on the left and the mandible, but the vertebrae were spared (*Fig. 1*). On the basis of scintigraphy, ICH was suspected. The disease progressed and an X-ray done a week later showed classical findings of thick irregular bone cortex in a distribution similar to the radio nuclide scintigram (*Fig. 2*). Serum alkaline phosphatase was normal.

He was started on Ibuprofen at a dose of 10 mg/kg/dose 8 hourly and fever subsided within a week. However the child remained irritable, continued to have elevated CRP levels and developed chest wall tenderness after 4 weeks of Ibuprofen therapy. At this time, since the platelet counts had dropped to $800-900 \times 10^9/L$, Ibuprofen was replaced by oral prednisolone (1mg/kg/day). Within 10 days, the child's irritability and pain subsided, platelet counts decreased to $630 \times 10^9/L$ and CRP turned negative. He became completely asymptomatic by 1 month, following which the prednisolone was tapered off.

A radionuclide bone scan done at 6 months

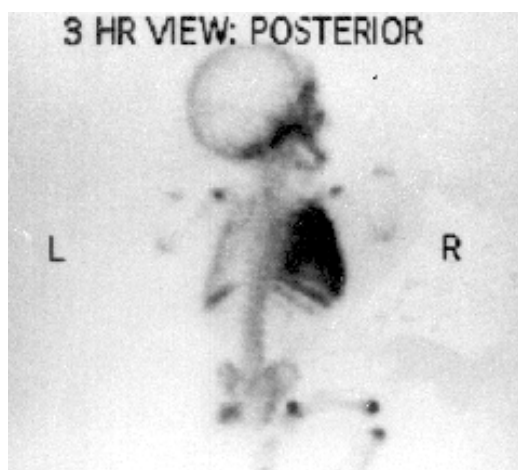


Fig. 1. Radio nuclide bone scan (posterior view) on day 85 showing involvement of all ribs on the right side, lowest rib on the left and the mandible.

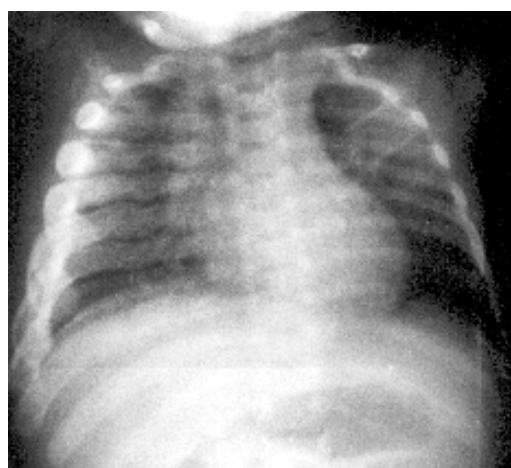


Fig. 2 Plain X-ray of the chest (antero-posterior view) showing cortical hyperostosis of the ribs.

of life showed near complete resolution, with a solitary residual hot spot in the right hemithorax. There has been no recurrence of the disease till 1 year of age. His linear growth has been normal till 1 year.

The fraternal twin was investigated for ICH but bone scintigraphy and skeletal X-rays were normal. He has also been followed up till 1 year and his linear growth is within normal limits.

Discussion

Infantile cortical hyperostosis is characterized by hyperirritability, soft tissue swelling and cortical hyperostosis. The median age of presentation is around 9 weeks of age. Our patient presented as a PUO from 6 weeks, and the disease was suspected on an X-ray done in the course of investigations. Fever in ICH may be due to high prostaglandin levels or due to excessive metabolic activity in the bones.

The commonest site of bone involvement

described in literature is the mandible followed by the clavicles, ulna, scapula, tibia and ribs(1,2). Vertebrae and phalanges have never been reported to be involved. Radionuclide bone scintigraphy is generally considered to be non-specific for ICH, because multi-focal osteomyelitis can present with a similar picture. However, in our case, the striking pattern of involvement, sterile cultures and absence of sub-periosteal collection left us with no other differential diagnosis.

Several hypotheses have been proposed for the etiology of ICH. Since similar lesions have been described in infants who receive exogenous prostaglandins, one of the proposed mechanisms is a disturbance of endogenous prostaglandin regulation. Some authors have tried prostaglandin inhibitors, such as naproxen and indomethacin, and intravenous gamma-globulin with some success(3,4). Naproxen has been reported to produce immediate and complete resolution of signs in a young girl who was having

frequent relapses. Indomethacin, at a dose of 3 mg/kg per day starting at the age of 9 months, was used to treat a pair of twins who were otherwise dependent on prednisolone. Indomethacin therapy allowed the cessation of prednisolone and disease flares were thereafter infrequent and responsive to indomethacin.

We used Ibuprofen for treatment. While selecting this drug, our considerations were that we have a convenient pediatric liquid formulation available, and being a platelet inhibitor, it would be preferred to steroids in a situation where there is thrombocytosis. The initial response to Ibuprofen in our patient was encouraging, but apart from defervescence, there appeared to be no change in the disease process. Hence, we started corticosteroids after an adequate trial of Ibuprofen.

The course of the illness is generally benign and recovers completely in many cases without treatment by 1 year (5). Relapses have been sporadically reported. The normal height at 1 year and lack of osteological complications in the index patient corroborates the benign nature of the disease. Bone scan is more sensitive, but less specific than CT scan or MRI for diagnosing ICH. There are no studies directly comparing these modalities. Most cases are sporadic, but autosomal

dominant and autosomal recessive patterns have also been described(6). The fraternal twin of our patient has remained normal on follow up till 1 year of age.

Contributors: SD made the diagnosis and managed the patient, NJ wrote the manuscript, AN performed and interpreted the scans, KM was involved in the management of the patient.

Funding: None.

Competing interests: None declared.

REFERENCES

1. Mizrahi Mograbi L, de Id Calleja C. Cortical infantile hyperostosis. Report of a case and review of the literature. *Bol Med Hosp Infant Mex* 1977; 34: 315-324.
2. Rethmeier JW. Infantile cortical hyperostosis (Caffey disease). Two case reports. *Radiol Clin (Basel)* 1976; 45: 251-257.
3. Thometz JG, DiRaimando CA. A case of recurrent Caffey disease treated with naproxen. *Clin Orthop* 1996; 323: 304-309.
4. Couper RT, McPhee A, Morris L. Indomethacin treatment of infantile cortical hyperostosis in twins. *J Pediatr Child Health* 2001; 37: 305-308.
5. Pohl A, Orha L, Dragoi AM. Infantile cortical hyperostosis (Caffey disease). *Rev Pediatr Obstet Ginecol Pediatr* 1989; 38: 369-373.
6. Emmery L, Timmermans J, Christens J, Fryns JP. Familial infantile cortical hyperostosis. *Eur J Pediatr* 1983; 141: 56-58.