

virus diarrhea noticed among 23 children out of 92(25%) from rural area in the present study.

#### Acknowledgements

The authors are thankful to Dr. P. Sreenivasulu, Head of the Department of Virology, S.V. University, for his help by providing the ELISA kits and also to Dr. G. Rani and Dr. D.P.N.M.V. Ratna Malika, Professor of Pediatrics, S.V.R.R. G.G. Hospital, Tirupati, for their help.

#### REFERENCES

1. Synder JD, Mcrson MH. The magnitude of the global problems of acute diarrheal disease: A review of surveillance data. Bull WHO 1982, 60: 605-613.
2. Who scientific working group. Rota virus and other viral diarrheas. Bull WHO 1980, 58: 183-198.
3. Wlde J, Yolken R, Willoughby R, Eiden J. Improved detection of rota virus sheading by polymerase chain reaction. Lancet 1991, 337: 323-326.
4. Maiya PP, Periera SM, Mathan M, Bhat P, Albert MJ and Baker SJ. Etiology of acute gastroenteritis in infancy and early childhood in Southern India. Arch Dis Child 1977, 52: 482-485.
5. Dulkansteel A, Jennifer J, Alexander, Ian YH. Rota virus associated gastroenteritis in black infants in South Africa. J Clin Microbiol 1986, 23: 992-994.
6. Miott P, Eiden J, Yolken R. Comparative efficiency of commercial immunoassays for the diagnosis of rota virus gastroenteritis during the course of infection. J Clin Microbiol 1985, 22: 693-698.
7. Finegold SM, Baron EJ. Baily and Scotts" Diagnostic Microbiology. 7th edn. St Louis, CV Mosby Company, 1986, pp 208-273.
8. Steinhoff MC, John TJ. Nonbacterial gastroenteritis. Indian J Pediatr 1980, 47: 317-320.
9. Samantray JC, Mahapatra LN, Bhan MK, Ghai OP. Study of rota virus diarrhea in North Indian Community. Indian Pediatr 1982, 19: 761-764.
10. Cukor G, Blacklow N, Copooza F. Secretary IgA antibody of rota virus in human milk 6-9 months postpartum. Lancet 1978, 1: 631-632.

---

## Niemann-Pick Disease Type IS in Sibs with 20 Years Follow Up

**M.K. Jain**  
**V.P. Gharpure**

In 1983, we had reported two sibs with Niemann-Pick Disease (NPD) type B(1). Type B is now reclassified as type IS(2). Now we are reporting further follow up of these sibs. No such follow up has been reported so far in the Indian literature.

### Case Reports

*Case 1:* The subject, bora of non consanguinous marriage from Indian Christain family was admitted in KEM Hospital,

---

*From the Department of Pediatrics, Seth G.S. Medical College and K.E.M. Hospital, Par el, Bombay 400 012.*

*Reprint requests: Dr. M.K. Jain, Honorary Professor of Pediatrics, K.E.M. Hospital and Seth G.S. Medical College, Par el, Bombay 400 012.*

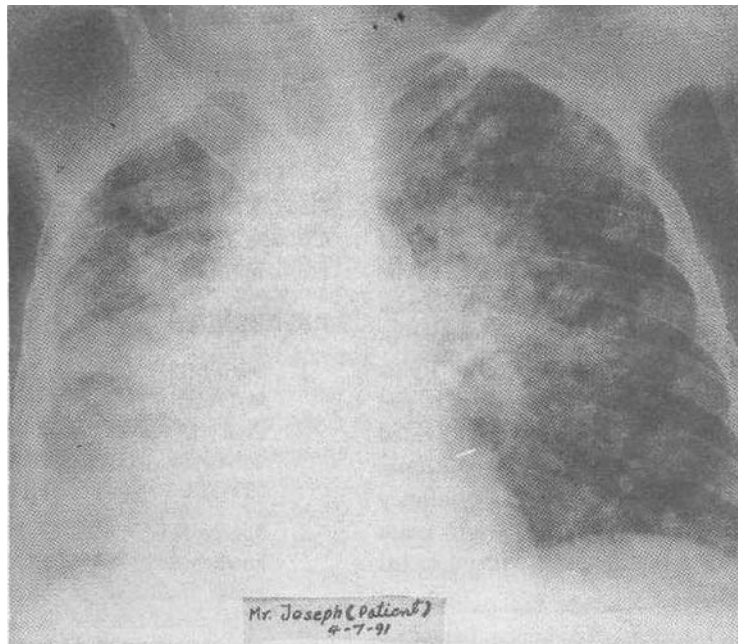
*Received for publication: August 31, 1992;*

Bombay in 1975 (age 9 years), with a history of progressive distention of abdomen noticed since infancy; jaundice at 1, 5 and 9 years of age, recurrent lower respiratory tract infections; frequent episodes of hemoptysis and epistaxis. His early developmental milestones were normal and had no neurological manifestations at that time. His younger sister expired at 7 years of age, she had hepatosplenomegaly, but no neurological manifestations at that time. She was not completely investigated.

On examination, he had massive hepatosplenomegaly (spleen 10 cm and liver 7 cm). His fundus examination revealed increased sphingomyelin (20 times the normal control). The enzyme sphingomyelinase was undetectable in cultured skin fibroblasts, whereas other lysosomal enzymes showed

normal activity.

During a follow up period from 1975 to 1990 he developed myoclonic jerks in 1983, requiring treatment with nitrazepam; deposits of sphingomyelin around the cornea starting from superior aspect and completing the circle over the next five years; intermittent cerebellar signs in 1985 and frank convulsions in 1988. In 1988, he also developed frequent loose stools with blood and mucus, not associated with evidence of infection. By 1989, he developed diffuse pulmonary infiltrates (*Fig. 1*), generalized lymphadenopathy and clubbing. He also developed marked skin pigmentation on lower extremities. In December 1989, he developed congestive cardiac failure, requiring hospitalization. His ECG revealed poor left ventricular function. He expired in June 1990, at the age of 24



*Fig. 1. Chest X-ray revealing bilateral diffuse pulmonary infiltrates*

years. He was a fully grown adult with normally developed, secondary sexual characteristics.

*Case 2:* The elder sibling of Case 1 was noticed to have hepatosplenomegaly at 9 years of age. He was diagnosed to have Niemann Pick disease on bone marrow and liver biopsies at the age of 14 years, during family screening. His fundus examination revealed grayish white areola at the macula and had no neurological manifestation at that time. He studied upto 8th standard. However, he developed deterioration of mental milestones at 15 years, cerebellar signs and corneal deposits at 23 years, and one episode of diarrhea with blood and mucus at 29 years. At present he is 30 years, has jerky movements of hands and feet, incoherent speech, poor concentration and memory, but no frank convulsions at yet. He has no respiratory or cardiac problems.

### Discussion

NPD has recently been reclassified into two broad Groups-I and II. Type I includes patients who are sphingomyelinase deficient (with activity less than 10% of normal) and predominant sphingomyelin and cholesterol deposits (as in our case); irrespective of neurological manifestations. Included in type H are a wide spectrum of patients with visceral or neurovisceral lipidosis with sphingomyelin deposition being less than other lipids and in whom exact nature of defect is not known. Each group is further subdivided into Acute (A), Subacute (S) and Chronic (C). Acute forms present in early infancy with rapid deterioration to death by 6 years of age. Chronic forms are usually first detected in adulthood(2).

Subacute forms develop visceral changes in early infancy or childhood, usually splenomegaly followed by hepatomegaly, but

progress slowly as in our case. In these early onset cases, the lung fields show diffuse infiltrates contributing to respiratory problems such as asthma and infections as in first sib. These patients show marked phenotypic heterogeneity particularly with respect to the nature, extent and temporal sequence of nervous system involvement. Various manifestations reported include mental retardation, cerebellar ataxia or extrapyramidal manifestations, or more than one manifestation. Various ocular changes such as macular halos, cherry red spot and corneal deposits may be the only evidence of nervous system involvement(2).

Management of these patients is mainly symptomatic. Replacement of enzyme sphingomyelinase by repeated implantation of human amnion sheets has been tried with promising results. Implantation of pure epithelial cells separated from other cell types of the amnion may avoid the risk of host versus graft rejection(3). Antenatal diagnosis is possible by enzyme estimation(2).

### Acknowledgements

The authors thank Dr. (Mrs) P.M. Pai, Dean, K.E.M. Hospital and Seth G.S. Medical College for granting us the permission to publish this case report.

### REFERENCES

1. Shah MD, Desai AP, Jain MK, Kulkarni V, Patel P, Waradkar AM. Niemann-Pick Disease with oculoneural involvement. *Indian Pediatr* 1983, 20: 521-522.
2. Spence MW, Challahan JW. Sphingomyelin-cholesterol lipidosis: The Niemann-Pick group of disease. *In: The Metabolic Basis of Inherited Disease*, 6th edn. Eds Scriver CR, Beaudet AL, Sly WS, Valle D. New York, McGraw - Hill Publication 1989, II: 1655-1676.

3. Scagginate B, Pineschi A, Sustersich M, Andolina M, Agostri E, Romeo D. Successful therapy of Niemann-Pick Dis-

ease by repeated implanon of human amniotic membrane. *Transplantation* 1987, 44: 59-61.

## Sirenomelia with Spinabifida

**M.L. Kulkarni**  
**C. Sureshkumar**  
**P.S. Sindhur**

Sirenomelia is an exceptionally rare congenital malformation characterized by a single fused lower limb. This deformity is variably known as symmelia, sympodia monopodia, sympus and due to its resemblance to the mermaid of Greek and Roman mythology popularly also known as mermaid baby. Sirenomelia has prevalence of 1.5 - 4.2 cases per 100,000 births(1). About 300 cases of this lethal anomaly have been reported in the world literature(2). In India over the last 15 years, 8 reports have appeared describing this condition(3). Most of these reports have only given the description of the dysmorphism but not have made any attempt to study the possible pathogenesis of the syndrome. In the present report we have done a postmortem arteriogram study to find out the possible vascular abnormalities which are supposed to be one of the mechanisms

*From the Department of Pediatrics, J.J.M. Medical College, Davangere 577004, Karnataka.*

*Reprint requests: Prof. M.L. Kulkarni, 2373, M. C. C. 'A' Block, Davangere, Karnataka 577 004.*

*Received for publication: March 22, 1993;*

*Accepted: May 7, 1993*

in the causation of this disorder(4). We also describe and discuss the association of neural tube defects along with siernomelia.

### Case Report

A 23-year-old, gravida two, with 8 months amenorrhea was admitted with premature rupture of membranes and onset of labor pain. Her antenatal period was uneventful and there was no history of any drug intake. There was neither a past or a family history of malformations.

A 1.6 kg infant was born by breech delivery. The baby had severe birth asphyxia (Apgar score was 2 at 1 minute and 4 at 5 and 10 minutes). All attempts to resuscitate the baby failed and the baby died after 40 minutes. Physical examination of the infant showed soft tissue fusion in lower extremities except the feet (*Fig. 1*) The feet were normally formed with toes, normal in number and appearance. Genitalia was represented by a small bud like projection. The anal and urethral openings were absent. Umbilical cord showed a single umbilical artery. The child had normal upper half of the body. The placenta was normal.

Radiological studies demonstrated normal bony structures in the lower extremities and feet. There was bilateral dislocation of hip and crowding of ribs. All the cervical vertebrae and thoracic vertebrae T1 to T4 showed spinabifida defect. The heart was of normal size and lungs were hypoplastic (*Fig. 2*).