
Images in Clinical Practice

Rectal Polyp

A 7-year-old boy presented with painless bleeding per rectum which was bright red in color and small in amount. The duration of symptoms was 6 months. On examination he had mild anemia. Colonoscopy showed a pedunculated solitary rectal polyp at 7 cm from the anal verge (*Fig. 1*). Endoscopic polypectomy was done and histopathology revealed a juvenile polyp. The patient remained asymptomatic on follow up of 2 years.

Multiple Colonic Polyps

A 10-year-old girl was admitted with complaints of fresh bleeding per rectum of

6 months duration and anemia. Colonoscopy (*Fig. 2*) and barium enema showed multiple sessile polyps all over colon. Barium meal follow through and upper gastrointestinal endoscopy was normal. Histopathology revealed adenomatous nature of polyps. She was subjected to proctocolectomy and ileal pouch was constructed. On follow up this girl remained asymptomatic with frequency of 3-4 stools/day.

Duodenal Varix

An 11-year-old boy, diagnosed as a case of extrahepatic portal venous occlusion, presented with hematemesis and melena after obliteration of esophageal varices by endoscopic injection sclerotherapy. On examination, he had anemia and

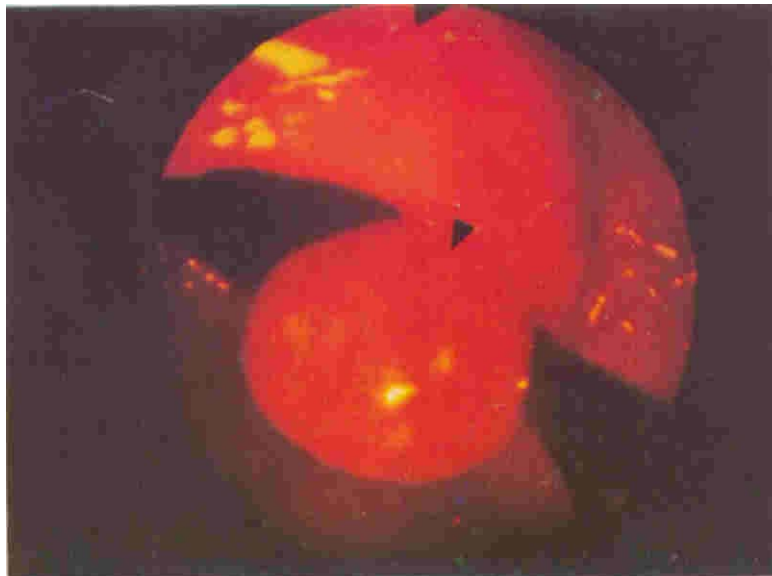


Fig. 1. Colonoscopic view of a child with rectal bleeding showing a solitary pedunculated polyp (arrow head) in rectum.

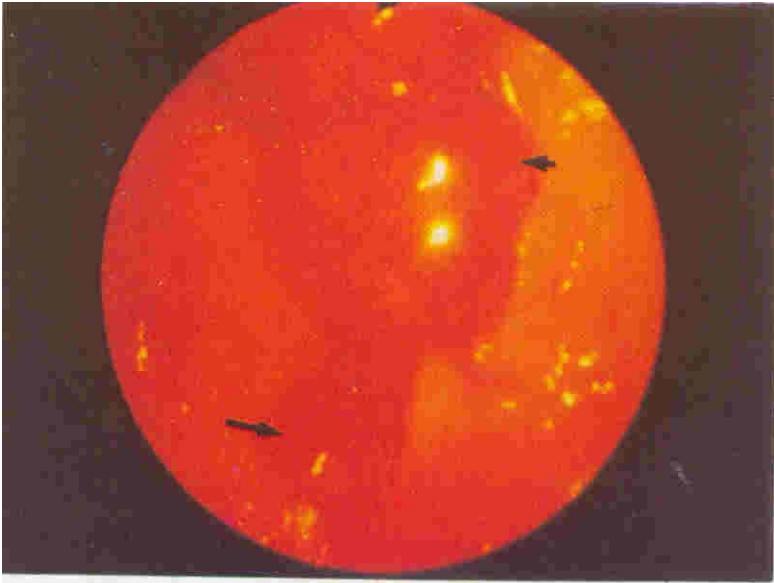


Fig. 2. Multiple polyps (arrows) on colonoscopic examination.

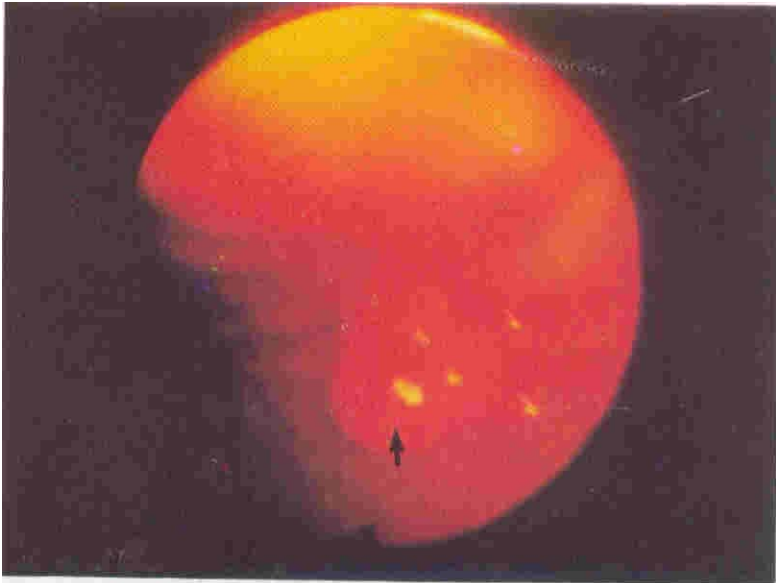

Fig. 3. Duodenal varix (arrow) in a child of portal hypertension presenting with hematemesis.

splenomegaly. There was evidence of hypersplenism. Upper gastrointestinal endoscopy showed no esophageal varices but there was an ectopic varix in the first part of duodenum (*Fig. 3*), which showed an adherent clot suggesting this to be the site of bleeding. Splenectomy and proximal lienorenal shunt was done, and the patient remained asymptomatic on follow-up.

S.K. Yachha,
Anshu Srivastava,
Pediatric Gastroenterology Unit,
Department of Gastroenterology,
Sanjay Gandhi Post Graduate
Institute of Medical Sciences,
Rai Bareilly Road,
Lucknow 226 014.