

Air Embolism in Assisted Ventilation

P.K. Rajiv
D.V. Raichur

Although air leak syndromes are not uncommon in a setting of assisted ventilation of non-compliant lungs using high pressures, air embolism (pneumatoxis arterialis) has been a rare but the most fatal type of air leak(1,2). We present here a case of air embolism in a preterm neonate.

Case Report

A 4-hour-old male preterm (gestational age 35 weeks) infant weighing 1.7 kg, resuscitated with endotracheal intubation 2 minutes after birth for apnea following "respiratory distress" since birth, presented to us with respiratory distress, central cyanosis, poor peripheral circulation and bilateral crepitations in the chest. Other examination findings were within normal limits. Hematological profile, plasma glucose, serum levels of sodium, potassium, calcium and cranial ultrasonography were normal. Chest X-ray revealed bilateral streaky shadows spreading peripherally from hila of the lungs. An arterial blood gas analysis (ABG) obtained from an indwelling (R) Radial Arterial catheter with an FiO_2 of 0.4 showed a pH-7.382, PaO_2 -92.9 mmHg, PaCO_2 -24.5 mmHg and HCO_3 -14.3 mmol/L. The baby was treated with 40% oxygen inhalation by head box, intra-

venous fluids, antibacterials, Dobutamine infusion, Vitamin K and Calcium gluconate. Continuous pulse oximetry and respiratory monitoring was done. Monitoring of non-invasive blood pressure (NIBP 4 hourly), urine output (hourly) and gastric aspirates were also done.

On the second day, the baby had increased retractions of the chest. Chest X-ray showed increase in perihilar shadows and ABG revealed a pH-7.309, PaO_2 -57.2 mmHg, PaCO_2 -40.0 mmHg and HCO_3 -23.6 mmol/L. The baby was given a trial of Continuous Positive Airway Pressure (CPAP) before starting Intermittent Mandatory Ventilation (IMV) for continued rise in PaCO_2 . ABG and chest X-ray were monitored periodically along with clinical examination to adjust the ventilatory settings and to assess the lungs. The lungs were non-compliant with a short time-constant requiring a Peak Inspiratory Pressure (PIP) of 20 cm H_2O and a Positive End-Expiratory Pressure (PEEP) of 4 cm H_2O , initially to maintain acceptable blood gas levels. During the following days, the baby's lungs continued to require relatively high pressures and an attempt to reduce PEEP and PIP failed due to deterioration in PaO_2 and PaCO_2 . Serial chest X-rays revealed a gradually extending bronchopneumonia. Blood culture done on the first day was negative. Despite administration of higher generation antibacterials, the lungs did not improve. By the tenth day, the requirement for PIP and PEEP increased gradually to 30-40 cm H_2O and 5 cm H_2O , respectively due to reduced compliance of the lungs as evidenced by reduced chest movements (after ensuring a fully patent endotracheal tube) to improve oxygen saturation beyond 90%. Later, sudden deterioration occurred on pulse oximetry followed by appearance of cyanosis clinically. While a sample was being taken for ABG from the arterial cannula, transillumination was performed

From the Departments of Perinatology and Pediatrics, P.V.S. Memorial Hospital 682 017, Kochi

Reprint requests: Dr. P.K. Rajiv, Head of Perinatal Medicine, Abishek Pediatric Foundation, P.V.S. Memorial Hospital, Kochi 682 017.

*Manuscript Received: April 17, 1997;
Initial review completed: May 19, 1997;
Revision Accepted: August 26, 1997*

CASE REPORTS

by fiberoptic light and a (R) sided pneumothorax was detected. It was treated immediately with needle aspiration followed by intercostal tube insertion. During the next 30 minutes, the saturation showed marked improvement but again chest movement decreased and saturation fell below 88% steadily. Pressures were increased to 40/5 to get acceptable saturation levels beyond 90% and effective chest movement. However, the baby again had

an abrupt desaturation on pulse oximetry followed instantaneously by undetectable peripheral pulses. Transillumination was done on the (L) side which was negative and wet film of an X-ray taken immediately by portable X-ray machine revealed gas in all chambers of the heart, aorta and its branches (including branchial and femoral) arteries, inferior vena cava, hepatic and portal veins, and internal jugular veins (*Fig. 1*). Soon bradycardia and cardiac

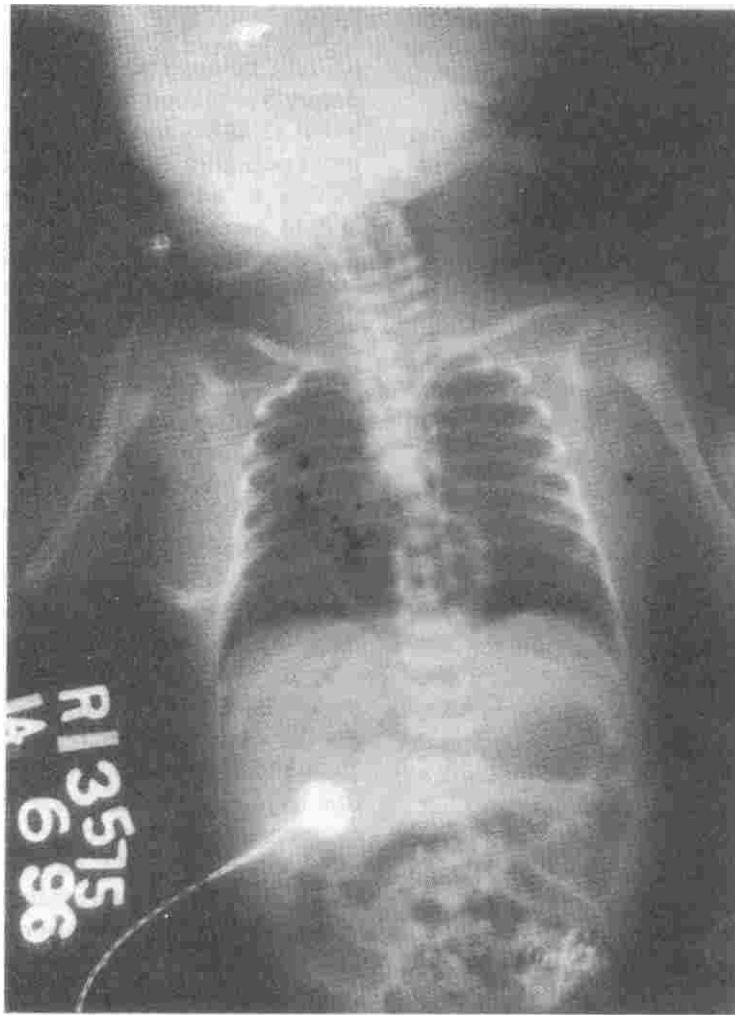


Fig. 1. X-ray chest of the baby.

arrest developed. All attempts at resuscitation failed and the baby expired.

Discussion

Air leak syndrome has become the most life-threatening complication of assisted ventilation(1). Air embolism, as a rare type of air leak, has occurred in the past during assisted ventilation with high pressures(3-6). When high PIP and PEEP are used, most of the air leaks occur due to alveolar rupture and spread of air through perivascular sheaths. However, air embolism is supposed to occur when due to a high intralveolar pressure, air is injected directly into the pulmonary capillaries at the time of alveolar rupture(1,6). Another possibility is spread through pulmonary lymphatics(7).

Clinically air embolism occurring during assisted ventilation presents with abrupt onset of peripheral circulatory collapse, bradycardia and cyanosis or pallor(1,2). Other forms of air leaks co-exist with air embolism(4). The diagnosis is made by finding the gas in chambers of the heart and major vessels, as was seen in the present case or by withdrawal of alternating segments of gas and blood from an umbilical arterial catheter. There is no effective treatment and the outcome is usually fatal(1,2,4).

High Frequency Ventilation (High Frequency Oscillatory Ventilation) is indicated once there is failure of conventional venti-

lation or there is development of pulmonary air leak syndrome. The greatest advantage of this modality is that at a lower mean airway pressure effective CO₂ washdown can be achieved.

REFERENCES

1. Korones SB. Extraneous air syndromes. *In: Assisted Ventilation of the Neonate*, 2nd edn, Eds. Goldsmith JP, Karotkin EH Philadelphia, W.B. Saunders Co, 1988; pp 255-264.
2. Kliegman RM. Extrapulmonary extravasation of air. *In: Nelson Text Book of Pediatrics*. Eds. Behrman RE, Kliegman RM, Arvin AM Philadelphia, W.B. Saunders Co, 1996; pp 488-489.
3. Lubens P, Jubelirer D, Steichen JJ. Massive intravascular air accumulation in a neonate. *J Pediatr* 1976; 88:1020-1022.
4. Bowen FW Jr, Chandra R, Avery BG. Pulmonary interstitial emphysema with gas embolism in hyaline membrane disease. *Am J Dis Child* 1973; 126:117-118.
5. Kogutt MS. Systemic air embolism secondary to respiratory therapy in the neonate: Six cases including one survivor. *Am J Roent* 1978; 131: 425-429.
6. Gregory GA, Tooley WH. Gas embolism in hyaline membrane disease. *N Engl J Med* 1970; 280:1141-1143.
7. Booth TN, Allen BA, Royal SA. Lymphatic air embolism: A new hypothesis regarding the pathogenesis of neonatal systemic air embolism. *Pediatr Radiol* 1995; 25 (Suppl 1): S220-S227.