REFERENCES

1. Sommer A, Tarwotjo I, Hussaini G, Susanto D, Soegiharto T. Incidence, prevalence and scale of blinding malnutrition. Lancet 1981, 27: 1407-1408.
2. Sommer A. Vitamin A deficiency and xerophthalmia. Arch Opthalmol 1990, 108: 343-344.
3. Rahamathullaji L, Underwood BA, Thulasiraj RD, *et al.* Reduced mortality among children in southern India receiving a small weekly dose of vitamin A. N Eng J Med 1990, 323: 929-935.
4. Pratinidhi AK, Shah U. Magnitude of vitamin A deficiency in primary school children of Sirur: A chronically drought affected area. Indian J Pediatr 1984, 51: 423-426.
5. Desai NC, Lohiya S, Keshan S, Nag V. Xerophthalmia in school children. J Indian Med Assoc 1989, 87: 209-211.
6. Solon FS, Popkin BM, Fernandez TL, Latham MC. Vitamin A deficiency in the Philippines: A study of xerophthalmia in Cebu. Am J Clin Nutr 1978, 31: 360-368.
7. Sharma RG, Mishra YC, Vennal GL, *et al.* Survey of ocular diseases in arid zone (Jaisalmer) with special reference to vitamin A. Indian J Opthal 1983, 31: 429-433.
8. Garg S, Nayar S, Garg A, Sane S. Vitamin A deficiency in pre-school children. Indian Pediatr 1984, 21: 491-494.

Allergic Bronchopulmonary Aspergillosis with Clubbing and Cavitation

A. Shah
R. Bhagat
N. Panchal

Allergic bronchopulmonary aspergillosis (ABPA) is a chronic indolent disease which ranges from mild asthma to fatal destructive lung disorder. We describe a case of childhood ABPA who presented with recurrent pneumonia along with cavitation and clubbing. The rarity of reports of ABPA in the pediatric population of India prompted the present description.

Case Report

An 11-year-old boy was referred to our Institute for evaluation of recurrent pneumonia. His clinical course during the past two years was characterized by intermittent fever, episodic wheezing dyspnea along with productive cough associated with frequent hemoptysis. There was history of passage of brownish plugs with sputum. The patient had loss of weight and appetite. The child was first born of a non-consanguinous marriage with uneventful antenatal and postnatal periods and had normal milestones. He had received full immunization. There was no family history of diabetes, immunodeficiency disorders or congenital anomalies except bronchial asthma in a maternal uncle.

Chest roentgenograms over the past 2 years revealed transient pulmonary infiltrates with a cavity in the posterior segment of the right upper lobe. Peripheral eosinophilia varying from 8-19% of the total white cell counts was also recorded. One year prior to referral, in spite of repeated sputum stains and cultures being negative for *Mycobacterium tuberculosis*, the patient was initiated on antitubercular therapy in the form of streptomycin, isoniazid and ethambutol without relief.

From the Department of Clinical Research, Vallabhbhai Patel Chest Institute, University of Delhi, P.O. Box 2101, Delhi 110 007.

Received for publication: October 22, 1991; Accepted: May 22, 1992

On examination, the patient was afebrile and dyspneic with mild tachycardia. There was no cyanosis but symmetrical digital clubbing was observed. Apart from bilateral polyphonic rhonchi on auscultation, examination of the chest was unremarkable.

On presentation, the total white cell count was 9800/cu mm with 19% eosinophils. Pulmonary function test showed mild airway obstruction–FEV_1 947 ml, FVC 1240 ml (72% of normal) and FEV_1/FVC 79%. Several sputum stains and cultures were negative for *Mycobacterium tuberculosis* and other pyogenic organisms. The sweat chloride levels were 32 mEq/L while the blood sugar was 80 mg/dl. Intradermal challenge with extract of *Aspergillus fumigatus* and *A. flavus* obtained from the CSIR Centre for Biochemicals gave strong Types I and III reactions. Serum precipitins against above antigens were detected by Ouchterlony's double diffusion technique. Chest roentgenogram revealed a right perihilar consolidation and a prominent left hilum (*Fig. 1*) while a right sided bronchographic study showed classical central bronchiectasis with normal peripheral filling (*Fig. 2*).

The patient was diagnosed as having ABPA in view of history of asthma, history of expectoration of brownish plugs, atopic background–maternal uncle was an asthmatic, blood eosinophilia, transient pulmonary infiltrates, Types I and III cutaneous reactivity to *A. fumigatus* and *A. flavus* precipitating antibodies against *A. fumigatus* and *A. flavus* and central bronchiectasis with normal peripheral filling.

Within two weeks the patient responded to 10 mg prednisolone (0.5 mg/kg) once daily along with bronchodilators. Prednisolone was reduced to alternate days after two weeks of therapy. The chest

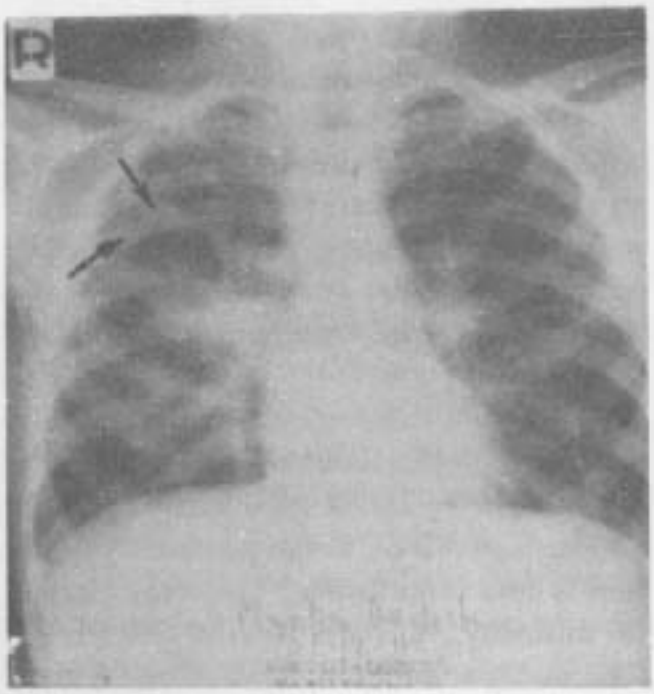

Fig. 1. Chest roentgenogram, showing right perihilar consolidation, cavity (arrow) in the right upper lobe and a prominent left hilar shadow.

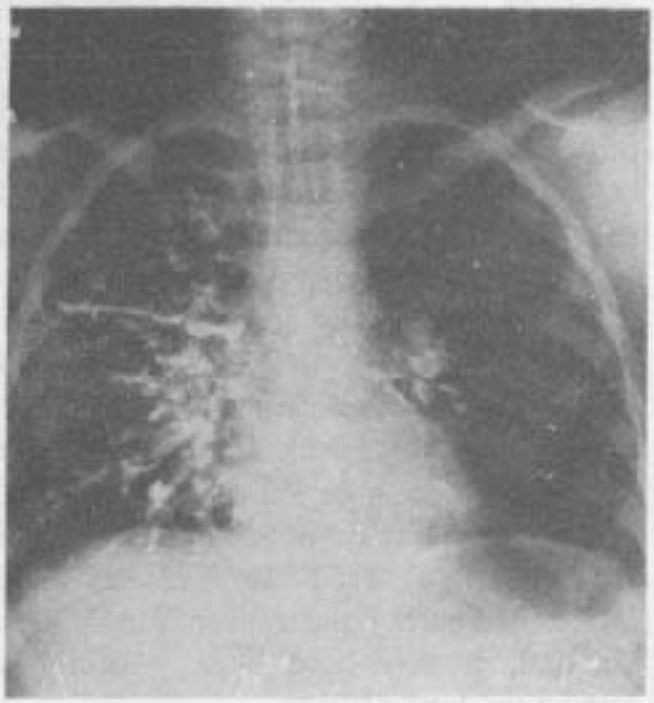

Fig. 2. Right sided bronchogram showing classical central bronchiectasis, with normal filling of peripheral bronchi.

roentgenogram showed remarkable clearing. Eosinophilia resolved while serum preci- pitins were no longer detectable. After 12 weeks of alternate day treatment, an exacerbation occurred when an attempt was made to taper prednisolone. The patient, however, remains asymtomatic with 7.5 mg prednisolone on alternate days.

Discussion

Although the onset of ABPA has been reported in an infant of 6 months(1), the diagnosis of ABPA in the pediatric population is less often made. This may be due to difficulty in fulfilling the criteria of Rosenberg *et al.*(2) in children and lack of awareness. In a study of 107 Indian children(3) with perinneal asthma, 35 with four or more of the above criteria were considered to have ABPA. However, demonstration of central bronchiectasis with normal peripheral filling, as seen in our patient, is a *sine qua non* for the diagnosis of ABPA(4).

Early diagnosis is vital to prevent irreversible damage, a point well illustrated by our case. The first radiological lesion was detected when the pateint was 9 years of age. Within a short span of 2 years, he presented to us with extensive central bronchiectasis and cavity formation demonstrating the rapidly destructive effect of ABPA on the lungs in pediatric patient. Cavitation, an uncommon feature of ABPA, may occur in 3% cases(5). Rarely, these cavities may be colonized by an aspergilloma(6). Had the diagnosis been established earlier and appropriate therapy initiated, it may have been possible to restrict the lung damage.

The presence of clubbing alongwith central bronchiectasis and other features of ABPA in a child raised the suspicion of associated cystic fibrosis which was ruled out by a negative sweat chloride test and normal peripheral filling on bronchogram. Clubbing has been observed in only 7% cases of ABPA(7), while associated hypertrophic osteoarthropathy has been reported in a single case so far(6). The patient's maternal uncle who also had asthma was screened for ABPA too as familial occurrence of ABPA, though rare, has also been reported(8).

Therapy with prednisolone remains the cornerstone of treatment of ABPA(4). Our patient had a remarkable symtomatic roentgenologic and serologic improvement with prednisolone. Unfortunately, we were unable to taper steroid to less than 7.5 mg on alternate days.

In our country, upper lobe pulmonary lesion presenting with cough, expectoration, fever and hemoptysis along with cavity formation is often associated with pulmonary tuberculosis, as it occurred in our patient. Failure to recognize ABPA as cause of this clinical presentation will inevitably result in diagnostic confusion, delay in initiation of appropriate therapy and increased morbidity.

Acknowledgement

The authors are thankful to Prof. H.S. Randhawa and Prof. Z.U. Khan for conducting the precipitin studies.

REFERENCES

1. Imbeau SA, Cohen M, Reed CE. Allergic bronchopulmonary aspergillosis in infants. Am J Dis Child 1977, 131: 1127-1130.
2. Rosenberg M, Patterson R, Mintzer R, Cooper BJ, Roberts M, Harris KE. Clinical and immunologic criteria for the diagnosis of allergic bronchopulmonary aspergillosis. Ann Intern Med 1977, 86: 405-414.
3. Chetty A, Bhargava S, Jain RK. Allergic bronchopulmonary aspergillosis in Indian

children with bronchial asthma. Ann Allergy 1985, 54: 46-49.

4. Greenberger PA. Allergic bronchopulmonary aspergillosis. *In:* Allergy-Principles and Practice, 3rd edn. Eds Middleton E Jr, Reed CE, Ellis EF, Franklin Adkinson N Jr, Yunginger JW. St Louis, The CV Mosby Company, 1988, pp 1219-1236.
5. Phelan MS, Kerr IH. Allergic bronchopulmonary aspergillosis: The radiological appearance during long term follow up. Clin Radiol 1984, 35: 385-392.
6. Shah A, Khan ZU, Chaturvedi S, Ramachandran S, Randhawa HS, Jaggi OP. Allergic bronchopulmonary aspergillosis with coexistent aspergilloma: A long term follow-up. J Asthma 1989, 26: 109-116.
7. McCarthy DS, Pepys J. Alllergic bronchopulmonany aspergillosis. Clinical immunology and clinical features. Clin Allergy 1971, 1: 261-286.
8. Shah A, Khan ZU, Chaturvedi S, Bazaz Malik G, Randhawa HS. Concomitant allergic *Aspergillus* sinusitis and allergic bronchopulmonary aspergillosis with familial occurrence of allergic bronchopulmonary aspergillosis. Ann Allergy 1990, 64: 507-512.

Biochemical Predictors of Mortality in Protein Energy Malnutrition

N. Sathy
K.E. Elizabeth
G. Letha Devi
J. Bai

Protein energy malnutrition (PEM) causes significant morbidity and mortality. Low serum albumin level has been reported to predict mortality(1). However, now-a-days since marasmus and undernutrition cases with normal serum albumin levels are more common(2), an attempt has been made to look into other probable predictors of mortality.

Material and Methods

One hundred and thirty six consecutive cases of PEM in the age group 1-24 months admitted to SAT Hospital, Medical College, Thiruvananthapuram were included in the study. Children with congenital anomalies, genetic and metabolic disorders, CNS infection and post measles cases were excluded from the study and also all the deaths due to other obvious infections. The anthropometric parameters were compared to NCHS standards. The biochemical parameters like serum protein, albumin, total lipids, total cholesterol and phospholipid levels were estimated using appropriately standardized techniques(3-7) and were compared to control values established using 25 blood samples collected from well nourished children belonging to the same age group. The mean age in the study was 15.3 ± 7.3 months and in the control it was 13.9 ± 7.4 months.

Results

Clinically 47 (35%) had marasmus, 10 (7%) had marasmic kwashiorkor, 6 (4%) had kwashiorkor and 73 (54%) had under nutrition. The mortality during the hospital stay was 11 (8%) and 8 (73%) of the deaths in those with severe PEM (weight <60%).

From the Department of Child Health and Biochemistry, Medical College, Thiruvananthapuram.

Reprint requests: Dr. N. Sathy, Professor and Head, Department of Child Health, SAT Hospital, Medical College, Thiruvanthapuram.

Received for publication: February 14, 1990; Accepted: June 3, 1992