BRIEF REPORTS

Double Aortic Arch Associated with Tetralogy of Fallot

A. Grover
H.N. Khattri
J.S. Varma
P.S. Bidwai

Double aortic arch (DAA), an uncommon condition, is rarely associated with other congenital cardiac malformations (1-3). Tetralogy of Fallot (TOF) seems to be the commonest heart disease associated with this anomaly(4). It is the rarity of this lesion and paucity of any report in Indian literature which made us write this case report of unusual combination of DAA and extreme pulmonary atretic variety of TOF.

Case Report

A 7-year-old female child, was referred to this institute for evaluation of cyanosis on exertion, fatiguability and squatting; even direct question did not reveal any symptoms of tracheoesophageal compression. Development and milestones were normal. Physical examination revealed generalized cyanosis and clubbing; normal neck veins, normal first heart sound and a single accentuated second heart sound. There was an aortic ejection click and Grade 1/6 ejection systolic murmur best heard in upper left sternal border. A continuous murmur was present in interscapular space.

X-ray chest (*Fig. 1*) showed normal heart size, a pulmonary bay and evidence of extensive bronchopulmonary collaterals. It was interpreted as showing evidence of right sided aortic arch. Electrocardiogram showed sinus rhythm, an axis of +120 degree and evidence of right ventricular hypertrophy.

Cardiac catheterisation revealed identical RV (right ventricle) and LV (left ventricle) systolic pressure (155 mm Hg), right atrial pressures were elevated, a=16 mm, v=14 mm, mean 11 mm. Aorta could not be entered from RV. Systemic arterial oxygen saturation (femoral artery) was 75%.

Multiple angiographic injections were done to demonstrate the anatomy. RV injection showed the dye going to aorta with double aortic arch; from each arch common carotid and subclavian arteries were arising (*Fig. 2*). Both arches united to form a single descending aorta. No passage of dye from RV to pulmonary artery was noticed. Dye from aorta showed extensive bronchopulmonary collaterals to both lungs. Angiographic diagnosis of pulmonary atretic variety of TOF with extensive collaterals with DAA was made.

The lesion was considered inoperable and the child was kept on follow-up. Over last one year her cyanosis had increased.

From the Department of Cardiology, Postgraduate Institute of Medical Education and Research, Chandigarh-160 012.

Reprint requests: Dr. H.N. Khattri, Associate Professor, Department of Cardiology, PGIMER, Chandigarh-160 012.

Received for publication October 26, 1987; Accepted December 10, 1990

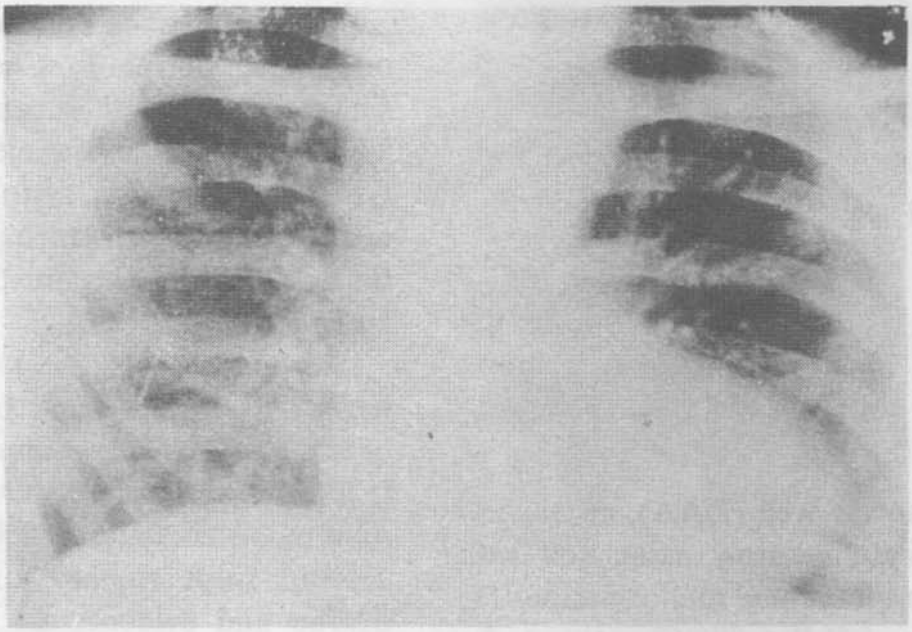

Fig. 1. X-ray chest showing normal heart size, a concave pulmonary bay and extensive bronchopulmonary collaterals.

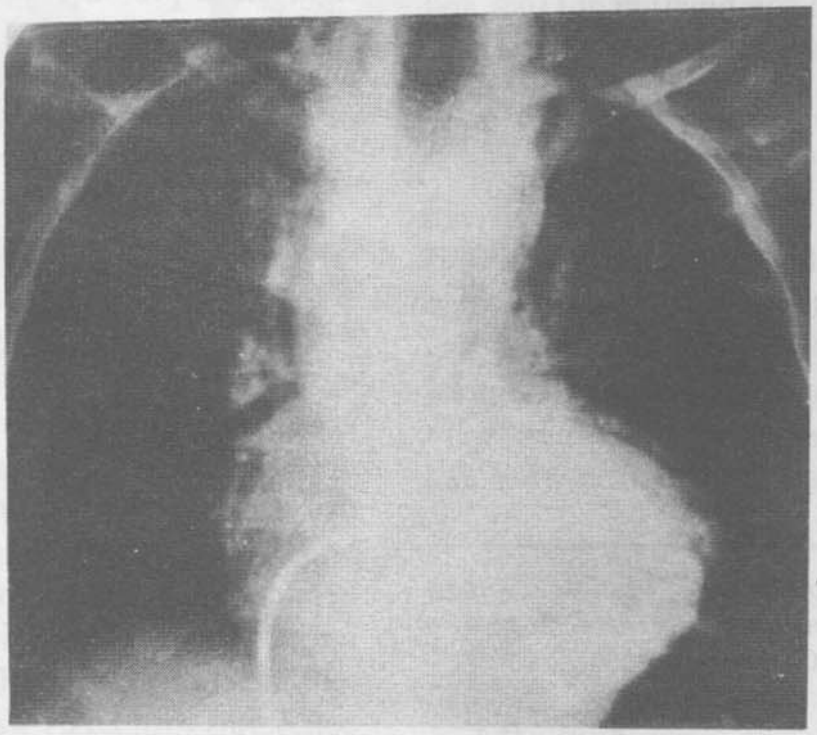

Fig. 2. Angiographic dye injected in right ventricle showing opacification of ascending aorta with double aortic arch. From each arch common carotid and subclavian arteries are arising. There is no passage of dye into pulmonary artery.

Discussion

The condition of double aortic arch was first described by Hommel in 1737(1). Wolman was first to realize its clinical importance and described a case in 1939(2). In patients with DAA, the ascending aorta arises normally but as it leaves the pericardium it divides into two arches-a left and a right aortic arch which join posteriorly to form the descending aorta. Double aortic arch, with both arches patent as an isolated anomaly, occurs uncommonly; the exact incidence is not known as some cases remain asymptomatic. It is rarely associated with other intracardiac anomalies(3). Higashino and Ruttenberg reviewed 16 cases of DAA associated with other congenital heart diseases reported till 1968(4). They showed that out of 16 cases, 14 had congenital cyanotic cardiac malformation (11 having TOF, 2 transposition of great vessels and 1 double outlet right ventricle); 2 had DAA associated with acyanotic cardiac malformation (one each of atrial septal defect and endocardial cushion defect).

Most patients with DAA present with symptoms and signs of tracheoesophageal constriction usually very early in life(5). The patient described in this report presented at the age of 7 years without any symptoms of tracheoesophageal constriction. The diagnosis can be suspected on plain *X*-ray showing widening of superior mediastinal shadow with bilateral tracheal indentation(6). Plain *X*-ray chest (*Fig. 1*) did not show tracheal indentation in our case. Diagnosis can be further supported by barium swallow showing indentation of esophagus at T_4 level(5). Angiography is essential to confirm the diagnosis and outline other associated intracardiac lesions.

Management of these cases depend on the degree of cyanosis and anatomy. Three cases of DAA with TOF described in literature underwent systemico-pulmonary anastomosis using one of the arches and connecting it to the pulmonary artery of the same side(7). We did not come across any case of DAA with TOF described in literature for which total correction had been attempted. In our patient, RV outflow was poorly developed and pulmonary arteries were of inadequate size. The lungs were mainly supplied through collaterals, hence no surgery could be attempted.

REFERENCES

1. Turner W. On irregularities of the pulmonary artery, arch of aorta and the primary branches of the arch. Dr. Foreign Med Chir Rev 1962, 30: 173-189.
2. Wolman I. Syndrome of constricting double aortic arch infancy. Report of a case. J Pediatr 1939, 14: 527-533.
3. Arciniegas E, Hakimi M, Hertzler JH, Farooki ZQ, Green EW. Surgical management of congenital vascular rings. J Thorac Cardiovasc Surg 1979, 77: 721-727.
4. Higashino SM, Ruttenberg HD. Double aortic arch with complete transposition of the great vessels. Brit Heart J 1968, 30: 579-581.
5. Chan TS. Young LW. Stridor due to double aortic arch anomaly. Am J Dis Child 1985, 139: 1047-1048.
6. Rajaram PC, Laksmikanthan C, Vaidyanathan N, Vasudevan S. Type D double aortic arch. Angiology 1983, 34: 597-603.
7. Binet JP, Langlols J. Aortic arch anomalies in children and infants. J Thorac Cardiovasc Surg 1977, 73: 248-252.