

Neonatal Dengue Infection

A 23-year-old woman with term pregnancy was admitted in our hospital with high fever, headache and myalgia for 7 days. Dengue NS1 antigen and IgM antibodies against dengue virus were positive, whereas IgG antibody test was negative. She delivered on the 3rd day of admission, and had severe postpartum hemorrhage, subconjunctival hemorrhage, and bilateral pleural effusion. Severe thrombocytopenia was present (platelet count $8 \times 10^9/L$). Repeated transfusions of blood, fresh frozen plasma and platelets were needed. Platelet count started rising on the 4th postnatal day, and after that she gradually recovered. A female baby was delivered vaginally on day-6 of maternal illness; birth weight was 2.7 kg, and APGAR scores were 7/10 and 9/10 at 1 and 5 minutes, respectively. Baby developed fever on day-3; the sepsis screen was negative. Dengue NS1 antigen was positive, and IgM and IgG antibody tests were negative. Blood culture was sterile. The fever initially settled but again appeared on day-10, and the infant had refusal of feeds, tachypnea, tachycardia, hepatomegaly and lethargy. Intravenous fluids were administered. Petechial lesions were noted on day-11; platelet count was $10 \times 10^9/L$. Platelet transfusions and supportive management were provided. Baby recovered well and was discharged on

day-20 of life on breast feeds.

Dengue fever presenting in neonatal period is unusual [1-3]. During the dengue fever epidemics, if a pregnant woman gets primary infection in late pregnancy and delivers at the height of viremia, both the mother and newborn are at risk of life-threatening complications [4]. A newborn with dengue infection should be vigilantly monitored for the warning signs well into the second week of life before being considered for discharge, especially during epidemics.

SRIRAM POTHAPREGADA

*Department of Pediatrics,
Indira Gandhi Medical College and Research Institute,
Puducherry, India.
psriram_ped@yahoo.co.in*

REFERENCES

1. Choudhary SP, Gupta RK, Kishan J. Dengue shock syndrome in newborn-A case series. *Indian Pediatr.* 2004;41:397-9.
2. Petdachal W, Sila'on J, Nimmannitya S, Nisalak A. Neonatal dengue infection: report of dengue fever in a 1-day old infant. *Southeast Asian J Trop Med Public Health.* 2004;35:403-7.
3. Chin PS, Khoo APC, Asma Hani AW, Chem YK, Norijah I, Chua KB. Acute dengue in neonate secondary to perinatal transmission. *Med J Malaysia.* 2008;63:265-6.
4. Maroun SL, Marliere RC, Barcellus RC, Barbosa CN, Ramos JR, Moreira ME, *et al.* Case report: vertical dengue infection. *J Pediatr (Rio J).* 2008;84:556-9.

Bilateral Exudative Retinal Detachment in Septo-Optic Dysplasia

A borderline premature infant was referred to us for routine ophthalmological examination because routine antenatal ultrasound scan showed unilateral ventriculomegaly. Initial examination revealed unremarkable anterior segments, bilateral inferior optic disc coloboma with subretinal fluid, and white fleck deposits at inferior retina. At nine months of age, nystagmus was detected; left eye was microphthalmic and esotropic – about 30° by Hirschberg estimation. Fundus showed bilateral pale optic discs with inferior optic disc coloboma, macular hypoplasia, nasal retinal detachment (RD) not involving macular in right eye (**Web Fig. 1a**), and fully detached retina in left eye (**Web Fig. 1b**). No

other family member had a similar problem. Clinical examination during initial presentation revealed subtle dysmorphic features, frontal bossing, prominent occiput, undescended testes, and micropenis (1.5 cm). Patient had

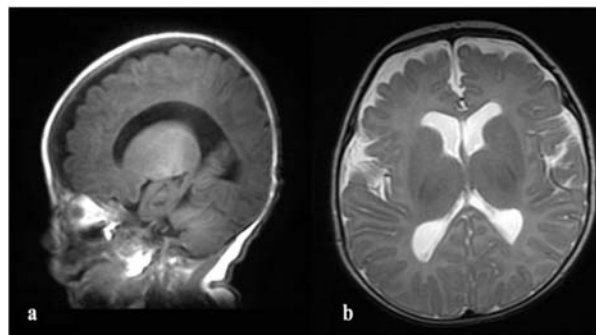


FIG. 1 Magnetic resonance image (MRI) sagittal plane (a) showing absence of corpus callosum, and axial plane (b) showing mild ventriculomegaly.