

Post Kala-azar Dermal Leishmaniasis: Macular Variety

A 7-year-old boy presented with numerous asymptomatic whitish flat lesions of varying sizes over the whole body for last two years. Patient was diagnosed as kala-azar about 3 years previously, and was treated suboptimally. There was no other systemic complaints like fever, pain abdomen or photosensitivity. On examination, there were asymptomatic hypopigmented macules and patches over the face (**Fig. 1**), trunk and extremities (**Fig 2**). There was no evidence of any scaling, erythema, itching sensation or photosensitivity. There were no mucocutaneous abnormalities, and lymphadenopathy, hepatosplenomegaly or any other systemic abnormalities. Slit skin smear from the lesions demonstrated the *Leishmania donorexi*; parasites and ELISA demonstrated the antibody in blood against the parasites. A diagnosis of post kala-azar dermal leishmaniasis was made (macular variety).

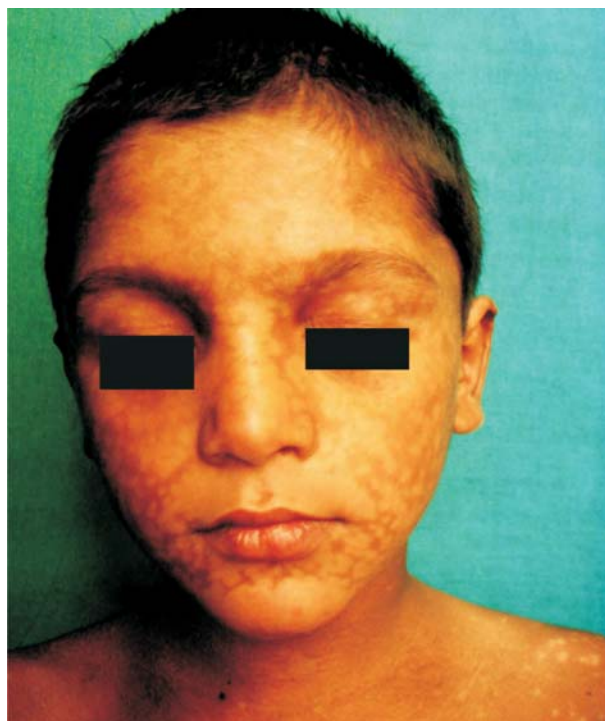

FIG. 1 Hypopigmented macules and patches over face.

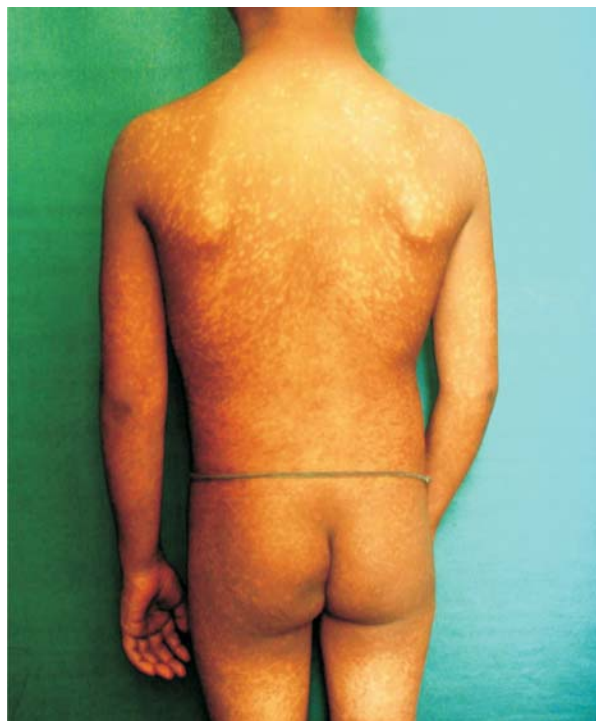


FIG. 2 Hypopigmented macules and patches over trunk and extremities (back).

About 1-2 years after recovery from kala-azar, post kala-azar dermal leishmaniasis (PKDL) develops as hypopigmented macules and patches over face and limbs. It gradually develops into papules, plaques and nodules. Macular variety of PKDL has the differentials of pityriasis versicolor (asymptomatic or mildly pruritic scaly hypopigmented patches over upper back, neck, chest, upper arms, early vitiligo (hypopigmented patches with scalloped margin), lepromatous leprosy, post inflammatory hypopigmentation following pityriasis rosea, lichen sclerosus et atrophicus, nevus depigmentosus (congenital hypopigmented nevus), nevus anemicus (hypopigmented patch because of increased sensitivity to endogenous catecholamines and subsequent vasoconstriction in that area). He was treated with amphotericin B injection (1 mg/kg/day) for 3 cycles of 20 days and the lesions started to heal slowly. Microbiological cure was demonstrated by polymerase chain reaction (PCR).

*ANIRBAN DAS AND TUSHAR KANTI SARKAR
 Department of Dermatology,
 Medical College and Hospital, Kolkata 700 073, India.
 *dr.anirban23@gmail.com