

cosmetic reasons. Some lesions improve with topical retinoic acid, salicylic acid, or ammonium lactate lotion. Laser treatment using carbon dioxide laser or Erbium YAG laser may be used.

DIPTI DAS, ANUPAM DAS AND NILAY KANTI DAS

*Department of Dermatology
Medical College and Hospital, Kolkata, West Bengal, India.
anupamdadr@gmail.com*

Benign Migratory Glossitis

A 9-year-old girl presented with complaints of burning sensation particularly with hot and spicy foods, and white lesion over tongue since 15 days. Review of her medical history revealed that she had similar complaints in the past which wane off without significant morbidity. She appeared normal, healthy, and well-developed. There were no abnormal extraoral clinical findings. Intraoral examination revealed a good oral hygiene, and no evidence of inflammation. The dorsum of tongue revealed irregular, circumscribed erythematous areas devoid of filiform papilla (**Fig. 1**). The lesions had raised white margins that could not be scraped off. These were surrounded a yellowish hyperkeratotic lesion on the posterior aspect. Lesions were migrating across the tongue by healing on one edge while extending on another. The regions were non-tender, no evidence of leukoplakia or white curd-like pseudomembranes. Other systemic examination and serological investigations were within normal limit. On the basis of history and clinical examination, provisional diagnosis of “benign migratory glossitis” (BMG) was made. Histological examination shows parakeratosis, acanthosis, dense polymorphonuclear infiltration, with Munro abscess in the epidermis. Exfoliative cytology was negative for *Candida*. On clinical and histopathological findings, diagnosis of benign migratory glossitis was made and she has been prescribed antihistamines and topical corticosteroid. Her mother was counselled regarding the benign nature of the disease.

Benign migratory glossitis (BMG), (geographic tongue, erythema migrans, annulus migrans and wandering rash of the tongue) is uncommon and occurs in up to 2% of the population. The exact cause is unknown but association with HLA-B15 suggest role of heredity in etiology of BMG. Attempts have been made to demonstrate an association between various systemic and/or psychological conditions and BMG but definitive causal relationship has not been established yet. BMG is

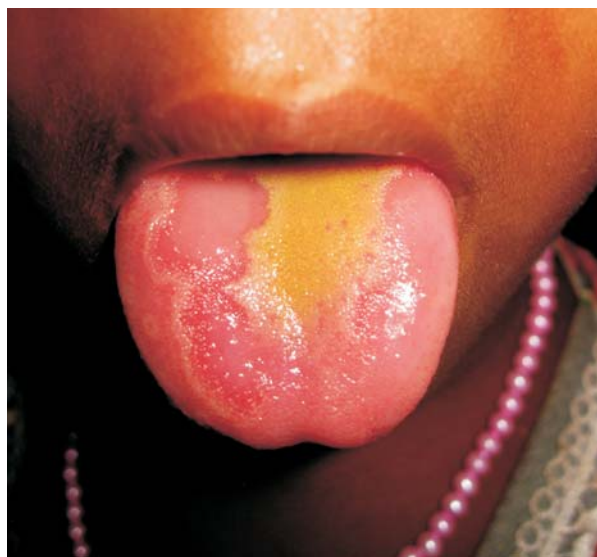


Fig. 1 Irregular, circumscribed erythematous areas with yellowish hyperkeratosis.

characterized by irregularly shaped erythematous, map-like smooth swollen patches bounded by slightly elevated keratotic band occurring mostly on dorsum of tongue, extending onto the lateral borders. The location and pattern undergo change over time, thereby accounting for the name “migratory.” Differentials include candidiasis (white exudate resembling cottage cheese along with a moist surface, growth of *Candida* positive on culture), leukoplakia (homogeneous or speckled white plaque that usually has sharply demarcated borders), psoriasis (usually associated with typical cutaneous lesions) and drug reaction. It is a benign condition that usually resolves itself without causing any problem. Discomfort may be treated with an antihistaminic, mouth gargle or rinse containing antiseptic and anaesthetic agents and topical corticosteroids.

**DHIRAJ KUMAR, ANUPAM DAS AND
RAMESH CHANDRA GHARAMI**

*Department of Dermatology
Medical College and Hospital, Kolkata,
West Bengal, India.
anupamdadr@gmail.com*