

## Kniest Syndrome

**Subramanian Subramanian**  
**Shivanand Gamanagatti**  
**Anindita Sinha**  
**Raju Sampangi\***

*A 12-year-old male child presented with bilateral visual loss and short stature. He had dysmorphic faces, barrel shaped chest and short limbs with enlarged peripheral joints. In addition he had bilateral retinal detachment with secondary cataract formation. Skeletal survey revealed irregular platyspondyly, hypoplastic femoral head and enlarged epiphysis of long bones with cloud like calcification. Radiological features were diagnostic of Kniest syndrome. The child underwent pars plana lensectomy and a vitreo-retinal surgery with silicon oil infusion in the right eye for retinal detachment.*

**Key words:** Kniest syndrome, Retinal detachment.

Kniest syndrome was first described by Wilhelm Kniest in the year 1952(1). Children affected by this syndrome have round faces, barrel shaped kyphotic trunk, disproportionate dwarfism, and enlarged joints with restricted movements(2). They may present with visual loss due to retinal detachment and myopia or with recurrent otitis media(2). The disease is inherited in autosomal dominant manner. We present a rare case of Kniest syndrome with ocular involvement in this report.

### Case Report

A 12-year-old male child presented with loss of vision in both eyes and short stature. He had visual loss in left eye for four years and in the right eye for one year. He was born to non-consanguineous

parents and his siblings were normal. He had normal milestones and intelligence. On examination, the child had a flat round face with epicanthal folds, depressed nasal bridge, and high arched palate. The chest was barrel shaped and there was kyphoscoliosis in lower back (*Fig. 1*). The limbs were shortened and knee, elbow, wrist and ankle joints were enlarged with limited mobility. His height was only 104 cm. Based on the clinical features Moriquio's disease was suspected.

Ocular examination revealed bilateral cataract. The cornea was clear on slit lamp examination. The intraocular tension was normal. As the retina could not be evaluated due to the presence of cataract, sonogram was done. Ocular sonogram revealed funnel shaped retinal detachment in right eye and closed funnel retinal detachment in left eye.

Skeletal survey revealed irregular platyspondyly with scoliosis in the lumbar vertebra. The pubic bones were hypoplastic and pelvic inlet was smaller in size. The ossification centre for femoral head was smaller in size and fragmented. The epiphysis of the lower end of femur was enlarged and metaphysis was flared. Cloud like calcification was seen around the growth plate (*Fig. 2*). The epiphysis in elbow, wrist and ankle joints also showed similar change. Radiograph of hand revealed flattened epiphysis of metacarpal bones with enlargement of both ends of metacarpal and phalanges. Joint space was reduced in the small joints of hand. The skull radiograph was normal. The radiological features are diagnostic of Kniest syndrome. The child underwent pars plana lensectomy and a vitreo-retinal surgery with silicon oil infusion in the right eye for retinal detachment.

### Discussion

The differential diagnosis for the present patient with short trunk dwarfism and abnormal epiphysis included Moriquio's disease, Spondyloepiphyseal dysplasia (SED), Spondyloepimetaphyseal dysplasia (SEMD), Kniest syndrome and Metatropic dwarfism. Children affected by Moriquio's disease have short trunk dwarfism and normal intelligence similar to present patient. They may have minimal corneal clouding which was not seen in present patient. In addition, the radiographic features like flaring of ribs, flared iliac wings, steep acetabular roof and proximal pointing of metacarpal bones

---

*From the Department of Radiodiagnosis and Department of Ophthalmology\*, All India Institute of Medical Sciences, Ansari Nagar, New Delhi 110 029, India.*

*Correspondence to: Dr Subramanian Subramanian, Department of Radiodiagnosis, All India Institute of Medical Sciences, Ansari Nagar, New Delhi 110 029, India. E-mail: drsubbusmc@yahoo.co.in*

*Manuscript received: January 19, 2007;*

*Initial review completed: February 28, 2007;*

*Revision accepted: July 24, 2007.*

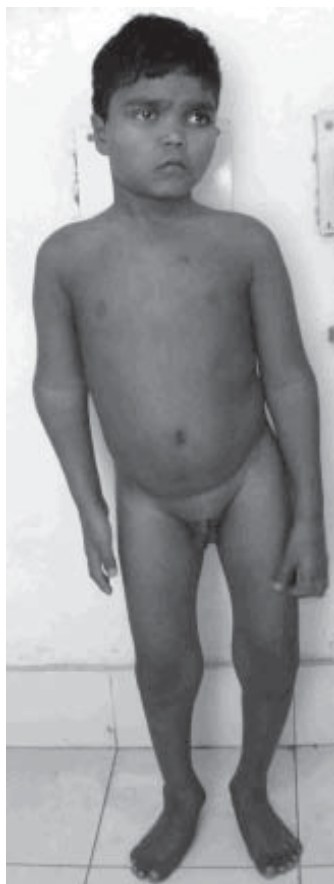

Fig. 1. Clinical photograph shows flat round face, enlarged peripheral joints and barrel shaped chest typical of Kniest Syndrome.

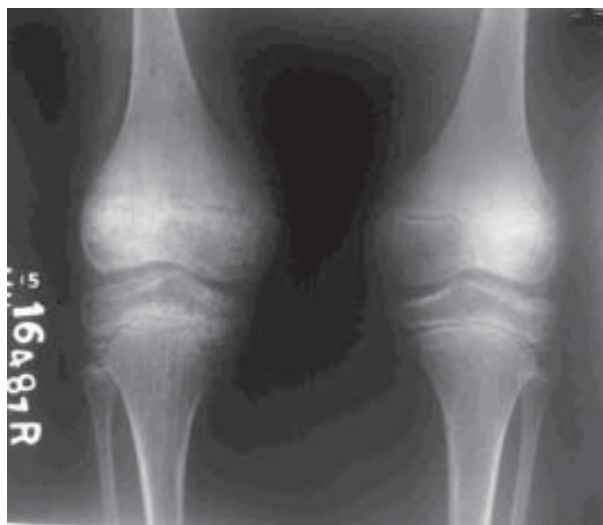


Fig. 2. Radiograph of knee shows enlarged epiphysis and flared metaphysis of the lower end of femur and upper end of tibia. Cloud like calcification is seen around the growth plate.

were not seen in the present patient. The present patient had enlarged epiphysis with cloud like calcification, platyspondyly and hypoplastic femoral head. Although platyspondyly and hypoplastic femoral head is seen in SED, SEMD and metatropic dwarfism, they usually have small normal appearing epiphysis(3). The metaphysis is abnormal and irregular in patients with SEMD. Only patients with Kniest syndrome have enlarged epiphysis with cloud like calcification. In addition they have characteristic findings in the hand radiograph which was seen in the present patient.

The common ocular manifestations in Kniest syndrome are vitreoretinal detachment and myopia(4). Other findings include cataract, dislocated lens and blepharoptosis. The present patient developed bilateral retinal detachment due to vitreous degeneration which was confirmed at surgery. Cataract formation was secondary to retinal detachment in the present patient. Regular ophthalmic examination is mandatory as they are prone to develop retinal detachment. Early detection of retinal detachment and surgical treatment may preserve useful vision in these patients(4).

Kniest syndrome should be suspected based on the clinical features and can be confirmed by its typical radiographic appearance. It should be differentiated from Moriquio's, SED, SEMD and Metatropic dwarfism. Early diagnosis and routine ophthalmic examination is essential in these patients to detect retinal detachment and to preserve useful vision in these patients.

*Contributors:* SS: Concept and design, acquisition of data, analysis and interpretation of data, Drafting of the manuscript (category I). SG: final approval of the version to be published (Category 3). AS: Drafting of the manuscript, critical revision of the manuscript for important intellectual content, literature review (category 2). RS: Concept and design, acquisition of data, analysis and interpretation of data, clinical management of patient (category I).

*Funding:* None.

*Competing interests:* None.

## REFERENCES

1. Kniest W. Zur Abgrenzung der Dysostosis enchondralis von der chondrodystrophie. *Ztschr. Kinderh* 1952; 70:633-640.
2. Lachman RS, Rimion DL, Hollister DW, Dorst JP,

- Siggers DC, McAlister W *et al.* The Kniest Syndrome. *Am J Roentgen* 1975;123:805-814.
3. Kozlowski K, Barylak A, Kobielow Z. Kniest syndrome. *Aust Radiol* 1977; 21:60-67.
  4. Maumenee IH, Traboulsi EI. The ocular findings in Kniest Dysplasia. *Am J Ophthal* 1985; 100:155-160.
  5. Menger SH, Mundlos S, Winterpacht A, Zabel B. Kniest dysplasia is caused by dominant collagen II (col2a1) mutations: parental somatic mosaicism manifesting as stickler phenotype and mild spondyloepiphyseal dysplasia. *Pediatr Radiol* 1994; 24:431-435.

## CINCA Syndrome

**Chetna Khemani**  
**Raju Khubchandani**

*CINCA syndrome is a genetic disorder characterized by early onset of recurrent fever, rash, progressive articular and neurological involvement. We report a 7-year-old girl with CINCA syndrome with an infrequent manifestation of retinal vasculitis and a relative paucity of neurological signs. She had a de novo F309S mutation in exon 3 of CIAS1 gene on chromosome 1. This is the first report of this entity from India.*

**Key words:** *CINCA syndrome, CIAS1 gene, retinal vasculitis.*

Chronic infantile neurological, cutaneous, articular (CINCA) syndrome or neonatal-onset multisystem inflammatory disease (NOMID) is a rare, genetic, autoinflammatory disorder associated with periodic fever characterized by seemingly unprovoked inflammation, in the absence of autoimmune or infective causes(1,2). It is caused by a mutation in the CIAS1 (Cold induced auto inflammatory syndrome-1) gene situated on chromosome 1(1,2). One case of an inherited

inflammatory disease in a kindred of north Indian descent has been reported in world literature(3). We report the first case of CINCA syndrome in Indian literature.

### Case Report

A 7-year-old girl was born, of a non-consanguineous marriage, by a normal delivery. A generalized urticarial rash was noticed since the second day of life. Throughout her infancy she was extremely irritable and resisted movement of her extremities. At 10 months of age, she developed recurrent febrile episodes with exacerbations of rash during these episodes. She had a delay in gross motor milestones and history of red eyes of 6 months duration.

She had sparse clinical records with multiple prescriptions of analgesics, local ointments, antibiotics and intermittent oral steroids. The patient's parents and 2 siblings were asymptomatic.

Her clinical picture consisted of failure to thrive (Wt 13.5 kg, Ht 102 cm, both <3rd percentile for age), pallor, lymphadenopathy, fine conjunctival nodules, generalized nodular urticarial pruritic rash, clubbing, frontal bossing, saddleback nose, left elbow arthritis with bilateral patellar overgrowth (*Fig 1*). Fundoscopy showed retinal vasculitis (*Fig. 2*). Systemic examination was unremarkable.

Hemogram revealed Hb of 6.9 g/dL, TLC 21,900 cells/cu mm, DLC N 82%, L 15%, E 2%, M 1%, platelet count 6.78 lakhs/cumm and ESR 110 mm/h. Urine routine was normal. Skin biopsy showed atrophic epidermis and dermal inflammation with perivascular neutrophilic infiltration with no granulomas. Serum angiotensin converting enzyme levels and chest radiograph were normal. The lower limb

*From the Pediatric Rheumatology Clinic, Jaslok Hospital & Research Center, Mumbai 400 016.*

*Correspondence to: Dr Raju Khubchandani, Consultant Pediatrician, Jaslok Hospital & Breach Candy Hospital, Mumbai, India.*

*E-mail: rajukhubchandani@yahoo.com*

*Manuscript received: March 28, 2007;*

*Initial review completed: May 10, 2007;*

*Revision accepted: July 31, 2007..*