

and red cells 8-10/HPF and a few epithelial and hyaline casts.

Discussion

Nephrosis or nephritis in congenital syphilis may be present at birth or may appear within one month. Presence of granular deposits IgG and C3, subepithelial electron dense deposits and elution of antitreponemal antibodies from glomerular deposits suggests an immune complex mediated pathogenesis(4).

Patients of syphilitic glomerulonephritis with azotemia, hematuria-glomerular proliferation, crescent formation and glomerulosclerosis usually carry a grave prognosis and the therapy may not alter the course of the disease(2). However, prognosis also depends on early initiation of therapy, the extent of glomerular damage and the age of child. According to Wiggelinkhuizen *et al.*(5), two younger infants aged 2 weeks and 2 months who were treated with penicillin showed clinical improvement and reversal of histological abnormalities.

Infants with nephritic or nephrotic syndrome should be screened for syphilis. Treatment with penicillin may result in resolution of biochemical abnormalities and clinical manifestations.

Acknowledgements

The authors wish to thank the Surgeon-Superintendent of SSKM Hospital, Calcutta for allowing them to utilize the hospital records and publish the article. They are also thankful to Dr. J. Bose, Assistant Professor, Department of Nephrology for doing the renal biopsy and giving advice in preparing the manuscript.

REFERENCES

1. Kaplan BS, Wiglesworth FW, Marks MI,

Drummond KN. The glomerulopathy of congenital syphilis— an immune deposit disease. *J Pediatr* 1972, 81: 1154-1156.

2. Yuceoglu AM, Sagel I, Tresser G, Wasserman E, Lange K. The glomerulopathy of congenital syphilis: A curable immune-deposit disease. *J Am Med Assoc* 1974, 229: 1085-1989.
3. Taitz LS, Isaacson C, Stein H. Acute nephritis associated with congenital syphilis. *Br Med J* 1961, 2: 152-153.
4. Gamble CN, Reardan JB. Immunopathogenesis of syphilitic glomerulonephritis: Elution of antitreponemal antibody from glomerular immune-complex deposits. *N Eng J Med* 1975, 292: 449-454.
5. Wiggelinkhuizen J, Kaschula ROC, Uys CJ, Kuijten RH, Dale J. Congenital syphilis and glomerulonephritis with evidence for immune pathogenesis. *Arch Dis Child* 1973, 48: 375-381.

Idiopathic Hypertrophic Osteoarthropathy

S.K. Puri
R. Kapoor
V. Baijal
M.M. Saha
B.K. Sharma

Hypertrophic osteoarthropathy (HOA) is a syndrome manifested by clubbing,

From the Departments of Radiology and Pediatrics, LNJP Hospital, New Delhi and Department of Radiology, Safdarjung Hospital, New Delhi.

Reprint requests: Dr. Sunil Kumar Puri, Assistant Professor, Radiology Department, G.B. Pant Hospital, New Delhi 110 002.

Received for publication: July 2, 1990;

Accepted: May 20, 1992

subperiosteal new bone formation and arthropathy(1). It usually occurs in the clinical setting of pulmonary neoplasms or other intra or extrathoracic disorders and is then called secondary HOA(2). In 3 to 5% of patients, no demonstrable cause can be found and the condition is, then, termed as idiopathic HOA(1). Idiopathic HOA is usually seen in adolescents and adults (adult variety), and is rare in children (childhood variety)(3). Only 14 cases of the 'childhood variety' have been reported so far(1,3-9).

The 'childhood' variety of idiopathic HOA is a self limiting disorder and is associated with characteristic skull changes in the form of delayed closure of sutures and presence of wormian bones(1,4). It has been reported that males are more frequently affected, the disease can be familial or sporadic and is associated with skin involvement(1,4).

We, recently encountered two children with idiopathic HOA and the review of pertinent literature revealed certain interesting observations.

Case Reports

Case 1:

A 1½-year-old girl was admitted with complaint of pain in both knee and elbow joints of two weeks duration. In addition, mild bowing of legs and thickening of the ends of fingers and toes were noticed by her parents since last six months. No family history of similar illness could be elicited.

Physical examination revealed clubbing of fingers and toes with no evidence of hyperhidrosis or any other skin lesion. Both knee, ankle and elbow joints were mildly tender with no evidence of inflammation, swelling or joint effusion. Anterior fontanelle was wide open (5.5 × 4.0 cm) but the head circumference was normal

and there was no evidence of hydrocephaly. Rest of the examination was unremarkable.

Routine hematological examination and blood biochemistry were within normal limits. X-rays of the skull showed large anterior fontanelle and multiple sutural bones (Fig. 1). X-rays of the limbs showed bilateral symmetrical, layered periosteal reaction along the diaphysis of all long bones (Figs. 2 & 3). X-rays of small bones of hands and feet, chest, spine and pelvis were normal. Skeletal survey of the other family members did not reveal any abnormality.

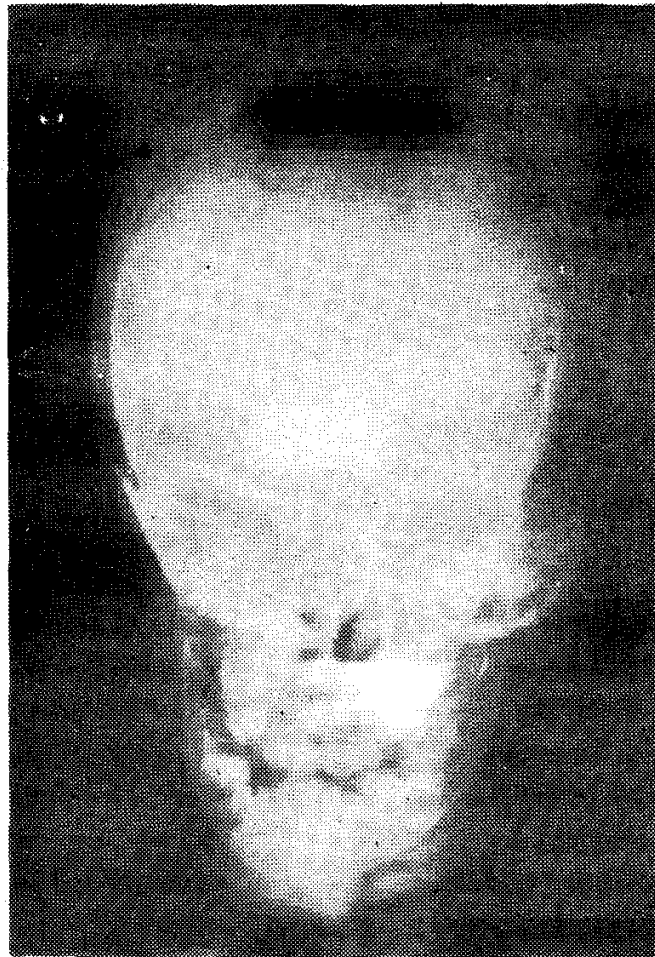


Fig 1. A-P skull radiograph shows a wide open anterior fontanelle and multiple Wormian bones.

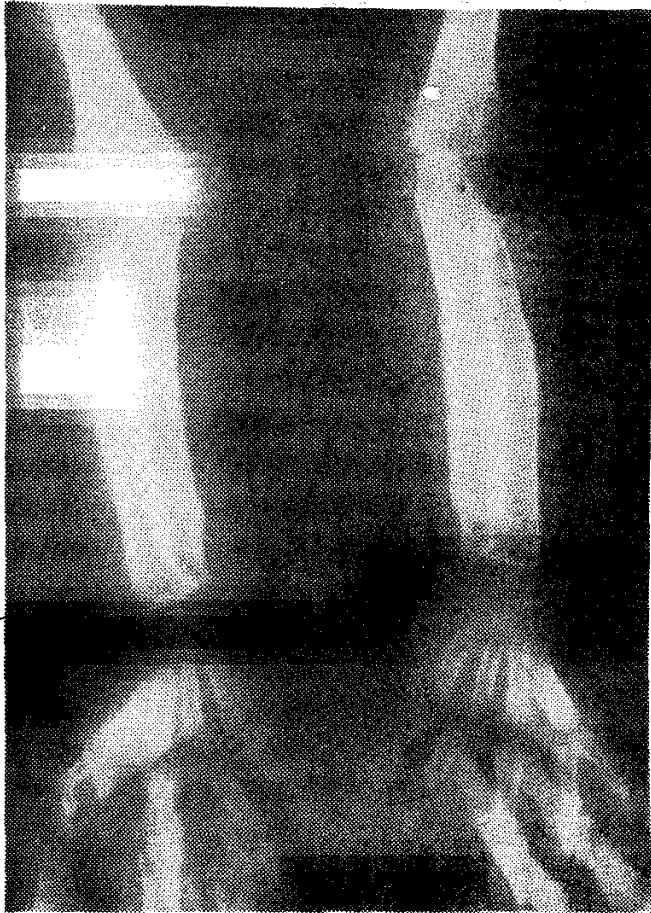


Fig 2. A-P radiograph of both forearms shows periosteal reaction along the shafts of radius and ulna.

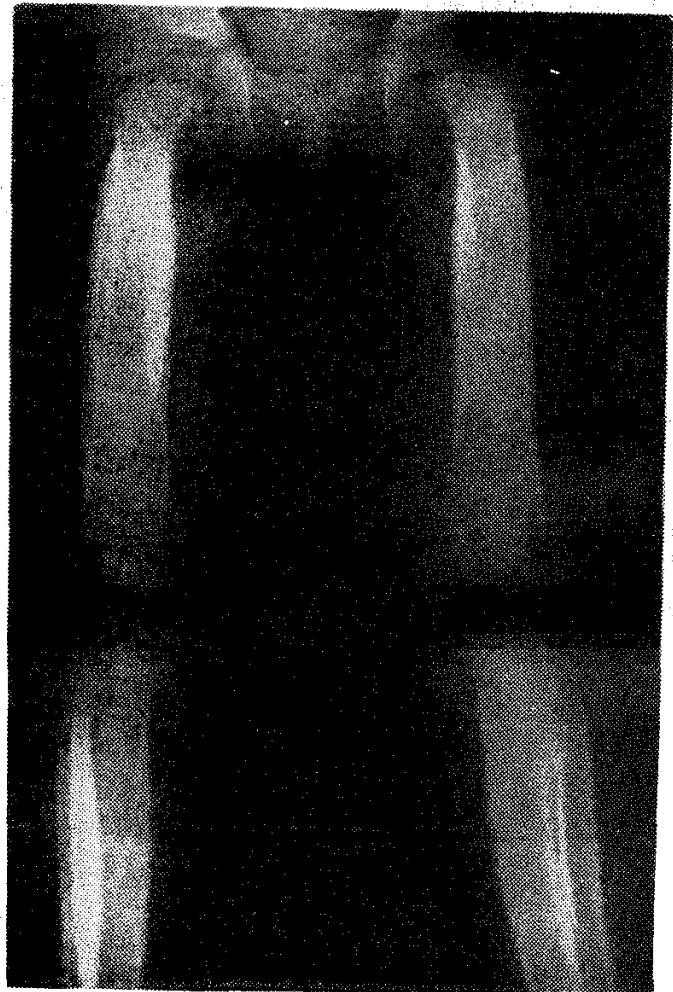


Fig 3. Lower extremity AP radiograph shows florid periosteal reaction along the diaphysis of long bones. Lateral bowing of left leg present.

Case 2:

A 4-year-old boy was admitted with complaints of recurrent swelling and pain in both knee and wrist joints since one year and failure of closure of anterior fontanelle. Both the parents, two elder brothers and a younger sister were all normal.

On examination, he was a malnourished child and had gross clubbing of the fingers and toes. No skin lesion could be detected. Non-tender synovial bogginess was present in both wrist and knee joints. There was no evidence of excessive sweating. Flexion contractures were present in both knee joints while no evidence of joint effusion was seen in any of the joints. Ante-

rior fontanelle measured 3.5×2.5 cm, head circumference was normal and there was no evidence of raised intracranial tension. Rest of the examination did not reveal any abnormality.

Routine hematological examination and blood biochemistry were normal. X-rays of the skull showed open anterior fontanelle and multiple Wormian bones. Radiographs of the extremities showed diaphyseal enlargement of all long bones except femora which had a cloak of periosteal new bone around the diaphysis and lower metaphysis. Outer borders of femur could just be made out inside the periosteal cloak. Chest X-ray showed widening of

both clavicles and no other abnormality. X-rays of the spine, pelvis and small bones of the hands and feet were normal. Skeletal survey of the other family members were normal.

Discussion

The 'childhood variety' of idiopathic HOA was first described by Currarino *et al.* in 1961(1). Since then, various authors have reported similar patients, documenting the clinical and radiological features including gradual regression of radiological changes with time(1,3-9).

Idiopathic HOA in children is said to affect males more frequently(1). However, we found that the females were affected twice more commonly (*Table I*).

Authors in the past have used the term 'familial idiopathic HOA' to denote this condition(1,6,8). However, we found that after the first family of three sisters described by Currarino *et al.*(1) and Chamberlain *et al.* (4), there have been only two other instances when multiple members of a family were affected(6,7). In contrast, a solitary family member was affected in six instances(4,5,8,9). Thus, the non-familial

TABLE—Clinical and Radiological Features in 16 Cases of Idiopathic HOA in Children..

Author(s)	Sex	Age (years)	Family history	Skin lesions	Slubbing	Periosteitis	Joint pains	Skull changes
Currarino <i>et al.</i> (1961)	F	8	+	Eczema	+	+	+	+
	F	NM	+	Seb. dermatitis				
Chamberlain <i>et al.</i> (1965)	F	3	+	Eczema	+	+	+	+
	F	9	-ve	Seb. dermatitis				
Cremin (1970)	F	11/2	-ve	-ve	+	+	+	+
	F	11/2	-ve	Eczema	+	+	+	+
Bartolozzi <i>et al.</i> (1975)	M	3	-ve	-ve	+	+	+	+
	M	3	-ve	-ve	+	+	+	+
Purohit <i>et al.</i> (1980)	M	8	-ve	-ve	+	+	+	-ve
	M	8	-ve	-ve	+	+	+	-ve
Reginato <i>et al.</i> (1982)	M	2	+	-ve	+	+	+	+
	F	4	+	-ve	+	+	+	+
	M	6	+	-ve	+	+	+	+
Diren <i>et al.</i> (1986)	F	11	+	-ve	+	+	+	-ve
	F	4	+	-ve	+	+	+	+
	F	10 mths	+	-ve	+	+	+	+
Davies <i>et al.</i> (1987)	NM	11/2	NM	NM	+	+	+	+
Present series	F	11/2	-ve	-ve	+	+	+	+
	M	4	-ve	-ve	+	+	+	+

NM: Not mentioned.

cases are twice more common than the familial ones. Till such time that the exact role of genetic factors in the etiopathogenesis of idiopathic HOA is decided, one should refrain from designating this condition as 'familial'.

The term pachydermoperiosteitis is used to denote those cases of idiopathic HOA which are associated with pachydermia. This manifests as thickening of the skin of the forehead and face with prominent folds and creases. It is a frequent occurrence in the 'adult variety' of idiopathic HOA(10,11). Since pachydermia was not seen in any of the reported patients of 'childhood variety', this term should be excluded from the terminology used to denote this condition(5). Even other skin lesions like eczema and sebaceous dermatitis are uncommon and were present only in 27% patients(1,4,8).

Differential diagnosis of the 'childhood variety' of idiopathic HOA includes secondary HOA, progressive diaphyseal dysplasia (Engelman's disease), congenital syphilis, idiopathic cortical hyperostosis (Caffey's disease) and hypervitaminosis A(12). However, radiologically the two conditions which can closely mimick idiopathic HOA in children are secondary HOA and Engelman's disease. But these can also be easily differentiated if one takes into account their clinical presentation along with the radiological features(12,13).

We conclude that idiopathic HOA in children is twice more common in females, is never associated with pachydermia, associated skin lesions are uncommon (27%) and its 'non-familial' form is twice more frequent than the 'familial form'. The use of terminology like 'familial idiopathic HOA' or 'idiopathic HOA without pachydermia' is not justified and should be discouraged.

REFERENCES

1. Currarino G, Tierney RC, Giesel RG, Weihl C. Familial idiopathic osteoarthropathy. *Am J Roentgenol Rad Ther Nucl Med* 1961, 85: 633-644.
2. Kozlowski K, Posen S. Idiopathic hypertrophic osteoarthropathy (Report of a further case with brief literature review). *Australas Radiol* 1983, 27: 291-294.
3. Davies RW, Hall CM, Apley AG. *Atlas of Skeletal Dysplasias*. Edinburgh, Churchill Livingstone, 1981, pp 512-515.
4. Chamberlain DS, Whitaker S, Silverman FN. Idiopathic osteoarthropathy and cranial defects in children (familial idiopathic osteoarthropathy). *Am J Roentgen* 1965, 93: 408-415.
5. Bartolozzi G, Bernini G, Maggini M. Hypertrophic osteoarthropathy without pachydermia. Idiopathic form. *Am J Dis Child* 1975, 129: 849-851.
6. Reginato AJ, Schiapachasse V, Guerrero R. Familial idiopathic hypertrophic osteoarthropathy and cranial suture defects in children. *Skeletal Radiol* 1982, 8: 105-109.
7. Diren HB, Kutluk, MT, Karabent A, Gocmen A, Adalioglu G, Kenanoglu A. Primary hypertrophic osteoarthropathy. *Pediatr Radiol* 1986, 16: 231-234.
8. Cremin BJ. Familial Idiopathic osteoarthropathy of children; a case report and progress. *Br J Radiol* 1970, 43: 568-570.
9. Purohit M, Saxena S, Garg A. Idiopathic hypertrophic osteoarthropathy. *Indian J Pediatr* 1980, 47: 165-167.
10. Yu YL, Turck WPG. Pachydermo periostosis (idiopathic hypertrophic osteoarthropathy). *Postgrad Med J* 1981, 57: 521-524.
11. Herbert DA, Fessel WJ. Idiopathic hypertrophic osteoarthropathy (pachyder-

- moperiostosis). West J Med 1981, 134: 354-357.
12. Fallon MD, Whyte MP, Murphy WA. Progressive diaphyseal dysplasia (Engelman's disease). J Bone Joint Surg 1980, 62A: 469.
 13. Salih SY, Halim MA. Idiopathic hypertrophic osteoarthropathy with severe recurrent arthritis in an African and a review of the literature. East Afr Med J 1978, 55: 31-35.

Schizencephaly—Imaging by MRI

P. Gulati
A. Jena
R. P. Tripathi
A. Sharma
Chandra

Schizencephaly is a congenital brain anomaly of neuronal migration characterized by holohemispheric grey matter lined clefts. As it forms a migrational disorder there may be associated anomalies. MRI due to its superior soft tissue contrast resolution and multiplanar imaging capability has been reported to be an ideal modality for total evaluation of this anomaly(1-5). We here describe our MRI findings in

From the NMR Research Centre, INMAS, Lucknow Marg, and G.B. Pant Hospital, New Delhi 110 002.

Reprint requests: Dr. Parveen Gulati, NMR Research Centre, INMAS, Lucknow Marg, and G.B. Pant Hospital, New Delhi 110 002.

Received for publication: November 6, 1991;

Accepted: July 6, 1992

three infants of this relatively uncommon condition.

Case Reports

A retrospective analysis of three infants of schizencephaly imaged on MRI was made. All the infants were studied by 1.5 Tesla superconducting system in head surface coil in supine position. Patients were sedated by syrup triclofos. A slice thickness of 5 mm and interslice gap of zero (for sagittal) or 50% (for axial) was used. The study was performed in spin echo sequence using TE/TR of 22/500-700 msec for T1 and TE/TR of 90/2000 msec for T2 images. Images were acquired on 256 × 256 matrix.

Case 1:

A 47-day-old female was referred with primary complaint of recurrent seizures. MRI revealed partial agenesis of right parietal lobe with complete clefting. The cleft was extending up to the lateral ventricle. There was a large cyst in the posterior fossa communicating with the fourth ventricle with almost complete agenesis of cerebellum (Dandy Walker cyst). There was associated partial agenesis of corpus callosum (*Fig. 1*).

Case 2:

A 4-year-old male presented with recurrent seizures and delayed milestones. MRI revealed bilateral schizencephaly with complete clefting on right and incomplete clefting on left side. Images also revealed heterotopia in the left parietal lobe giving same signal intensity as cortex in T1 as well as on T2 images. This was seen just medial to the site of clefting. There was evidence of polygyria also on right side. (*Fig. 2*).

Case 3:

MRI in a 2-year-old female child pre-