

- GM, Cahill Jr. GF, *et al.* Philadelphia, WB Saunder Co, 1989, pp 1065-1079.
2. Potts Jr JT. Diseases of parathyroid gland and other hypo and hypercalcemic disorders. *In: Harrison's Principles of Internal Medicine, Vol 2, 12th edn.* Eds Wilson JD, Braunwald E, Isselbacher KJ, *et al.* USA, McGraw Hill, Inc. 1991, pp 1918-1921.
  3. Drenzer MK, Nelson FA. Pseudohypoparathyroidism. *In: The Metabolic Basis of Inherited Disease, 5th edn.* Eds Stanbury JB, Wyngaarden JB, Fredrickson DS, Goldstein JL, Brown MS. USA, McGraw Hill Book Company, 1983, pp 1508-1527.
  4. Illum F, Dupont E. Prevalences of CT detected calcification in the basal ganglia in idiopathic hypoparathyroidism and pseudohypoparathyroidism. *Neuroradiology* 1985, 27: 32-37.
  5. Schaaf M, Payne CA. Effect of diphenylhydantoin and phenobarbital on overt and latent tetany, *New Engl J Med* 1966, 274: 1228-1233.
  6. Dudley AW Jr, Hawkins H. Mineralisation of the CNS in pseudohypoparathyroidism. *J Neural Neurosurg Psychiatry* 1970, 33: 147-152.

## Isosexual Male Precocity Due to a Leydig Cell Tumor

S.K. Advani  
N.M. Khan  
S.S. Borwankar  
P.B. Badhe  
B.K. Kulkarni  
S.D. Bhandarkar  
K.V. Moralwar

A ten-year-old boys presenting with isosexual precocity had a Leydig cell tumor of the right testis. The case is presented as

Leydig cell tumor is an uncommon cause of male precocious puberty(1,2). Further a Leydig cell tumor replacing the entire testis is very rare.

### Case Report

A ten-year-old boy was brought to the Puberty and Growth Clinic for tall stature and a large penis. These abnormalities had been noticed by the mother about 8 months earlier, and during the intervening 8 months, the patient developed a muscular, hirsute male habitus and had erections and nocturnal emissions. On examination, the height was 142 cm (>95th percentile of ICMR standard(3), height age: 14 years), weight 41.3 kg (weight age: 15 years) and BP 110/70 mm Hg. The pubic hair were of Tanner Stage P4, the stretched penile length was 7.5 cm and the penis was of adult thickness. The right testis was 10 ml in volume with a normal configuration, whereas the left testis was 2 ml in volume and normal in consistency. The build was muscular and there were hair on the face, chest and arms. There was no gynecomastia.

Investigations showed the following: bone age 15 years (Greulich and Pyle's standards)(4), serum testosterone 25 ng/ml (normal 0-0.6 ng/ml in children), serum estradiol 45 pg/ml (normal male 30 pg/ml), serum FSH 7.9 mIU/ml (Normal: male prepuberty: 1-9 mIU/ml—Leeco Std: 2nd IRP-78/549), serum LH 5 mIU/ml

*From the Departments of Endocrinology, Pediatric Surgery and Pathology, Seth G.S. Medical College and K.E.M. Hospital, Parel, Bombay 400 012.*

*Reprint requests: Dr. Naznin M. Khan, 17-C, Elco Arcade, Hill Road, Bandra, Bombay 400 050.*

*Received for publication: July 4, 1991;*

*Accepted: March 4, 1992*

(normal male prepuberty: 3-17 mIU/ml—Leeco Std 1st IRP-68/40). Ultrasonography of the right testis showed multiple hypoechoic areas. The left testis was normal. Ultrasonography of the abdomen did not reveal the presence of any metastases in the lymph nodes or the liver. X-ray of the chest was normal. With a probable diagnosis of a Leydig cell tumor, a right orchidectomy was performed. Gross examination of the specimen (*Fig. 1*) showed a testis shaped mass measuring  $4.2 \times 3.7 \times 3.2$  cm, which was covered with a tunica albuginea and tunica vaginalis. The cut surface showed a homogeneous brown tumor, replacing the entire testis, with a few grey spots. Microscopic sections stained with hematoxylin and eosin (*Fig. 2*) revealed complete replacement of normal testicular tissue with round and polyhedral tumor cells, arranged in sheets, with small spherical nuclei and abundant eosinophilic cytoplasm. Some cells had plasmacytoid appearance with occasional cells containing brown lipochrome pigment. There was no nuclear atypism or mitotic activity and no evidence of vascular or capsular invasion. Masson trichrome stain did not show the presence of Reinke crystalloids. Epididymis and spermatic cord were free of the tumor. The histopathological diagnosis was Leydig cell tumor.

Serum hormonal profile after the surgery was as follows: serum testosterone: 1.4 ng/ml; serum estradiol: 10 pg/ml, serum FSH: 7.6 mIU/ml, serum LH: 3.4 mIU/ml.

## Discussion

Testicular tumors are rare in general population and occur at the rate of about 2/100,000 per annum(5). These are uncommon in children and account for 1-2% of all pediatric solid tumors(6). Leydig cell tumors are even rare and account for 1-3%

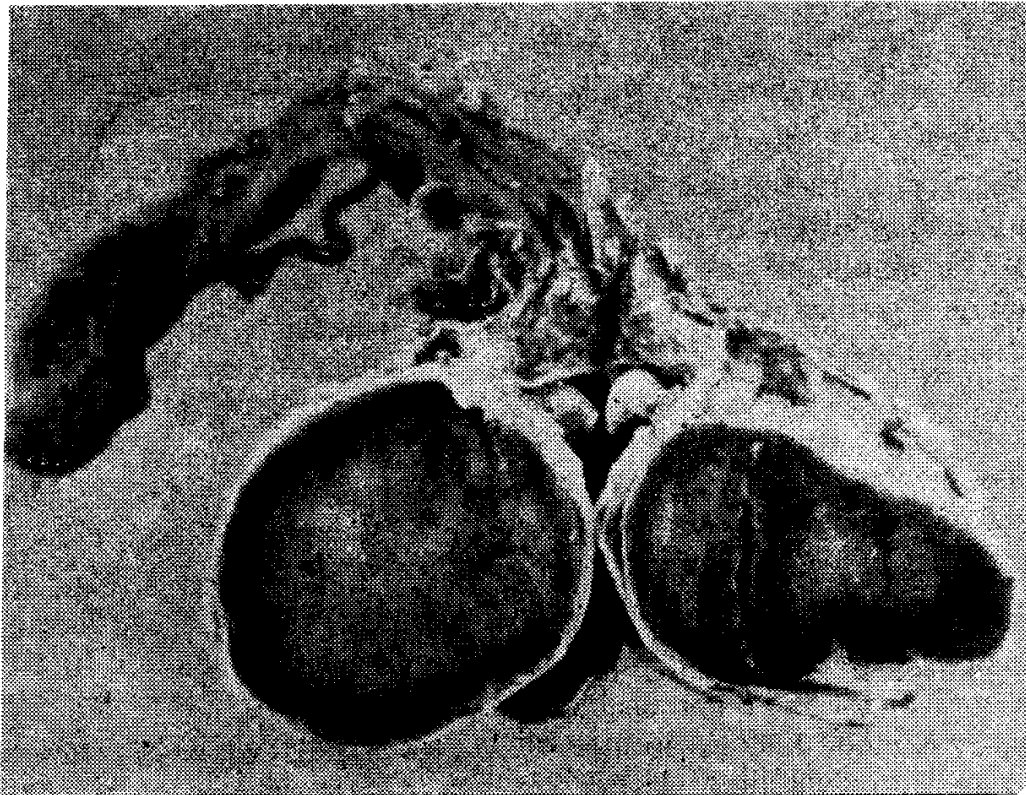
of all testicular tumors(7). About 25% of all Leydig cell tumors occur in children(8). Since the initial report of Sachi in 1895, about 250 cases of Leydig cell tumor were reported till 1986(9).

Leydig cell tumors are mainly seen in three different age groups: (1) prepubertal: 5-9 years, (2) adult: 30-35 years, and (3) older age: about 60 years.

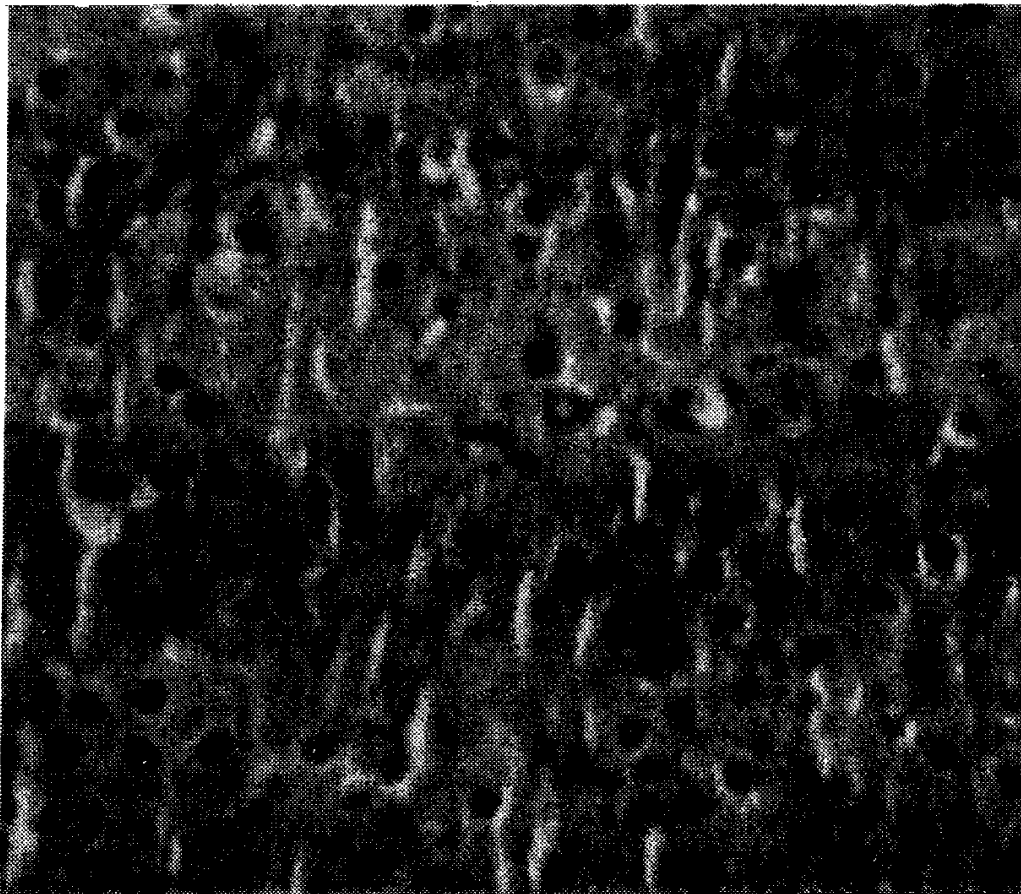
In childhood, isosexual precocious puberty is almost always seen. The manifestations mimic the features of normal puberty but for the unilateral testicular enlargement. FSH and LH are usually at the prepubertal level. Leydig cell tumors must be differentiated from adrenal rest tumors of testis that often develop in boys with poorly controlled congenital adrenal hyperplasia(10,11). Leydig cell tumors can also occur in association with male pseudohermaphroditism, Klinefelter syndrome and testicular feminization(8).

In adult life, Leydig cell tumors are predominantly estrogen secreting and present with gynecomastia, sexual impotence and a tumor mass(5). Feminization may long precede the discovery of the testicular tumor. The feminization may be directly related to estrogen production or indirectly to metabolic conversion of excess androgen produced by the tumor.

The Leydig cell tumor secretes testosterone in children and predominantly estrogen in adults, account for the differences in the clinical manifestations between children and adults. Plasma FSH and LH are usually low or low normal. Only few studies have been made concerning the post operative hormonal values. The hormonal profile may return to normal; alternatively the pediatric patients, in whom there has been a hypothalamic awakening as a result of elevated testosterone level, may slide from pseudopreco-



*Fig. 1. Cut surface of the tumor mass completely replacing the testis.*



*Fig. 2. Tumor consisting of round to polyhedral cells arranged in sheets, with a small spherical nucleus and abundant eosinophilic cytoplasm. (H & E stain 400 X).*

cious puberty into true isosexual precocious puberty with the normal profile of progressive male puberty(2,12).

Most Leydig cell tumors are small and measures less than 2.5 cm in diameter(8). Some may be non-palpable and are detected only on ultrasonography of the testis(12,13). Following injections of HCG, there may be a very marked increase in plasma levels of testosterone and estrogen(8). The histopathologic appearance is as described in this patient.

Ten per cent of the tumors are bilateral(7), 10% are malignant, and malignancy should be suspected in tumors more than 5 cm in diameter. A certain diagnosis of malignancy is made only by documenting metastatic disease, though it may be suspected from histological features. Metastatic disease may occur many years after orchidectomy. Thus, these patients require prolonged clinical follow up.

The prognosis in patients with Leydig cell tumor is good. Treatment consists of orchidectomy, but this may not cause regression of the physical precocity or the child's bone age(14). Malignant tumors are generally refractory to radiotherapy and to conventional chemotherapy(15).

#### Acknowledgement

The authors thank the Dean, KEM Hospital and Seth GS. Medical College, Bombay 400 012, for allowing them to report this article.

#### REFERENCES

1. Urban HD, Lee PA, Plotnick LP, Migeon CJ. The diagnosis of Leydig cell tumors in childhood. *Am J Dis Child* 1978, 132: 494-497.
2. Crisuolo T, Sinisi AA, Perrone L, Graziani M, Bellastella A, Faggiano M.

Isosexual precocious pseudopuberty secondary to a testosterone-secreting Leydig cell testicular tumor. True isosexual development early after surgery. *Andrologia* 1986, 18: 175-183.

3. Indian Council of Medical Research: Growth and Physical Development of Indian Infants and Children, Technical Report Series No. 18, 1972.
4. Greulich WW, Pyle SI. Radiographic Atlas of Skeletal Development of Hand and Wrist, 2nd edn. Stanford California, Stanford University Press, 1959.
5. Mellor SG, McCutchan JDS. Gynecomastia and occult Leydig cell tumor of the testis. *Br J Urol* 1989, 63: 420-422.
6. Ise T, Ohtsuki H, Matsumoto K, *et al.* Management of malignant testicular tumors in children. *Cancer* 1976, 37: 1539-1545.
7. Mostofi FK, Price EB. Tumors of Male Genital System. Atlas of Tumors Pathology, 2nd Series Fasc Armed Forces Institute of Pathology, 1973, pp 86-99.
8. Steg A, Frileux P, Debre B, Desligneres S, Luton JP. Leydig cell tumors in adults. A report of 13 cases. *Prog Clin Biol Res* 1985, 203: 643-655.
9. Jorion JL, DeCooman SE, Darolenne AN, Gosseye S, Wese FX, Van Cangh PJ. Leydig cell tumor of the testis—Four new cases. *Acta Urol Belg* 1986, 54: 450-458.
10. Burke EF, Gilbert E, Mehling DT. Adrenal rest tumors of the testis. *J Urol* 1973, 109: 649-652.
11. Newell ME, Lippe BM, Ehrlich RM. Testis tumors associated with congenital adrenal hyperplasia: a continuing diagnostic and therapeutic dilemma. *J Urol* 1977, 117: 256-258.
12. Corrie D, Norbeck JC, Thompson I *et al.* Ultrasound detection of bilateral

Leydig cell tumors in palpable normal testis. *J Urol* 1978, 137: 747-748.

13. Emory TH, Charboneais JW, Randall RV, Scheithauer BW, Grantham JG. Occult testicular interstitial tumor in a patient with gynecomastia: Ultrasonic detection. *Radiology* 1984, 151: 474.
14. John WD. Surgical aspects of testis tumors in children. *In: Pediatric Surgical Oncology*. Ed Heys DM. Los Angeles, Grune and Stratton Inc (Orlando, USA), 1986, pp 189-204.
15. Glavind K, Sondergaard G. Leydig cell tumor: Diagnosis and treatment. *Scand J Urol Nephrol* 1988, 22: 343-345.

---

## Acute Infectious Thrombocytopenic Purpura and Circulatory Failure—Is It Dengue Shock Syndrome?

S. Lewin  
N. Pandit  
M. Yeshwanth

Dengue hemorrhagic fever/dengue shock syndrome (DHS/DSS) is a severe, often fatal, febrile illness caused by dengue viruses, characterized by capillary permeability, abnormalities of hemostasis, and in severe cases, a protein losing shock syndrome.

---

*From the Department of Pediatrics, St John's Medical College Hospital, Bangalore 560 034.*

*Reprint requests: Dr. Malathi Yeshwanth, Professor of Pediatrics, St John's Medical College Hospital, Bangalore 560 034.*

*Received for publication: July 18, 1991;*

*Accepted: March 25, 1992*

At the National Conference of the Indian Academy of Pediatrics (1991), there was presentation of an upsurge of Dengue from Bombay(1). However, we believe this distinct shock syndrome, highly suggestive of DSS, is the first reported from South India probably heralding a new cause for morbidity and mortality in children.

### Case Reports

Four healthy girls residing in Bangalore District, Karnataka presented with evidence of an acute febrile illness, purpura and shock. None had travelled out of the State and were all admitted as septicemic shock.

The pertinent details of the cases are tabulated in *Table I & II*. All children recovered with fresh blood, intravenous fluids, dopamine and steroids. Antibiotics were discontinued following prompt response and negative cultures. Antibody titres failed in all these cases due to improper storage, but as we send this report a similar child with a DHF picture has been reported positive (Virus specific IgM antibody by Elisa).

### Discussion

Dengue hemorrhagic syndrome (DHS) and dengue shock syndrome (DSS) is a leading infectious cause for morbidity in the tropics(2,3). In the past two decades, epidemics have occurred throughout SE Asia and W. Pacific including India(3-5). Epidemic rates are as high as 50% with 5% presenting in shock with hemorrhage. Death has occurred in 1% of these cases(20).

In endemic areas, Dengue is primarily a disease of childhood with nearly 100% occurring before 8 years of age(2). A large number of DHS/DSS occurred in children with a mean age of 3 years. DSS has an age