

Herpetic Whitlow

A seven-year-old, non-atopic girl presented with a painful eruption over right thumb of two days duration. She had fever, vesicular eruptions over lips and oral cavity, three days prior to the onset. She had a habit of thumb-sucking. Cutaneous examination showed multiple grouped vesicles over dorsa of right thumb and primary herpetic gingivostomatitis (**Fig. 1**). Tender submental and right epitrochlear lymphadenopathy was present. Other cutaneous and systemic examination was normal. A diagnosis of herpetic whitlow was confirmed by tzanck smear. Patient was started on tablet acyclovir (30mg/kg/day) for seven days with complete resolution.

Herpetic whitlow refers to herpes simplex virus infection of digits. In children, it commonly occurs from primary herpetic gingivostomatitis due to auto-inoculation from finger/thumb sucking or nail biting. Fingers (thumb), palms and wrists are involved in decreasing order of frequency. Fever, constitutional symptoms, painful erythematous swelling with vesicles/pustules appears over infected site. Painful regional lymphadenopathy/lymphangitis may be present. Spontaneous resolution may occur in 18-20 days. Differential diagnosis for primary herpetic gingivostomatitis includes streptococcal infections,

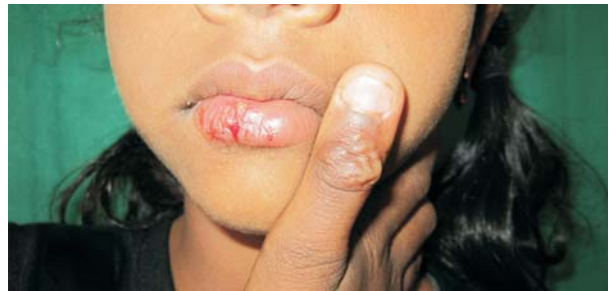

FIG 1. Grouped vesicles/erosions over lower lip and right thumb.

aphthous stomatitis, herpangina, diphtheria, erythema multiforme and Stevens-Johnson syndrome. Herpetic whitlow needs to be differentiated from bacterial paronychia, felon, blistering distal dactylitis, bullous impetigo and other staphylococcal pyodermas. Complications include local hypoesthesia, and secondary ocular and genital disease. Systemic acyclovir may be used and counseling must be done to avoid thumb-sucking for preventing recurrences

**SAMBASIVIAH CHIDAMBARA MURTHY AND
SHRICHARITH SHETTY**

*Department of Dermatology and Venereology,
Government Medical College and Hospitals(VIMS),
Bellary- 583104, India.
chidumurthy@rediffmail.com*

Piebaldism

A seven year old male child was brought to us for fever and was diagnosed to have *Plasmodium vivax* malaria with anemia and thrombocytopenia. On general examination, he had a white forelock and depigmented patches over the knees and a unique heart shaped depigmented patch over the abdomen. (**Fig.1**) There were islands of normal skin in the depigmented areas. Family history revealed that the paternal grandfather and three aunts of the patient had similar features suggesting piebaldism.

Piebaldism is inherited as an autosomal dominant condition and is also known as partial albinism. The distribution of the depigmented patches seen in our patient

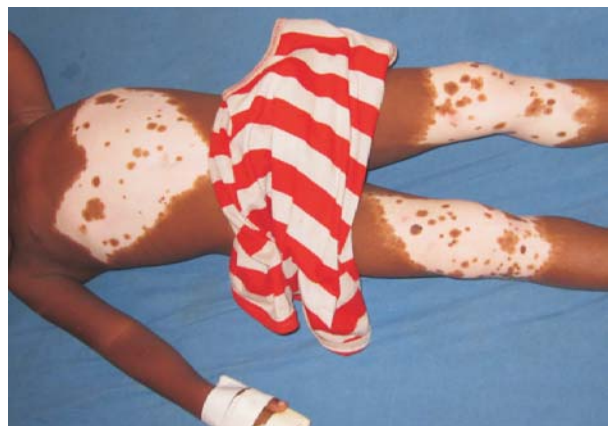

FIG.1 White forelock and depigmented patches over the knees and the heart shaped depigmented patch over the abdomen.


is classically described in literature. These plaques of depigmentation are a result of a permanent localized absence of melanocytes and melanosomes or reduced numbers of abnormally large melanocytes. It results from mutations in the KIT proto-oncogene, which encodes the cellular transmembrane tyrosinase kinase for mast/stem cell growth factor. This pattern of depigmentation is probably due to defective melanocyte proliferation or migration from the neural crest during development. It should be differentiated from vitiligo which is progressive and Waardenberg syndrome which has heterochromic iris, dystopia canthorum, broad nasal root and congenital

deafness, in addition to white forelock and hypopigmentation. There are occasional reports of piebaldism associated with type 1 Neurofibromatosis and Rubinstein Taybi syndrome.

**VAISHALI MORE, RATNA SHARMA AND
VINNY THOMAS,**

*Department of Pediatrics
Dr DY Patil Medical College,
Hospital and Research Center,
Nerul, Navi-Mumbai, Maharashtra, India.
morevaishali28@gmail.com*


BOOK REVIEWS



Social Pediatrics
SATYA GUPTA, AP DUBEY
*Paras Medical Publishers;
Hyderabad, New Delhi
1st Edition, 2011
Pages: 387; Price: 250/-.*

Pediatricians, as an academic and professional community, have always been responsive to their wider roles and it is not merely a coincidence that they stay as some of the most visible and suitably informed actors in the practice and politics of Public Health. In this historical context, one feels a bit surprised that the domain of Social Pediatrics did not enjoy a fitting growth rate in spite of the exceptional legacy of leaders like Shanti Ghosh. This handy and readable book comes as a booster while offering some consolidated and handy text to the practitioners of pediatrics from varied settings. Uncomplicated mind maps in most of its 33 chapters make the browsing very simple. It is equally creditable that necessary theoretical and conceptual inputs have not been sacrificed while maintaining a practical tenor. The flipside is non-uniformity of form and structure amongst chapters, and a few unclear photographs. Academic movements in Social Pediatrics have had a paroxysmal character. A single book is a single vote which may not make or break the establishments but one can hope that this attempt reignites a chain reaction for some positive change.

SANJAY CHATURVEDI
*Professor of Community Medicine,
University College of Medical Sciences,
Delhi-110 095, India.
cvsanjay@hotmail.com*



**The 10 Minute Clinical
Assessment - A Review**
KNUT SCHROEDER
*UK: Wiley-Blackwell;
Pages: 772;
Price: Not mentioned.*

This 'Desk Top' reference Book consisting of 154 selected clinical situations is a treasure to be possessed by every practitioner facilitating in making quick clinical assessment of the patient's illness based on the complaints and arrive at a correct diagnosis for efficient management.

Though modern gadgets and sophisticated investigative procedures are becoming abundant day by day, the importance of clinical assessment cannot be underplayed. One of my professors during my undergraduate training five decades ago, rightly said that "diagnosis of respiratory system is by INSPECTION; diagnosis of gastrointestinal and hepatic system diseases is by PALPATION; diagnosis of cardiovascular diseases is by AUSCULTATION and diagnosis of central nervous neurological disorders is by MATHEMATICAL CALCULATION". This book enlightens this maxim in its well written and well presented 18 chapters. This book guides the reader to assess the patient's complaints and symptoms and signs in 10 minutes and arrive at a correct diagnosis for accurate management, and refer if needed. This book guides the reader. I strongly recommend this book for a practicing doctor's office.

A PARTHASARATHY
*Distinguished Professor of Pediatrics,
The Tamil Nadu Dr MGR Medical University, Guindy,
Chennai, Tamil Nadu, India. apartha2020@gmail.com*