

## ***Klebsiella pneumoniae* Brain Abscess in Two Neonates**

PRAGYA PANT  
SHYAMAL BANERJEE  
SUTAPA GANGULY

### ABSTRACT

*We report two premature infants who developed multiple brain abscesses following Klebsiella pneumoniae infection. Both the cases were diagnosed by ultrasonogram (USG) and cranial tomography. Abscess had intraventricular communication in one case. One infant was managed conservatively while the other required surgical drainage.*

**Key words:** Brain abscess, *Klebsiella pneumoniae*, Neonates.

### INTRODUCTION

Brain abscess is an infrequent complication of meningitis, including cases caused by Gram-negative enteric bacteria in neonates(1). *K. pneumoniae*, although a common cause of neonatal septicemia, is rarely implicated as an etiological agent for cerebral abscess in this age group(2). The interest of these cases lies in the rarity of the causative organism.

### CASE REPORT

**Case 1:** A preterm, 32 weeks, appropriate for gestational age (AGA) baby with birthweight 1700 g

*From the Neonatology Unit, Department of Pediatrics, N.R.S. Medical College and Hospital, 138, AJC Bose Road, Kolkata 700 014,, India.*

*Correspondence to: Dr. Pragya Pant, C/o Dr. Jayanta Kumar Ghosh, RMO Quarter, I Floor, Medical College, 88, College Street, Kolkata 700 073, West Bengal, India. E-mail: drpragyapant@yahoo.co.uk*

*Manuscript received: June 11, 2007;  
Initial review completed: July 23, 2007;  
Revision accepted: February 1, 2008.*

was delivered vaginally to a primi gravida. Mother had history of high-grade fever for 24 hours before delivery and the treating obstetrician diagnosed urinary tract infection. Apgar scores at 1 and 5 minutes were 8 and 9 respectively. The baby was asymptomatic and feeding well till day 6 of life after which he developed lethargy and failure to suck. Sepsis screen showed raised C-reactive protein (CRP) level (10mg/dL). CSF examination was suggestive of meningitis. Blood culture (BACTEC) after 72 hours showed growth of *K. pneumoniae* sensitive to amikacin, ofloxacin and meropenem. Child was treated with meropenem and amikacin. CSF culture also showed the same organism and sensitivity pattern. Baby showed partial improvement, he started taking feeds but lethargy persisted. On 12<sup>th</sup> day of life, bulging anterior fontanel was noted. USG cranium revealed multiple space occupying lesions in bilateral frontal and parietal lobes with echogenic fluid. Cranial tomography revealed multiple bilateral brain abscesses with intraventricular communication. Aspiration of the abscess done through anterior fontanel revealed frank pus which was sterile on culture. Parents were not ready for surgical drainage. Baby received antibiotics for total of 21 days, during which he was persistently lethargic and head circumference was increasing. On 22<sup>nd</sup> day of admission, parents declined treatment and took the baby against medical advice.

**Case 2:** A preterm, 35 weeks, AGA baby with birthweight of 2000 g was delivered vaginally to a second gravida mother. Apgar scores at 1 and 5 minutes were 8 and 9 respectively. Mother had history of PROM for 3 days. Baby was lethargic and mildly tachypneic. However, there were no features suggestive of intracranial infection. Sepsis screen revealed leukopenia (total leukocyte count, 4200/mm<sup>3</sup>; absolute neutrophil count, 1450/mm<sup>3</sup>) and raised CRP (18.4 mg/dL). CSF and X-ray chest were normal. IV ampicillin and amikacin were started. Blood culture (BACTEC) at 72 hours revealed *Klebsiella pneumoniae* sensitive to amikacin, chloramphenicol, coamoxyclav, ofloxacin and meropenem. Antibiotics

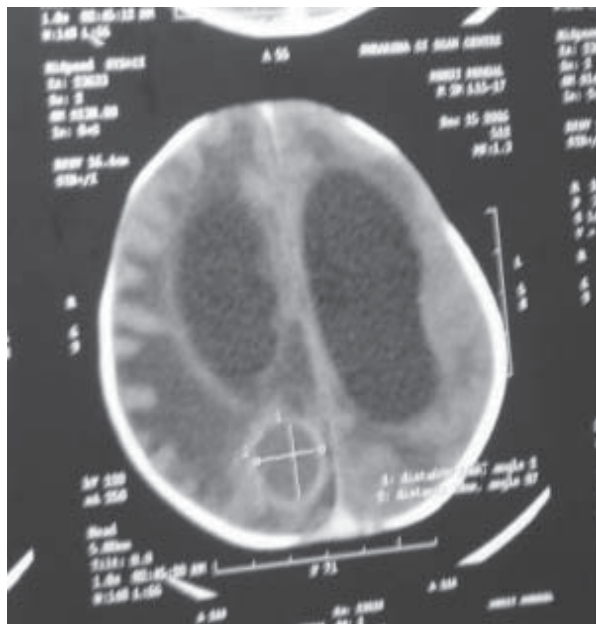
## CASE REPORTS

were changed to meropenem and amikacin. The baby showed gradual improvement and was discharged at 14 days of life. Mother noticed increasing head size after discharge but ignored it. On day 25 of life, baby presented with fever, convulsions and vomiting for 6 days. Baby had received multiple antibiotics from elsewhere in the last 6 days. Cranial tomography showed an abscess in the occipital region (**Fig. 1**). The abscess was not communicating with any ventricle; ventriculomegaly was present possibly due to associated ventriculitis. Neurosurgical drainage was done immediately and IV antibiotics were started. Gram stain of the pus and pus culture were negative possibly due to prior antibiotic treatment. Baby showed gradual improvement and discharged after 21 days of IV antibiotics.

## DISCUSSION

We have presented two cases of brain abscess in neonates after sepsis caused by *K. pneumoniae*. Despite *Klebsiella* being one of the most common organisms causing neonatal sepsis in India(3), only one case of brain abscess due to the organism has been reported earlier(2). Another case was reported in 1987 by Theophilo, *et al.*(4). In one of the largest series of 30 neonates with brain abscess in a tertiary center, no case was attributed to *Klebsiella*(5). By the presence of *K. pneumoniae* in the blood and C.S.F of case 1 and blood of case 2, it was concluded that the abscess is most likely due to the same organism. Pus culture could be negative due to prior antibiotic therapy. Most of the cases of brain abscess in the neonates are caused by *Proteus* and *Citrobacter spp.*, possibly due to more necrotizing lesions caused by the latter organisms(1).

The source of infection in both the cases was likely from mother, in the first case, mother had UTI and in the other case history of prolonged rupture of membrane was present. In neonates, brain abscess appears to be a complication of meningitis in the majority of cases(6). Complications are severe in preterm neonates with brain abscess. Treatment of brain abscess includes prolonged antibiotic therapy and neurosurgical drainage. Multiple aspirations are necessary for cases that do not respond to single aspiration(6).



**FIG. 1.** CT Cranium showing brain abscess in right occipital region and ventriculomegaly.

**Funding:** None.

**Competing Interest:** None stated.

## REFERENCES

1. Graham DR, Band JD. *Citrobacter diversus* brain abscess and meningitis in neonates. *JAMA* 1981; 245:1923-1925.
2. Basu S, Mukherjee KK, Poddar B, Goraya JS, Chawla K, Parmar VR. An unusual case of neonatal brain abscess following *Klebsiella pneumoniae* septicemia. *Infection* 2001; 29: 283-285.
3. Singh M. Perinatal Infections. In: Singh M, editor. *Care of the Newborn*. 6th ed. New Delhi: Sagar Publications; 2004. p.196-218.
4. Theophilo F, Burnett A, Filho JG, Miranda S, Theophilo L, Carvalho M, *et al.* Ultrasound-guided brain abscess aspiration in neonates. *Childs Nerv Syst* 1987; 3: 371-374.
5. Renier D, Flandin C, Hirsch E, Hirsch JF. Brain abscesses in neonates. A study of 30 cases. *J Neurosurg* 1988; 69: 877-882.
6. Francis BM, Gilbert GM. Survey of neonatal meningitis in Australia 1978-89. *Med J Aust* 1992; 17: 240-243.