

**Discussion**

Congenital granular cell myoblastoma is one of the very rare tumor seen in pediatric age group. The female preponderance and failure to grow postnatally suggests the hypothesis of some intrauterine stimulus, Estrogen derived from fetal ovaries under the stimulus of chorionic gonadotropins may be this intrauterine stimulus. Various theories of the histogenesis of these neoplasms have been suggested ranging from lontogenic, fibroblastic, histiocytic, myogenic and neurogenic as reviewed by Blair and Edwards(4). The electron microscopic and immunocytochemical studies have indicated it to be of Schwann cell origin.

The present case was seen in an eight hour old neonate and was treated by complete surgical excision without recurrence after one year of excision which is in agreement with earlier experienced). The case

presented characteristic histology of a benign granular cell myoblastoma.

**REFERENCES**

1. de La Monte SM, Radowsky M, Hood AF. Congenital granular cell neoplasm. An unusual case report with ultrastructural findings and a review of literature. *Am J Dermatopathol* 1986, 8: 57-63.
2. Lack EE, Worsham GF, Callihan MD, Grawford LP Vawter GF. Gingival granular cell tumors of the new born (congenital "epulis"). A clinical and pathologic study of 21 patients. *Am J Surg Pathol* 1981, 5: 37-46.
3. Sharma KK, Goyal RB, Sharma CS, Sinha DD, Shekhawat NS. Congenital granular cell myoblastoma. *Indian J Cancer* 1992, 29: 24-26.
4. Blair AE, Edwards DM. Congenital epulis of the newborn. *Oral Surg* 1977, 43: 687-691.

**Spontaneous Gastric Perforation in a Neonate**

**Geeta Gathwala**  
**K.N. Rattan**  
**Pankaj Abrol**  
**Dinesh Sodhi**

Spontaneous gastric perforation of the

*From the Department of Pediatric Medicine and Pediatric Surgery, Medical College and Hospital, Rohtak 124 001.*

*Reprint requests: Dr. Geeta Gathwala, 11J/11, Medical Enclave, Rohtak 124 001.*

*Received for publication: April 22, 1994;*

*Accepted: May 9, 1994*

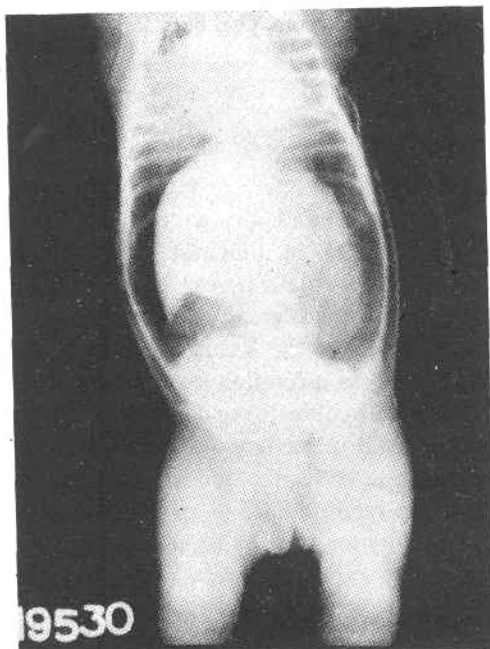
newborn is a rare entity with just over 200 cases reported in literature(1). Although the condition entails a very high mortality, its pathogenesis is greatly debated. Congenital absence of the gastric wall musculature(2), stress ulceration secondary to neurogenic difficulties(3) and ischemia of the gastric wall secondary to vascular shunting(4) have been proposed as etiologic factors. We report a case of spontaneous gastric perforation seen by us in a one-day-old baby.

**Case Report**

A one-day-old male presented with fast respiration and abdominal distension since birth. There was no history of vomiting and the baby had passed meconium. The baby

had not accepted feeds since birth. He was a full term normal vaginal delivery at home conducted by an Auxiliary Nurse Midwife. There was history of birth asphyxia with the baby having cried 15 minutes after birth. On examination, the baby was full term appropriate for gestational age and weighed 3.2 kg. The general condition was not satisfactory and the cry, activity and neonatal reflexes were depressed. He was markedly dyspneic with a respiratory rate of 120/min. The heart rate was 148/min. The abdomen was markedly distended with absent bowel sounds and the liver dullness was masked. Rest of the examination was within normal limits.

On investigation, hemoglobin was 18



*Fig. 1. X-ray abdomen-erect film showing free air under the diaphragm. The abdominal viscera are displaced medially producing the "Saddlebag" appearance.*

g/dl and TLC 16,000 cu/mm ( $P_{75}$   $L_{20}$   $M_3$   $E_2$ ). X-ray abdomen erect film showed free gas under the diaphragm. The viscera were displaced medially, producing the typical 'saddlebag' appearance (Fig. 1). The X-ray chest, blood urea and serum electrolytes were within normal limits.

A diagnosis of gastric perforation was made and an urgent laparotomy undertaken. This revealed a linear perforation 1 cm long with ragged edges, on the anterior wall, near the gastroesophageal junction. The surrounding stomach wall was ischemic. A wide excision of the ischemic edges was done and the perforation was closed in two layers with silk. Postoperatively intravenous fluids were administered and nasogastric aspiration done every 2 hours. Intra-gastric feeds were started on 5th postoperative day. The baby made uneventful recovery and was discharged on the 14th postoperative day.

#### Discussion

Spontaneous gastric perforation as reported earlier is more common in the pre-term baby with perforations most commonly occurring between the 2nd and 7th days of age(5,6). The highest reported incidence of rupture is on the 3rd day of life(6). Our baby was a full term baby and the perforation had occurred on the first day of life. Sudden abdominal distension and respiratory distress have been the reported predominant symptoms(1,5). The incidence of prenatal and perinatal risk factors is reportedly high(5,7). Those commonly observed include prematurity, respiratory distress at birth, asphyxia and resuscitation, premature rupture of membranes and breech, Cesarean or twin delivery, in decreasing order of frequency. Severe birth asphyxia was the high risk factor seen in the present case.

Most commonly the perforations have been linear tears, seen on the greater curvature, usually high and measured between 0.5-8 cm(1,5). In the present case, the perforation was also a linear tear and measured 1 cm. It was located on the upper anterior wall, close to the gastroesophageal junction.

Prompt surgical intervention with repair of the gastric tear is the recommended management. Any delay in surgery will result in a higher mortality(8,9).

The pathogenesis of spontaneous gastric perforation is much debated(2-4,10-12). Gastric tissue ischemia secondary to hypoxia is one plausible explanation(4, 11). During severe hypoxic stress there is selective shunting of blood away from the splanchnic vascular bed leading to vascular damage and perforation. This was the probable sequence of events that operated in our patient.

#### REFERENCES

1. Houck WS, Griffin JA. Spontaneous linear tears of the stomach in the newborn infant. *Ann Surg* 1981, 193: 763-767.
2. Herbut PA. Congenital defect in the musculature of the stomach with rupture in a newborn infant. *Arch Pathol* 1943, 36: 91-94.
3. Kiesewetter WB. Spontaneous rupture of the stomach in the newborn. *Am J Dis Child* 1956, 91: 162-167.
4. Touloukian RJ. Gastric ischemia: The primary factor in neonatal perforation. *Clin Pediatr* 1973, 12: 219-225.
5. Holgersen LO. The etiology of spontaneous gastric perforation of the newborn: A re-evaluation. *J Pediatr Surg* 1981, 16: 608-613.
6. Hood JH. Clinical considerations of intestinal gas. *Ann Surg* 1966, 163: 359-366.
7. Prabhakar G, Agarwal LD, Shukla A, *et al.* Spontaneous gastrointestinal perforation in the neonate. *Indian Pediatr* 1991, 28: 1277-1280.
8. Saracli J, Mann M, Frennd DM, *et al.* Rupture of the stomach in the newborn infant: Report of three cases and review of the world literature. *Clin Pediatr* 1967, 6: 583-588.
9. Inouye WY, Evans G. Neonatal gastric perforation. *Arch Surg* 1964, 88: 471-485.
10. Kneiszi F. Some data on the etiology of gastric rupture in the newborn. *Biol Neonate* 1962, 4: 201-222.
11. Lloyd JR. The etiology of gastrointestinal perforations in the newborn. *J Pediatr Surg* 1969, 4: 77-84.
12. Nagaraj HS, Sandhu AS, Cook LN, Buchino JJ, Groff DB. Gastrointestinal perforation following indomethacin therapy in very low birth weight infants. *J Pediatr Surg* 1981, 16: 1003-1007.