

## Spontaneous Rupture of Malarial Spleen

JAYDEEP CHOUDHURY  
KHEYA GHOSH UTTAM  
MAYA MUKHOPADHYAY

### ABSTRACT

*Spontaneous rupture of malarial spleen is uncommon even in highly endemic areas of malaria. We report an eight year old girl who presented with spontaneous splenic rupture following malaria. She recovered with conservative management.*

**Key words:** Malaria, Rupture spleen.

### INTRODUCTION

Splenic rupture is a rare complication of malaria(1,2). We report a girl with spontaneous rupture of spleen following malaria.

### CASE REPORT

An 8-year-old girl presented with diffuse dull aching pain in the left subcostal region and around umbilicus with low grade fever for 2 days. Pain was acute in onset not accompanied by vomiting, diarrhea, dysuria or trauma. There was no history of fever or jaundice. Twenty days prior to this episode she had suffered from *P. vivax* and *P. falciparum* malaria for which she was successfully treated with oral chloroquine. During the intervening period the child was asymptomatic and maintaining sedentary lifestyle.

On examination she was having mild pallor, tachypnea and tachycardia with normal blood pressure. Abdomen was neither distended nor tense; bowel sounds were sluggish. The spleen was just palpable with marked tenderness on pressing the left

subcostal region. The lymphnodes were not enlarged and the liver was not palpable. She was put on conservative management with intravenous fluid and hemodynamic monitoring. Thick and thin peripheral blood smear did not show any malaria parasites. There were no abnormal cells in peripheral blood smear. Antigen test for both *P. vivax* and *P. falciparum* species were negative. Liver function test was also normal. Ultrasonography of abdomen showed mild splenomegaly with a hypoechoic area in splenic parenchyma, decreased gut movement and minimal ascites. There was tenderness in the left subcostal region when the ultrasound probe was pressed. CT scan of abdomen was done the next day which revealed enlarged spleen with smooth outline and density. A large wedge shaped non-enhancing hypodense lesion was seen in the upper part of the spleen extending up to the splenic capsule suggesting infarct (**Fig. 1**) with rupture (**Fig. 2**). There was no calcification.

The child was put on conservative management with bed rest and intravenous fluid. She did not require any analgesic as the pain was not very severe. Daily abdominal ultrasonography was done. Oral feed could be started after 3 days. She did not complain of abdominal pain after eight days. Prior to discharge two weeks later, CT scan of abdomen did not show any hypodense lesion or rupture.

### DISCUSSION

The exact mechanism of spleen rupture in malaria is not known. The following three mechanisms are implicated: (i) increase in intrasplenic tension due to cellular hyperplasia and engorgement; (ii) spleen may be compressed by the abdominal musculature during physiological activities such as sneezing, coughing, defecation, etc.; and (iii) vascular occlusion due to reticulo-endothelial hyperplasia, resulting in thrombosis and infarction(1). This leads to interstitial and subcapsular haemorrhage and stripping of the capsule, which lead to further subcapsular haemorrhage. The distended capsule finally gives way.

According to a WHO report, splenic infarction is considered rare in *P. falciparum* malaria(3). There are a few Indian reports of infarction and spontaneous rupture of malarial spleen, following *P.*

*From the Institute of Child Health, 11 Dr Biresw Guha Street, Kolkata 700 017, West Bengal, India.*

*Correspondence to: Dr Jaydeep Choudhury, 95/2 Ballygunge Place, Kolkata 700 019, India.*

*E-mail: drjaydeep\_choudhury@yahoo.co.in*

*Manuscript received: March 22, 2007;*

*Initial review completed: April 12, 2007;*

*Revision accepted: November 19, 2007.*

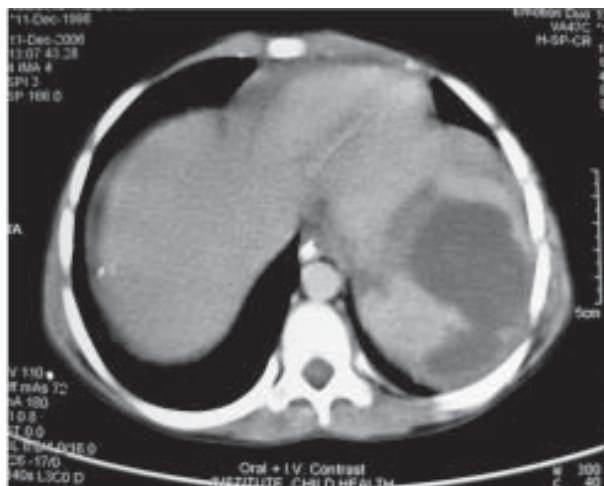


FIG. 1. CT scan of abdomen showing splenic infarct.

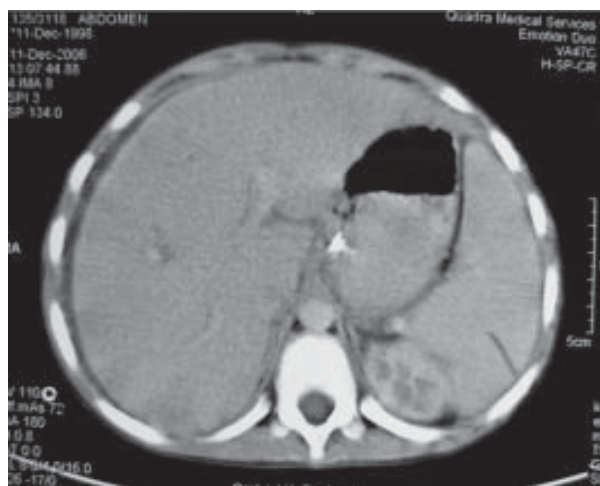


FIG. 2. CT scan of abdomen showing splenic rupture.

*falciparum* infection(4-6); however, among the splenic rupture cases reported in malaria by Zingman(7), 9 out of 15 were due to *P. vivax*. Spontaneous rupture of a malarial spleen can occur in up to an estimated 2% of cases(8).

This rare complication can occur despite appropriate antimalarial prophylaxis and treatment(9). There are no definite predictive signs. Left hypochondrial pain occurring during or following treatment of malaria is usually the most common presentation of splenic infarction or rupture in malaria(4-6,8,9).

Splenectomy has been suggested as the treatment of choice for pathologic rupture of spleen(2). But, due to the important role of spleen in the immune response to pneumococcal and malarial infections, successful conservative management has been reported(9). Non-operative management consists of observation for 7-14 days in the hospital, strict bed rest, and administration of fluid and blood as needed. Regular abdominal ultrasonography should be done to assess healing. Splenectomy should be reserved for patients with severe rupture or those with continued or recurrent bleeding(10).

*Contributors:* JC and KG were involved in patient management. JC reviewed the literature and drafted the manuscript. MM supervised the management and guided in preparation of the manuscript. JC shall act as guarantor.

*Funding:* None.

*Competing interests:* None stated.

## REFERENCES

1. Patel MI. Spontaneous rupture of a malarial spleen. *Med J Aust* 1993; 159: 836-837.
2. Krause PJ. Malaria (*Plasmodium*). In: Behrman RE, Kliegman RM, Jenson HB, editors. *Nelson Textbook of Pediatrics*. 17th edn. Philadelphia: WB Saunders Co; 2004. p. 1139-1143.
3. WHO Guidelines for the Treatment of Malaria. Geneva: WHO Regional Publications; 2006.
4. Agarwal VK, Agarwal S, Pathak T. Splenic infarct in falciparum malaria. *Indian Pediatr* 1997; 34: 1050-1051.
5. Sur AK, Khawash N, Mitra P, Ghosh K, Sinharoy D. Splenic infarct in falciparum malaria. *Indian Pediatr* 1997; 34: 34.
6. Vidyashankar C, Basu A, Kulkarni AR, Choudhury RK. Spontaneous rupture of spleen in falciparum malaria. *Indian J Gastroenterol* 2003; 22:101-102.
7. Zingman BS, Viner BL. Splenic complications in malaria: case report and review. *Clin Infect Dis* 1993; 16: 223-232.
8. Ozsoy MF, Oncul O, Pekkaşali Z, Pahsa A, Yenen OS. Splenic complications in malaria: report of two cases from Turkey. *J Med Microbiol* 2004; 53:1255-1258.
9. Bonnard P, Guird-Schimid JB, Develoux M, Rozenbaum W, Pialoux G. Splenic infarction during acute malaria. *Trans R Soc Trop Med Hyg* 2005; 99: 82-86.
10. Mokashi AJ, Shirahatti RG, Prabhu SK, Vagholkar KR. Pathological rupture of malarial spleen. *J Postgrad Med* 1992; 38: 141-142.