

Synchronous Germinomas in the Pineal and Suprasellar Region

Faisal Haque
 Mohd Zahid
 S. Ameer Ahmad
 Shano Naseem*

Synchronous primary intracranial germ cell tumors are rare. Only 5-10% of all germ cell tumors are found as synchronous lesion in pineal and suprasellar region. They are also known by the entity "double mid-line atypical teratoma". An 11-year-old male child presented with polyuria, polydipsia and features of raised intracranial tension. CT scan head revealed well-defined homogenously enhancing lesions in the pineal and suprasellar region. Histopathology examination showed the lesion to be of germ cell origin.

Keywords: *Germinoma, Pineal gland.*

Germinomas are the commonest primary intracranial germ cell tumors and account for over 50% of all neoplasms in the region of pineal gland. The preferential locations of intracranial germinomas are the pineal and suprasellar regions.

Germ cell tumors with synchronous lesions in the pineal and suprasellar regions (GCTSPS) account for nearly 10% of all intracranial germ-cell tumors(1,2). There is a

From the Departments of Radiodiagnosis & Pathology, Jawahar Lal Nehru Medical College, Aligarh Muslim Univerity, Aligarh 202 002, U.P., India.*

Correspondence to: Dr. Faisal Haque 41-Alig Apartment, Shamshad Market, Aligarh 202 002, U.P., India.

E-mail: faisalhaquel@rediffmail.com

Manuscript received: February 9, 2004;

Initial review completed: April 22, 2004;

Revision accepted: November 29, 2004.

male predominance with majority of the patients presenting in the second decade of life. We are presenting a rare case of synchronous germinoma in the pineal and suprasellar region in an 11-year-old male child.

Case Report

A 11-year-old boy presented with polyuria and polydipsia of three months duration, and headache, nausea, vomiting, blurred vision and unsteady gait of one month duration. Neurological examination revealed papilledema and bilateral scotoma. There was restriction of upward gaze and convergent nystagmus on attempted upgaze (Parinaud's syndrome). The patient had normal mental development and secondary sexual characters.

The routine hematological examination revealed no abnormality. The CSF examination did not show any abnormal cells. The serum alpha-protein level was raised (1.1 ng/mL). β -hCG level was also significantly elevated to 988 MIU/mL.

CECT head (*Fig. 1*) showed well defined rounded homogenously enhancing lesion, in the pineal and suprasellar region measuring 1.3×1.0 cm and 1.0×1.1 cm respectively, without any evidence of calcification or necrosis. The suprasellar lesion was causing mass effect on the floor of 3rd ventricle. Bilateral temporal horns were mildly prominent. Craniotomy was performed and tumor was resected through subfrontal approach, which on histopathology revealed germinoma and subsequently the patient was put on radiotherapy.

Histopathologic examination of multiple, irregular, grayish brown soft tissue bits revealed the tumor to be composed of two types of cells—polyhedral cells with vacuolated cytoplasm and cells identical to small mature T-lymphocytes. They were

CASE REPORTS

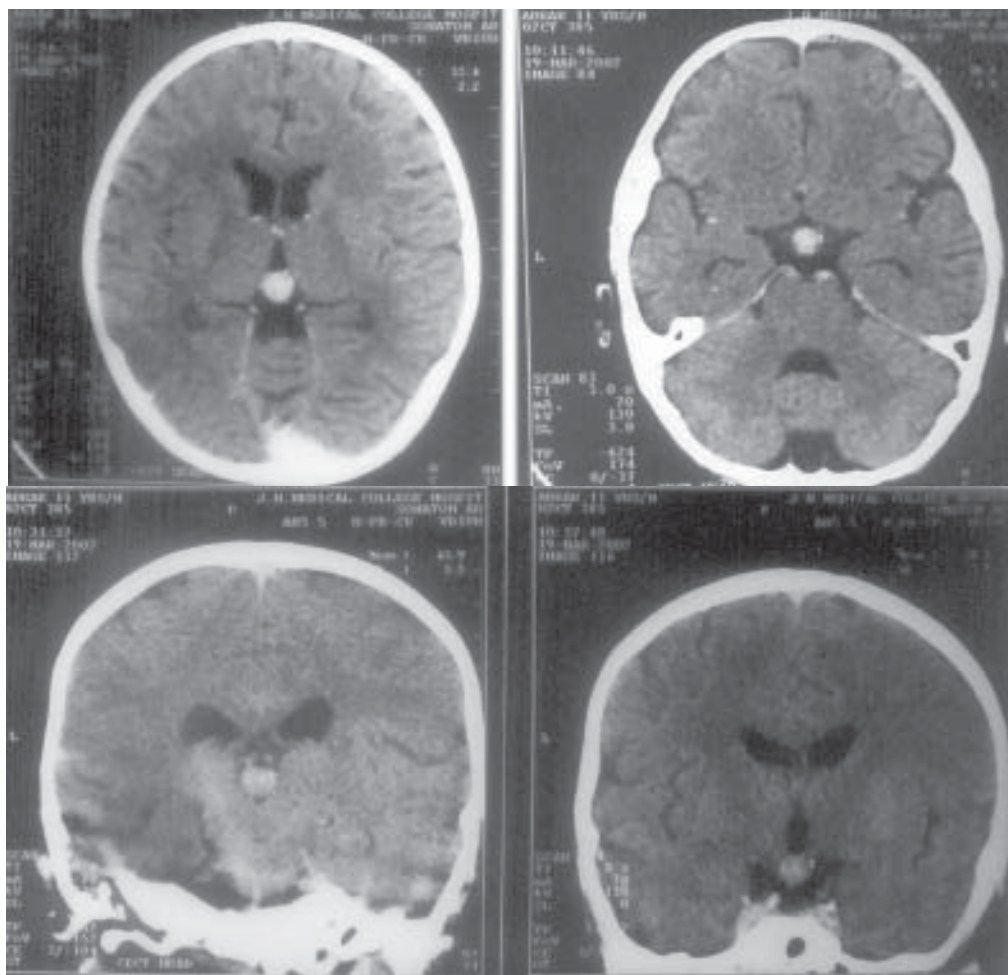


Fig.1(a,b). Axial and coronal post contrast CT scans demonstrating well defined markedly enhancing suprasellar and pineal masses, with mass effect on third ventricle.

arranged in lobules traversed by delicate vascularized trabeculae.

Discussion

The term “germinoma” was originally introduced by Friedman(3). Majority of the patients presents in the second decade of life, with a preponderance of males over females(1). The symptoms depend on the location of the tumor within the brain. In the suprasellar germinoma, endocrinological

manifestations prevail (most commonly diabetes insipidus, delayed gonadal functions and precocious puberty may be the other complaints). Symptoms in germinomas located in the pineal region are due to increased intracranial pressure(4). When the tumor involves both sellar and the pineal region, the presenting symptoms are typically due to sellar lesion rather than the pineal mass. The present case an 11 years old boy also initially presented with features due to sellar

mass particularly diabetes insipidus and subsequently developed features due to raised ICT. Involvement of the oculomotor apparatus produces loss of upward conjugates deviation of the eyes (Parinaud's syndrome) and abnormal pupillary reflexes(5). Our patient had most of the common clinical features described by Sung, *et al.* Intracranial germinomas may also be associated with Down's syndrome(6).

The introduction of CT scanning was truly an epoch, though MRI is the ideal investigation today. On plain CT, the tumor shows well defined, rounded and homogenous is to slightly higher density mass. Calcification and necrosis are rare. After intravenous contrast administration, the tumor shows homogenous enhancement irregular margins suggest local infiltration. MR scans typically demonstrate an infiltrating mass that is isointense to brain on T1WI, moderately hyperintense on T2WI and enhances strongly and homogeneously after contrast administration(7). GCTSPS has been considered highly sensitive to irradiation and can be cured with it alone without histological diagnosis. However, some subtypes are not radiation sensitive and neuroimaging characteristics of germinoma and non germinomatous tumors are similar enough to limit diagnostic certainty and proceeding for further treatment on its basis alone. So, histopathological confirmation becomes significant atleast from single site. Keeping this in view, we also got the histopathology done from only the suprasellar region. The histologic picture is highly distinctive. About 70% to 80% of tumor-infiltrating lymphocytes in intracranial germinomas are T-lymphocytes and 20 to 30% are B-lymphocytes.

In pineal region germ cell tumors cannot be separated on the basis of neuro-imaging characteristics from other tumors such as

pineblastoma, pineocytomas or gliomas. However, pattern of calcification may be helpful in differentiating them(8). Differential diagnosis of a suprasellar region germinoma includes opticochiasmatic - hypothalamic glioma and cranio-pharyngiomas. Langerhans cell histiocytosis may clinically and radiographically mimic it but isolated disease of the central nervous system in Langerhans cell histiocytosis is rare(8).

Ideal treatment of germinoma consists of surgical removal, post-operative chemotherapy and craniospinal radiotherapy. Overall prognosis of this tumor is good with 90% 5 year survival rate. Non-germinomatous germ cell tumors have a worse prognosis, with 5yrs survival rates less than 25%(8). Blood hCG and alpha-fetoprotein levels are useful markers for follow-up.

Contributors: FH diagnosed the case and supervised the manuscript and is guarantor of the paper: SAA & MZ reviewed the literature and prepared this manuscript and followed the patient. SN performed histopathological examination.

Funding: None.

Competing interests: None.

REFERENCES

1. Sugiyama K, Uozumi T, Kiya K, Mukada K, Arita K, Kurisu K, *et al.* Intracranial germ-cell tumor with synchronous lesions in the pineal and suprasellar regions: Report of six cases and review of literature. *Surg Neurol* 1992; 38: 114-120.
2. Arita N, Ushio Y, Hayakawa T, Watanabe M, Maeda Y, Kanai N, *et al.* Primary intracranial germ-cell tumors. *Surg Neurol* 1979; 7: 465-475.
3. Friedman NB. Gaminoma in the pineal. Its identity with germinoma of the testis. *Cancer Res* 1947; 7: 363-368.
4. Korm A. Bifocal primary intracranial germinoma in a child-case report. *Radiol Oncol* 2001; 35: 179-183.

CASE REPORTS

5. Sung D II, Harisiadls L, Chang CH. Midline pineal tumors and suprasellar germinomas: Highly curable by irradiation. *Radiology* 1978; 128: 745-751.
6. Fujita T, Yameda R, Saitoh H, Itoh S, Nakai O. Intracranial germinoma and Down's syndrome: Case report. *Neurologia Medico-chirurgica* 1992; 32: 163-165.
7. Johnsen DE, Woodruff WW, Allm IS, Cera PJ, Funkhouser GR, Coleman LL. MR imaging of the sellar and juxtaseellar regions. *Radiographics* 1991; 11: 727-758.
8. Sanders WP, Chundi VV. Extra axial tumors including pituitary and parasellar. *In: William W, Orrison Jr MD, editor. Neuroimaging. Philadelphia: WB Saunders Company. 2000; p 660-696.*

Multiple Hypoechoic Lesions in Spleen and *Mycoplasma Pneumoniae* Infection

Chao Chun Zou
Li Liang

An 8-year-old boy was admitted because of recurrent fever for 1 month with increased CRP and ESR. Ultrasound reviewed multiple, small, hypoechoic, rounded and wedge-shaped nodules with diffuse blood flow in spleen and enlarged abdominal lymph nodes. The spleen was enlarged and no echoic space was found in the largest lesion on 5th day. After a positive mycoplasma pneumoniae (MP) IgM was reported on 6th day, azithromycin was used intravenously. The temperature returned to normal and CRP and ESR improved in a short period. The

From Zhejiang University, School of Medicine, Children's Hospital, 57 Zhugan Xiang, Hangzhou 310 003, China.

Correspondence to: Chao Chun Zou, Zhejiang University, School of Medicine, Children's Hospital, 57 Zhugan Xiang, Hangzhou 310 003, China. E-mail: zou108cc@yahoo.com

Manuscript received: October 23, 2003;

Initial review completed: January 23, 2004;

Revision accepted: September 27, 2004.

lesions and lymphadenopathy disappeared and MP IgM antibody became negative 6 months later.

Key words: *Mycoplasma pneumoniae, Splenic lesions, Ultrasound.*

Case Report

An 8-year-old boy was admitted to hospital because of recurrent fever (normal in the morning and febrile during night, ranged from 39.5° C to 40.0° C) for 1 month. There was no cough except on the first and second day. No angina, tetter, arthralgia, dyspepsia, vomiting, night sweats, or abdominal pain were noted. He had no history of chronic liver disease or foreign travelling and no family history of serious illness. The patient had received intravenous cephalosporins or penicillins for 20 days, but did not recover.

Physical examination showed normal vital signs except for a temperature of 40° C. There was no skin lesion or peripheral stigmata of chronic liver disease. Several cervical lymph nodes were palpable with 0.5-1.0 cm in diameter, and no axillary or inguinal nodes were noted. The head, ears, eyes, nose, throat, cardiac and pulmonary examinations were all normal. The spleen was not palpable. The liver span was 9-10 cm by percussion, easily felt