

**Chediak-Higashi Syndrome —
Accelerated Phase**

**R.P. Singh
P. Gupta
Satendra
B. Sen**

Chediak-Higashi syndrome (CHS), an autosomal recessive defect of polymorphonuclear leucocytic function is characterized by increased susceptibility to pyogenic infections, oculocutaneous albinism, neutropenia and presence of abnormal granules in leucocytes. This rare disorder has been described in approximately 80 cases from world over including three reports from India since its first description(1-3). CHS can enter into an accelerated phase mimicking lymphoreticular malignancy with poor outcome(1). We report an interesting case of CHS without albinism in accelerated phase.

Case Report

A 154-year-old girl, product of a non-

*From the Departments of Pediatrics and Pathology,
University College of Medical Sciences and
G. T.B. Hospital, Delhi.*

*Reprint requests: Dr. Piyush Gupta, R-6A MIG
Flats, Dilshad Garden, Delhi 110 095.*

Received for publication: October 12, 1992;

Accepted: July 20, 1993

consanguineous marriage was admitted with three months history of high grade intermittent fever, neck swellings and pallor. There was no history of cutaneous bleeds or tubercular contact. Examination revealed a sick looking, febrile, irritable, photophobic child with moderate anemia and generalized lymphadenopathy. Skin, hair and iris were normal. There were no bleeding spots or bony tenderness. The liver and spleen were enlarged 5 cm below costal margin each. Rest of the systemic examination was normal. On investigation, hemoglobin was 7.0 g/dl. Total leucocyte count was $5.9 \times 10^9/L$ with 22% neutrophils, 76% lymphocytes and 2% monocytes. Peripheral smear revealed predominantly microcytic hypochromic red cells. The neutrophils and lymphocytes showed large peroxidase positive granules. Few atypical lymphocytes were also seen. Platelets were adequate. Bone marrow was hypercellular with M:E ratio 1.17 : 1 with normal myeloid and erythroid maturation. The granulocytes, lymphocytes, monocytes and histiocytes showed large, prominent, peroxidase positive inclusions (*Fig. 1*). Megakaryocytes were adequate in number. Electronmicroscopy of the marrow revealed large granules in the myeloid series in cells (*Fig. 2*). Lymph node aspiration revealed histiocytic hyperplasia with hemophagocytosis (*Fig. 3*). Blood culture showed *Acinetobacter anitrotus* sensitive to chloramphenicol, amikacin and cotrimoxazole. Liver functions showed mild elevation of enzymes (SGOT-140 IU/L, SGPT-157 IU/L) and prolongation of prothrombin time and partial thromboplastin time with kaolin. The child was put on IV fluids and antibiotics (cefotaxime 100 mg/kg/day and amikacin 15 mg/kg/day). On

BRIEF REPORTS

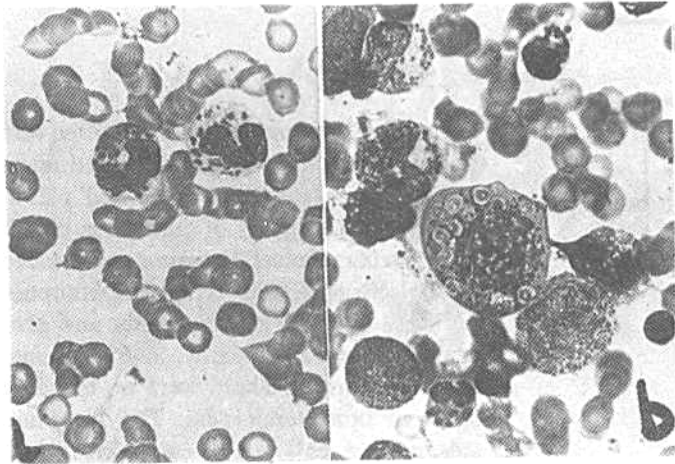


Fig. 1. Large prominent granules in myeloid series of cells as seen in (a) peripheral smear and (b) bone marrow.

Fig. 2. Electromicrograph of marrow showing prominent granules in cytoplasm.

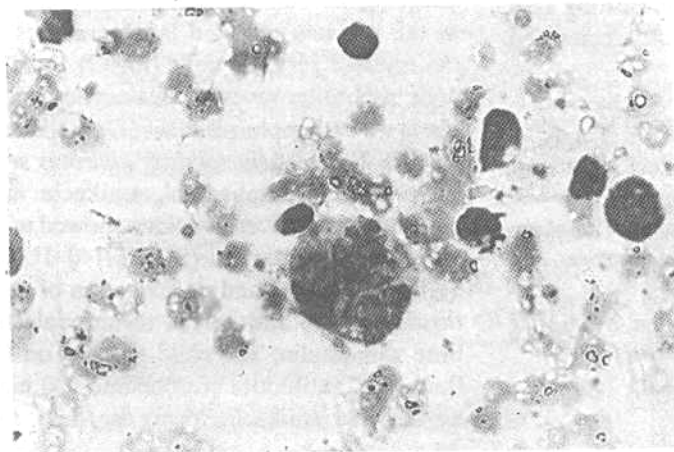
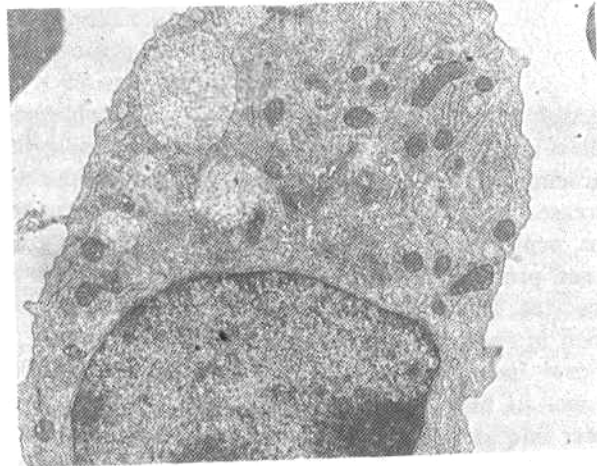


Fig. 3. Histiocyte with hemophagocytosis in lymph node aspirate.

3rd day she became drowsy and developed left sided hemiparesis and VII nerve palsy. A lumbar puncture was done which revealed few atypical lymphocytes, occasional monocytoïd cells and neutrophils with large granules. CSF protein was 60 mg/dl. The child continued to run high grade fever and developed fulminant pneumonia on 7th day despite supportive therapy with antibiotics and blood transfusion and expired three days thereafter.

Discussion

The present case presented in the accelerated phase of CHS with clinical features suggestive of lymphoreticular malignancy. Partial oculocutaneous albinism is one of the integral part of this clinico-hematological syndrome, yet without albinism have also been described in the literature(4,5). Most of the patients who land up in the accelerated phase succumb to illness. The term 'accelerated phase' originated in 1964 and is still used as the exact pathophysiology remains elusive(6). Whether accelerated phase is a neoplastic process or expression to a viral reaction is controversial. In few studies, the acceleration has been linked with associated malignancy(7,8). However, majority describe the acceleration as a consequence of reaction to some viral infection. White *et al.*(9) demonstrated some virus like particles in peripheral blood cells of two patients with CHS. Rubin *et al.* (10) identified the benign hemophagocytic lymphohistiocytosis in these cases and ascribed it to viral reaction. The authors also coined a new term "virus associated hemophagocytic syndrome (VAHS)" for this phase in case a virus is also identified. Presence of atypical lymphocytes in the peripheral blood and cerebrospinal fluid along with histiocytic hyperplasia and hemophagocytic changes seen in bone mar-

row and lymph node favored a reactive pathology in the present case. The patient has associated neurological deficit, which could be due to presence of granules in Schwann cells(1) or an acute insult to the nervous system in the form of an intracranial bleeding could not be documented by doing a CT scan due to difficulty in transporting this sick child.

The granules found in CHS are to be differentiated from those in Alder-Reilly anomaly, Batten-Spielmer disease, May-Hegglin anomaly and Hermansky-Pudlak syndrome on the basis of different clinical and morphological characteristics. Apart from the supportive treatment, which includes antibiotics to control the infection and blood transfusions; various treatment modalities such as high dose vitamin C, corticosteroids, vincristine and transfer factor have been tried but none has proved to be consistently beneficial(1,11,12). Bone marrow transplant, to date, is the only available cure(13).

Acknowledgement

The authors acknowledge the Pool scheme of CSIR, Government of India.

REFERENCES

1. Blume RS, Wolff SM. The Chediak-Higashi Syndrome: Studies in four patients and a review of literature. *Medicine* 1972, 51: 247-280.
2. Seth P, Bhargava M., Kalra V. Chediak-Higashi Syndrome. *Indian Pediatr* 1982, 19: 950-952.
3. Pandita R, Quadri MI. Chediak-Higashi Syndrome. *Indian Pediatr* 1989, 26: 826-828.
4. Efrati P, Jonas W. Chediak's anomaly of leucocytes in malignant lymphoma associated with leukemic manifestations: Case-report with necropsy. *Blood* 1958, 13: 1063-1073.

5. Saraize LG, Azevedo M, Correa JM, Carvalho G, Prospero JD. Anomalous panleukocytic granulation. *Blood* 1959, 14: 1112-1127.
6. Kritzler RA, Turner JY, Lindenbaum J, *et al.* Chediak-Higashi syndrome: Cytological and serum lipid observations in a case and family. *Am J Med* 1964,36: 583-594.
7. Dent PB, Fish LA, White JG, Good RA. Chediak-Higashi syndrome: Observations on the nature of the associated malignancy. *Lab Invest* 1966, 15: 1634-1642.
8. Tan C, Etcubanas E, Lieberman P, Isenberg, H, King O, Murphy ML. Chediak-Higashi Syndrome in a child with Hodgkin's disease. *Am J Dis Child* 1971,121: 135-139.
9. White JG. Virus like particles in peripheral blood cells of two patients with Chediak-Higashi Syndrome. *Cancer* 1966, 19: 877-884.
10. Rubin CM, Burke BA, McKenna RW, *et al.* The accelerated phase of Chediak-Higashi Syndrome. An expression of the virus associated hemophagocytic syndrome? *Cancer* 1985, 56: 524-530.
11. BoxerLA, WatanabeAM, RisterM, Besch HR, Allen J, Baehner RL. Correction of leucocyte function in Chediak-Higashi Syndrome by ascorbate. *New Eng J Med* 1976, 295: 1041-1045.
12. Khan A, HillJM, Loeb E, MacLellan A, Hill NO. Management of Chediak-Higashi Syndrome with transfer factor. *Am J Dis Child* 1973, 126: 797-799.
13. Virelizier JL, Durandy A, Lagrue A, Fischer A, Griscelli C. Successful bone marrow transplant in a patient with Chediak-Higashi Syndrome. *Exp Hematol* 1983, 11: 91-92.

Familial Testotoxicosis

P.K. Chandra
A. Kalam
P. Banerjee
K.N. Bhattacharya
S. Chowdhury

Familial testotoxicosis is a rare variety of isosexual precocious puberty resulting from autonomous Leydig cell hyperplasia of testes(1). It is transmitted as a male limited autosomal dominant disorder(2).

Case Report

A 4-year-old boy was brought to us for

evaluation of masculine stature with inappropriately large penis (*Fig. 1*) observed for about 2 years. Thereafter, the patient gradually developed a masculine body habitus with moustache and adult like hoarse voice. However, expulsion of semen on one occasion—when the phallus was handled by the mother during a bath—made the parents anxious.

Nevertheless, the boy had no behavioral

From the Department of Pediatrics, Calcutta National Medical College and Hospital, 24, Gorachand Road, Calcutta 700 014.

Reprint requests: Dr P.K. Chandra, 375, Sahid Khudiram Bose Sarani (Kalindi West), Calcutta 700 030.

*Received for publication: November 25, 1992;
 Accepted: September 1, 1993*