

CONGENITAL SYPHILIS: A REAPPRAISAL

A. Malik
Sudarshan Kumari
S. Singh

The incidence of congenital syphilis has paralleled the increasing incidence of primary and secondary syphilis in adult population since 1986(1,2). However, because of the implementation of routine maternal serologic screening during pregnancy, it is relatively uncommon to encounter a child with classic signs of late congenital syphilis. Currently, the challenge is, evaluation of the symptom-free infant born to a mother with a positive result on a serologic screening test for syphilis. The pediatrician must assess the maternal treatment regimen for adequacy of treatment of infection in the fetus and must determine the need to treat an infection that may not be clinically apparent in the newborn infant.

Areas already plagued with large number of cases of human immunodeficiency

virus (HIV) infection are seeing a resurgence in the incidence of primary and secondary syphilis predominantly among heterosexuals(3). Published reports of individual treatment failures have formed the basis of renewed concerns about CNS involvement in early syphilis and about treatment efficacy of Benzathine Penicillin 'G' in infants and in patients with acquired immunodeficiency syndrome.

Epidemiology

In India, we do not have national figures for all cases of congenital syphilis—also for positive serology in pregnant women. The incidence of syphilis cases reported in 1987 showed higher figures for some states like Andhra Pradesh (n=14,791), Karnataka, Maharashtra and Madhya Pradesh. In Delhi, during the same year, 1034 cases of syphilis were reported. In the foot hills of Himalayas in Uttar Pradesh, sexually transmitted diseases and syphilis have high incidence due to polygamy being socially acceptable. A study from rural areas of Madras noted positive serology for syphilis in 1.8-2.4% of pregnant women whereas 1.99% of pregnant women were VDRL reactive at the Institute of Venereal Diseases, Madras.

In the United States, congenital syphilis is at its highest rate since the early seventies(2,3). The increase in cases of congenital syphilis reported by the Centre for Disease Control (CDC) is due to an increase in actual cases and also due to broadening of the case definition in 1988(4) (Table I). In India, the magnitude of this disease is still very great. The factors which attribute to it are: (i) Poor antenatal care and home deliveries by untrained birth attendants; (ii) No routine serological testing of preg-

From the Neonatal Unit, Department of Pediatrics, Lady Hardinge Medical College and Associated Smt. Sucheta Kriplani Hospital and Kalawati Saran Children's Hospital, New Delhi 110 001.

Reprint requests: Dr. Sudarshan Kumari, 23B/6, P-2 Guru Gobind Singh Marg, New Delhi 110 005.

TABLE I—Surveillance Case Definition for Congenital Syphilis.

For reporting purposes, congenital syphilis includes cases of congenitally acquired syphilis in infants and children, as well as syphilitic still births.

I. *Confirmed*: A confirmed case of congenital syphilis is a case in which *T. pallidum* is identified by darkfield microscopy, fluorescent antibody, or other specific stains in specimens from lesions, placenta or autopsy material.

II. *Presumptive*: A presumptive case of congenital syphilis is either of the following:

- A. Any case in which the infant's mother had untreated or inadequately treated* syphilis at delivery, regardless of findings in the infant.
- B. Any case in which the infant or child is reactive to a treponemal test for syphilis and in which anyone of the following present:
 - 1. Any evidence of congenital syphilis on physical examination (*Table II*).
 - 2. Any evidence of congenital syphilis on a long bone radiograph.
 - 3. Reactivity to a CSF VDRL test +
 - 4. Elevated CSF cell count or protein (without other cause) +
 - 5. Quantitative nontreponemal serologic titer that is fourfold higher than the mother's (both specimens drawn at birth).
 - 6. Reactive test for FTA-ABS 19S-IgM antibody +

III. *Syphilitic stillbirth*: A syphilitic stillbirth is defined as a fetal death in which the mother had untreated or inadequately treated syphilis at delivery of a fetus after a 20-week gestation or of a fetus weighing more than 500 g.

Modified from centres for Disease Control MMWR 1989, 38: 825-829.

* Inadequate treatment consists of any nonpenicillin therapy or penicillin given less than 30 days before delivery.

+ It may be difficult to distinguish between congenital and acquired syphilis after infancy. Signs may not be obvious and stigmata may not yet have developed. Abnormal values of CSF VDRL test cell count, and protein, as well as IgM antibodies, may be found in either congenital or acquired syphilis. Findings on long bone radiograph may help to indicate congenital syphilis. The diagnosis may ultimately be based on maternal history and clinical judgement; the possibility of sexual abuse also needs to be considered.

nant women; (iii) Lack of proper sex education; (iv) Poor status of women in society; (v) Poor budget allocation for STD as compared to other diseases; (vi) Inadequate maternal therapy; and (vii) Its not being a notifiable disease.

Clinical Manifestations

Transplacental infection of the fetus can occur at any stage of pregnancy(5) and during any stage of maternal syphilis. The widely varied manifestation of *in utero* in-

fection are determined by the maternal stage of syphilis, stage of pregnancy at the time of infection, rapidity of maternal diagnosis and treatment, adequacy of the maternal treatment regimen for the fetus, maternal reinfection, and immunologic reaction of the fetus. Because the fetus acquires *Treponema pallidum* by hematogenous spread from the mother, there is no primary (chancre) stage in the fetus and widespread involvement is usual. Thirty to forty per cent of fetuses with congenital syphilis are still born and represent the most severely affected infants. Nearly two-thirds of newborns are symptom free and have been identified by prenatal screening (Table II).

TABLE II—Clinical Findings of Congenital Syphilis: Early Congenital Syphilis.

1. Antenatal	
	Funisitis
	Placentitis(7)
	Enlarged placenta
	Focal proliferative villitis
	Endovascular proliferation
	Immature villi
2. Natal	
	Still birth
	Non Immune hydrops fetalis
	Intra uterine growth retardation
	Hepatosplenomegaly
	Neonatal jaundice
	Generalized lymphadenopathy(17,18)
3. Bone abnormalities	
	Osteochondritis
	Wimberger sign
	Diaphyseal periostitis
4. Mucocutaneous lesions	
	Condylomata Lata
	(Pigmented macules)
	Vesicubullous rash
	Mucous patches

Unexplained rash on palms and soles
Intractable diaper rash
Snuffles (Persistent rhinitis)

5. *Nephrotic syndrome*
6. *Pneumonitis (Pneumonia alba)*
7. *Neurological abnormality*
Postneonatal crabs palsy (Pseudoparalysis)

Late Congenital Syphilis

(Onset after 2 yrs)
Frontal bossing
Saddle nose
Short maxilla
Protruding mandible
High arched palate
Hutchinson teeth*
(Peg shaped upper incisors)
Perioral fissures
Mulberry molars
Clutton joints
(Bilateral knee effusions)
Higoumenakis sign
(Sternoclavicular thickening)
Saber Tibia
Interstitial keratitis*
Flaring scapulas
Hydrocephalus
8th cranial nerve* deafness
Mental retardation
Leptomeningitis
Failure to thrive
Ophthalmic abnormalities

*Components of Hutchinsons triad.

Adapted from Ibeda and Jenson(15).

Diagnostic Evaluation

A symptom free infant born to mother with positive maternal VDRL test result, calls for a careful search for clinical findings and additional laboratory abnormalities for congenital syphilis. Testing is especially important if no maternal history is

available or if the placenta is grossly enlarged or shows other abnormalities. Examination of amniotic fluid should be performed in cases of fetal death if no other tissue is available.

Clinical Evaluation and Laboratory Diagnosis

These can be briefly summarized as below:

1. Clinical history and infant examination.

2. *Maternal examination:* Any evidence of primary and secondary syphilis, speculum examination for chancre on cervix, the typical painless indurated ulcer. It should be looked for at other sites also, e.g., anus, nipple, lip and tongue, etc.

3. *Serologic tests:* Two types of standard tests are used in conjunction:

(a) *Non treponemal antibody tests:* (i) Venereal Diseases Research Laboratory Test (VDRL); (ii) Rapid Plasma Reagin Card test.

(b) *Confirmatory Treponemal Antibody test:* (i) Microhemagglutination assay for antibodies to *T. pallidum* (MHA-TP), (ii) Fluorescent Treponemal antibody adsorption test (FTA-ABs)

Both types of tests are highly sensitive, although FTA-ABs test is more specific than the VDRL test.

The following facts should be kept in mind before interpreting these tests:

- * Titres of VDRL rise with increasing duration of infection; the titres diminish with appropriate syphilis therapy and can be used to follow response to therapy.
- * Treponemal antibody titres do not correlate with disease activity and are not quantified, once reactive,

they usually remain positive for life even if the infection is cured.

- * Serum from the infant is preferred to cord blood for confirmatory tests because cord blood may produce either false -ve or false +ve results(6,7).
- * Comparison of maternal and neonatal quantitative VDRL antibody titres may indicate fetal infection if infants titre is at least fourfold (i.e., 2 tube dilution) greater than the maternal titres.

(c) *IgM Tests:* It is performed on the IgS fraction of serum IgM.

(d) *Direct Examination of T. pallidum:* Treponemes seen in fresh exudate by darkfield microscopy. Material known to harbour high numbers of spirochetes in congenital syphilis include skin lesions, nasal discharge, the placenta, the umbilical cord and amniotic fluid. Darkfield examination of oral mucosal lesions is not reliable because of the presence of saprophytic non-treponemal spirochetes (Table III).

4. *Examination of CSF for neurosyphilis* in the symptom free infant is indicated in the following situations:

1. Positive cord-blood VDRL.
2. Infants of mothers with untreated syphilis, with undocumented or inadequate treatment, with treatment less than one month before delivery, with stable or rising non-treponemal antibody titres, or with HIV infection.

The following points help in interpretation:

- * CSF VDRL if reactive is generally considered indicative of neurosyphilis and requires appropriate treatment(8,9).
- * CSF leucocytosis and elevated protein concentrations are less specific findings.

TABLE IV—Recommended Antimicrobial Treatment Regimens for Infants Born to Mothers with Positive VDRL Test Results.**I. For confirmed or presumptive congenital syphilis (either item A or item B)**

- (A) Crystalline Penicillin G, 100,000 units per kg/day administered intravenously in divided doses every 8-12 hours for 10-14 days.
- (B) Procaine Penicillin G, 50,000 units/kg/day administered once daily intramuscularly for 10-14 days.

II. Recommended only for infants at low-risk for congenital syphilis who were born to HIV-seronegative mothers adequately treated for syphilis and in whom close follow-up cannot be ensured.

Benzathine penicillin G, 50,000 units/kg (administered intramuscularly as one-time dose).

III. Neurosyphilis: Either 'A' or 'B' to ensure adequate therapy to sterilize CSF(2).

unequivocally treponemicidal in the fetus. Therefore, regardless of the stage of pregnancy, syphilis in pregnant women who are not allergic to penicillin should be treated with penicillin G according to the same dosage regimen recommended for non-pregnant patients.

For penicillin allergic pregnant patients, desensitization followed by treatment with appropriate doses of penicillin G is recommended. Tetracyclines and doxycycline are contraindicated in the treatment of pregnant women because of potential adverse effects on the fetus. Erythromycin should be used with caution because of its frequent failure to cure syphilitic infection in the fetus, probably because of its unpredictable transfer across the placenta(12,13).

Because of the concern about the efficacy of erythromycin treatment of fetal infection, infants whose mothers received erythromycin during pregnancy should undergo complete examination and be treated with a 10-14 day course of penicil-

lin. Treatment failures are higher in women with secondary syphilis. Women treated in second half of pregnancy are at risk for premature delivery and fetal distress if syphilitic treatment precipitates a Jarisch-Herxheimer reaction(14). They should be advised to seek medical attention after treatment if they notice any change in fetal movement or if they have contractions. After maternal therapy, monthly nontreponemal serologic studies should be performed during pregnancy and should demonstrate a progressive fall in titre.

An algorithm for management of an infant born to mother with positive VDRL or RPR test result is depicted in the *Figure*.

Follow-up and Screening

In developed countries routine serologic testing for syphilis is legally required at the beginning of prenatal care. Intermediate testing at the beginning of prenatal care. Intermediate testing at the beginning of the third trimester should be performed for women in high risk populations, and is also indicated for women with suspect

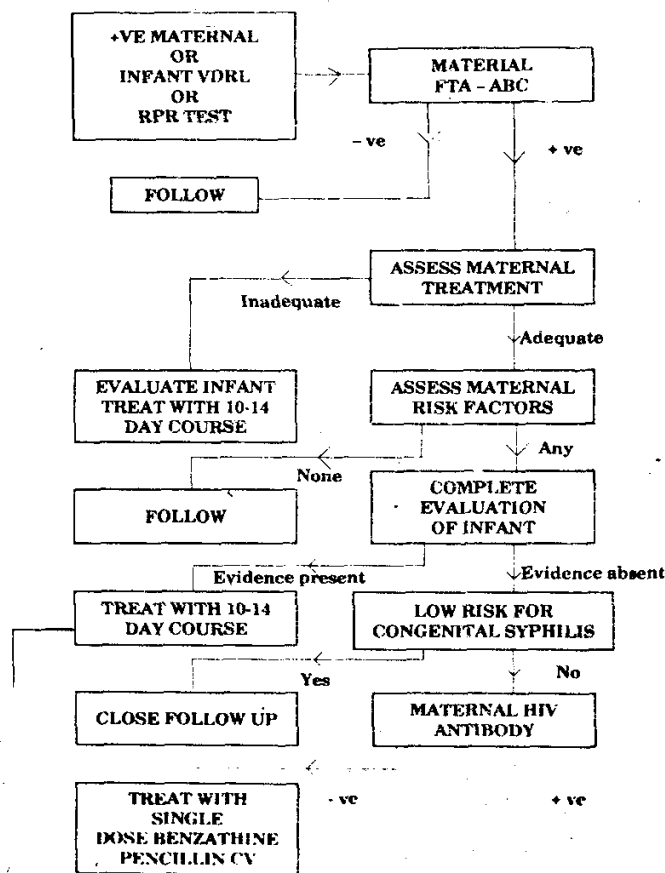


Fig. Algorithm for management for infant born to mother with positive VDRL or RPR test results.

lesions, or a history of exposure to an infected sexual partner.

Some state guidelines specify screening of umbilical cord blood at delivery, although maternal screening may be preferable because cord blood testing may produce either false negative and false positive results(6,7).

Physicians and hospitals should report all confirmed or presumptive cases of congenital syphilis to the local public health authority.

It is imperative to ensure follow-up of all infants born to mothers with a +ve reaction to a serologic test for syphilis which is currently not the practice in India(16,17). Untreated infants should be seen at 1, 2, 4,

6, and 12 months of age. Serologic tests should be performed until they become non-reactive. In the absence of fetal infection, the VDRL titre should be decreasing by 3-4 months of age and should be undetectable by 6 months of age. If these titres are stable or rising, the infant should be fully re-examined and treated. The antibodies transferred to the fetus may be detected for up 1 year after birth, and if positive beyond that, the child should be re-examined and treated.

If postpartum secondary or tertiary syphilis develops in a mother who had undergone treatment for primary syphilis during pregnancy, her infant should have a thorough re-examination for congenital syphilis.

Infants with CSF abnormalities should have additional analysis every 6 months until the profile is normal. CSF VDRL should be performed at 6 months; if +ve, infant should be treated again. If a trend toward normal cell count and protein level is not evident at each examination, or if the cell count is still abnormal at 2 years of age, the infant should be treated yet again.

Organ system demonstrating involvement in the acute phase of infection need to be monitored throughout childhood particularly for neurologic and ophthalmic abnormalities(15).

It would probably be appropriate for us to close this review recalling what Platou said as far back as 1949 "Almost certainly preventable, the occurrence of a case of congenital syphilis can usually be attributed to ignorance or neglect"(16). Undoubtedly, the final stage in the prevention of congenital syphilis and its consequence rests in the hands of Pediatrician's suspicion of congenital syphilis must remain high as long as this epidemic continues to flourish.

REFERENCES

1. Centres for Disease Control: Increases in primary and secondary syphilis, United States, MMWR 1987, 36: 393-395.
2. Centres for Disease Control: Syphilis and congenital syphilis, United States, 1985-1988. MMWR 1988, 37: 486-489.
3. Centres for Disease Control: Congenital Syphilis, United States, 1983-1985. MMWR 1986, 35: 625-628.
4. Cohen DA, Boyd D, Prabhudas I, Mascola L. The effects of case definition in maternal screening and reporting criteria on rates of congenital syphilis. Am J Public Health 1990, 80: 316-317.
5. Harter CA, Benirschke K. Fetal syphilis in the first trimester. Am J Obstet Gynecol 1976, 7: 705-711.
6. Centres for Disease Control: Guidelines for the prevention and control of congenital syphilis. MMWR 1988, 37(S1): 1-13.
7. Brown ST, Zaidi A, Larsen SA, Reynolds GH. Serological response to syphilis treatment: A new analysis of old data. JAMA 1985, 253: 1296-1299.
8. Lukehart SA, Hook EW, Baker Zander SA, *et al.* Invasion of CNS by *Treponema pallidum*: Implications for diagnosis and treatment. Ann Intern Med 1988, 109: 855-862.
9. Swartz MN. Neurosyphilis. In: Sexually Transmitted Diseases. Eds Holmes KK, Mardh PA, Sparling PF, *et al.* New York, McGraw-Hill, 1984, p 318.
10. Mohr JA, Griffeths W, Jackson R, Saadah H, Bird P, Riddle J. Neurosyphilis and penicillin levels in cerebrospinal fluid. JAMA 1976, 236: 2208-2209.
11. McCracken GH Jr, Kaplan JM. Penicillin treatment for congenital syphilis: A critical reappraisal. JAMA 1974, 228: 855-858.
12. Philipson A, Sabath LD, Charles D. Trans-placental passage of erythromycin and clindamycin. New Engl J Med. 1973, 228: 1219-1221.
13. Hashiasaki P, Wertzberger GG, Conrand GL, *et al.* Erythromycin failure in the treatment of syphilis in the pregnant women. Sex Transm Dis 1983, 10: 36-38.
14. Klein VR, Cox SM, Mitchell MD, Wendel GD, Jr. The Jarisch-herxheimer reaction complicating syphilotherapy in pregnancy. Obstet Gynecol 1990, 75: 375-380.
15. Ibeda MK, Jenson HB. Evaluation and treatment of congenital syphilis. J Pediatr 1990, 117: 843-852.
16. Hira SK, Bhat GJ, Patel JB, *et al.* Early congenital syphilis. Clinicoradiologic features in 202 patients. Sex Transm Dis 1985, 12: 177-183.
17. Chawla V, Pandit PB, Nkrumah FK. Congenital syphilis in the newborn. Arch Dis Child 1988, 63: 1393-1394.