

Dieulafoy's Lesion in a Child

Massive upper gastrointestinal bleeding due to a solitary gastric erosion which was first described by a French physician Dieulafoy in 1898(1). Such a lesion has been rarely reported in children. We report a case of Dieulafoy's lesion in a 9-year-old boy who presented with acute massive upper gastrointestinal hemorrhage. There was no history of gastric complaints or drug intake prior to this bleeding episode. Routine investigations including the bleeding profile was essentially normal. Gastroscopy revealed a spurting bleeder from a pinpoint mucosal defect about 3 cm of the gastro-esophageal junction near the lesser curve. Subsequently, the bleeding stopped spontaneously the same day. A repeat endoscopy after three days could not localize the lesion again.

The typical Dieulafoy's lesion is a pinpoint mucosal defect with a spurting bleeder lying within 6 cm of the gastro-esophageal junction and in particular, at the site of lesser curve(2). This entity should always be considered in the differential diagnosis if the cause of hemorrhage remains unexplained. The importance of this lesion lies in the fact that the source of the hemorrhage is difficult to locate, which may lead to repeated negative endoscopies or negative laparotomies and at times, may lead to in-appropriate surgical treatment(3). 'Medical' measures such as cold saline irrigation, H_2 -receptor antagonists or vasopressin don't help. Non-operative

procedures such as selective arterial embolisation or endoscopic electro-coagulation/clipping may be tried. But if these fail or are unavailable, one has to resort to surgical measures which include simple suture ligation of the bleeding artery or local excision. 'Blind' resection such as Billroth surgery should not be attempted; vagotomy does not prevent bleeding either(3).

**Y.K. Sarin,
A.K. Sharma,**

*Department of Pediatric Surgery,
S.M.S. Medical College, Jaipur 302 004*

REFERENCES

1. Dieulafoy G. Exculceration simplex. Bull Acad Med 1898, 49: 49-84.
2. Veldhuyzen van Zanten SJO, Bartelsman JFWM, Schipper MEI, Tytgol GNJ. Recurrent massive hematemesis from Dieulafoy vascular malformations— A review of 101 cases. Gut 1986, 27: 213-222.
3. Haffman J, Beck H, Jensen HE. Dieulafoy's lesion. Surg Gynecol Obstet 1984, 159: 537-540.

Antenatal Diagnosis of Conjoined Twins with Multiple Malformations

Conjoined twins whose occurrence is very rare(1) is frequently associated with multiple anomalies. We report a case of thoraco omphalopagus (conjoined twins) with omphalocele and multiple cardiac anomalies which was diagnosed in the third trimester by ultrasound scanning. The ob-

stetrical management was directed according to the above findings.

A multipara was referred for ultrasound scanning because of the disproportionately increased uterine size. Her past obstetric history was normal and the marriage was nonconsanguineous. On scanning 2 fetuses were detected. The twins had normal growth of the bones corresponding to the gestational period of 38 weeks. The heads and limbs were separated but the thorax was joined at the ventral aspect. The intra abdominal contents were also seen fused and the viscera was lying enclosed by a thin sac (*Fig.*) in between the lower abdominal regions. The detailed imaging of

ous with the common atrium. The targeted imaging of the common atrium showed the presence of an incomplete partition.

The various types of conjoined twins(2) include thoraco omphalopagus (28%), thoracopagus (18%), omphalopagus (10), incomplete duplication (10%) and craniopagus (6%). A diagnosis of conjoined twins is made on the basis of monozygotic twinning associated with inseparable trunks, solitary large liver and heart, bony fusion, single umbilical cord with more than 3 vessels and other supportive variable findings.

The present case was of the commonest type. The ultrasound features were classical especially the presence of conjoined

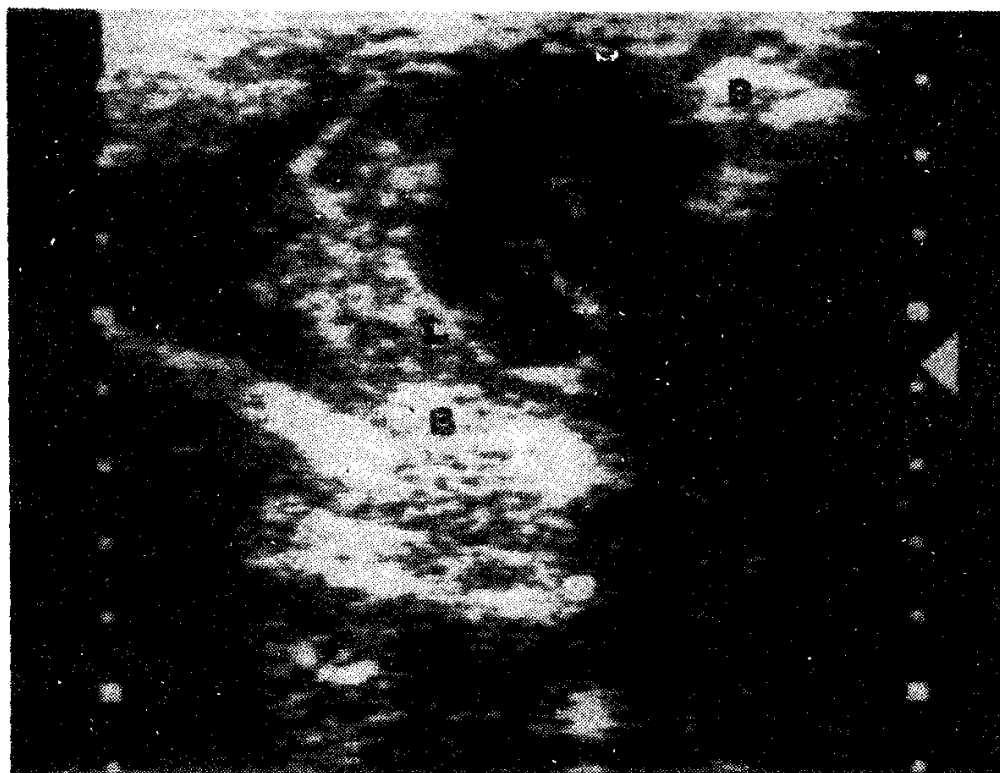


Fig. Associated omphalocele – the bowel loops (L) occupying between the distal halves of the body (B).

the cardiac chambers showed wide deficiency of ventricular septum. The atrio ventricular valves were not formed but was represented by a common orifice continu-

heart which is usually associated in the majority of these fetuses. The ventricular septal defect was very large, a common finding which is consistently present among these

cases(3,4). Though the number of atria may vary (1 to 4) there were 2 atria in this case that could be demonstrated.

Polyhydramnios which is usually present in the majority was not evident here. The large lower ventral defect was manifesting as omphalocele. The other often associated anomalies such as neural tube defects and orofacial defects were also absent. Thoraco-omphalopagus associated with omphalocele ends up in inevitable death(5). Conjoined heart prohibits surgical separation. These fetuses died immediately after the cesarian section.

If correctly diagnosed the decision for separation is determined by the site of fusion, organs shared, presence of correctable or associated other anomalies, extent of damage to connecting structures and the general well being of each fetus(5).

K. Balakumar,

Consultant Ultrasonologist,

P.V.S. Cancer Research Centre,

Calicut 673 002.

REFERENCES

1. Harper RG, Kenigsberg K, Sia CG, Horn D, Stern D, Bongiovi V. Xiphopagus conjoined twins: A 300 years review of the obstetric, morphopathologic, neonatal and surgical parameters. *Am J Obstet Gynecol* 1980, 137: 617-629.
2. Guttmacher AF, Nichols BL. Teratology of conjoined twins. *Birth Defects* 1967, 3: 3.
3. Noonan JA. Twins conjoined twins and cardiac defects. *Am J Dis Child* 1978, 132: 17-18.
4. Patel R, Fox K, Dawson J, Tailor JF, Graham GR. Cardiovascular anomalies in thoracopagus twins and the importance of pre-operative cardiac evaluation. *Br Heart J* 1977, 39: 1254-1258.
5. Votteler TP. Conjoined twins. *In: Pediatric Surgery*. Eds Welch KJ, Randolph JG, Ravitch MN, O'Neill JA, Rowe MI. Chicago, Year Book Medical Publishers 1986, pp 771-779.
6. Romero R, Pihu G, Jeanty P, Ghidini A, Hobbins JC. Conjoined twins. *In: Prenatal Diagnosis of Congenital Anomalies*. Eds Romero R, Pihu G, Jeanty P, Ghidini A, Hobbins JC. Connecticut. Appleton and Lange, 1988, pp 405-409.

Brain Stem Abscess

A ten-year-old male child was admitted with headache and diplopia for five days. There was no history of fever, convulsions, headache or trauma and no past history of similar attack. On admission child was conscious and vital signs were maintained. Neurological examination revealed left sixth and seventh nerve palsy with slight weakness of left upper and lower limb and a clonus at left ankle joint. There were no signs of raised intracranial tension and fundus was normal. The skull X-ray and cerebrospinal fluid analysis were normal. The neurological status deteriorated over the next one week. The weakness on the left side increased markedly with dysphagia and urinary retention. The CT scan revealed a lesion in the brain stem, compressing and displacing the fourth ventricle and without any hydrocephalus. A diagnosis of brain stem abscess was made. The patient was put on conservative management. The sensorium further deteriorated with inter nuclear ophthalmoplegia and features of raised intracranial tension. A surgical intervention was done and the abscess was drained; 6 ml of yellowish green pus was obtained which revealed Gram